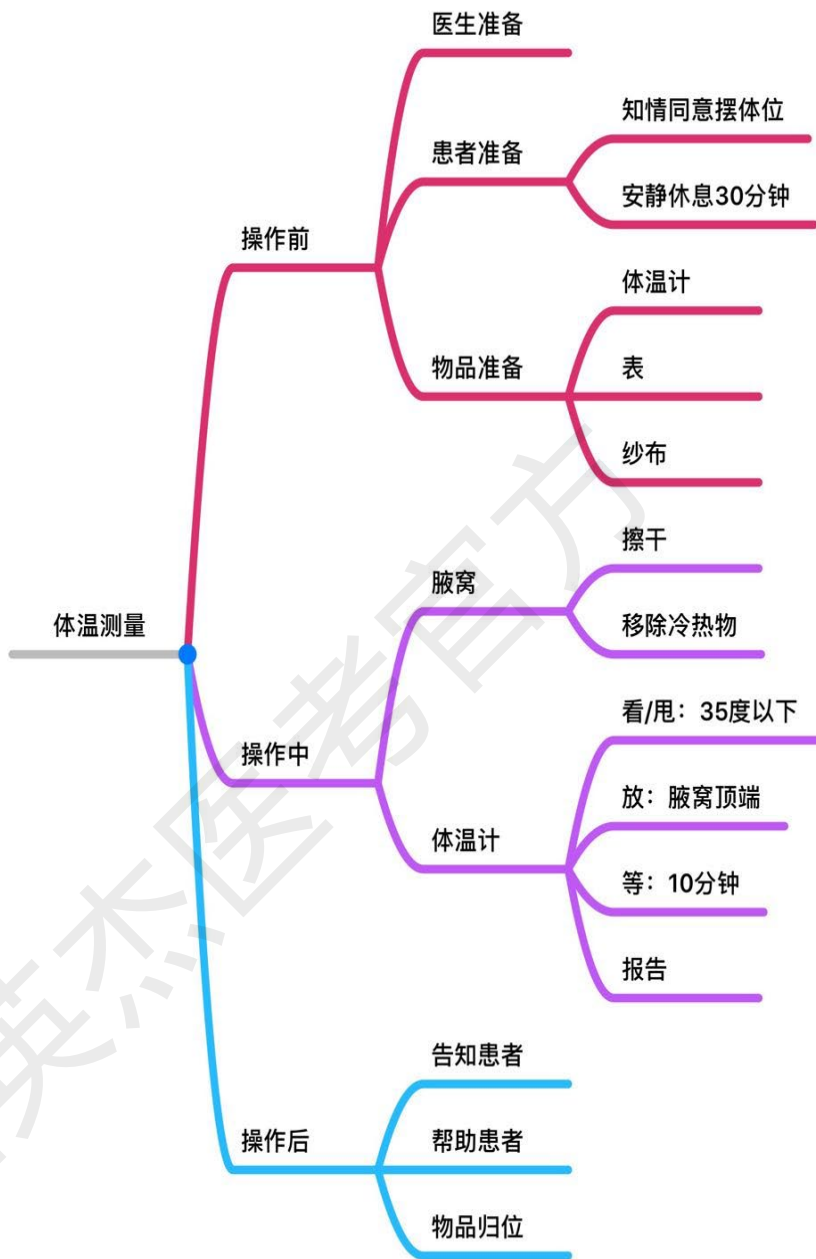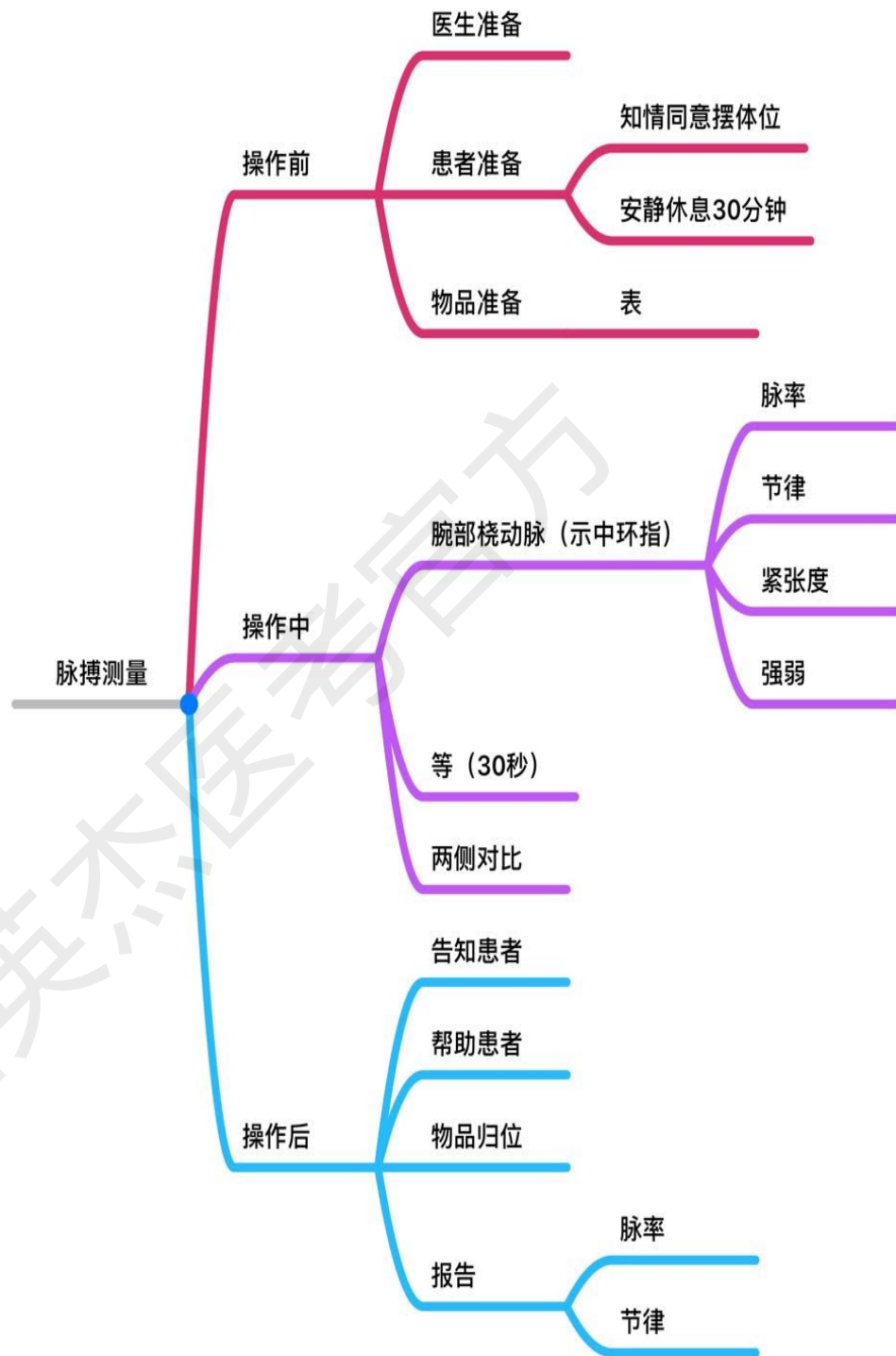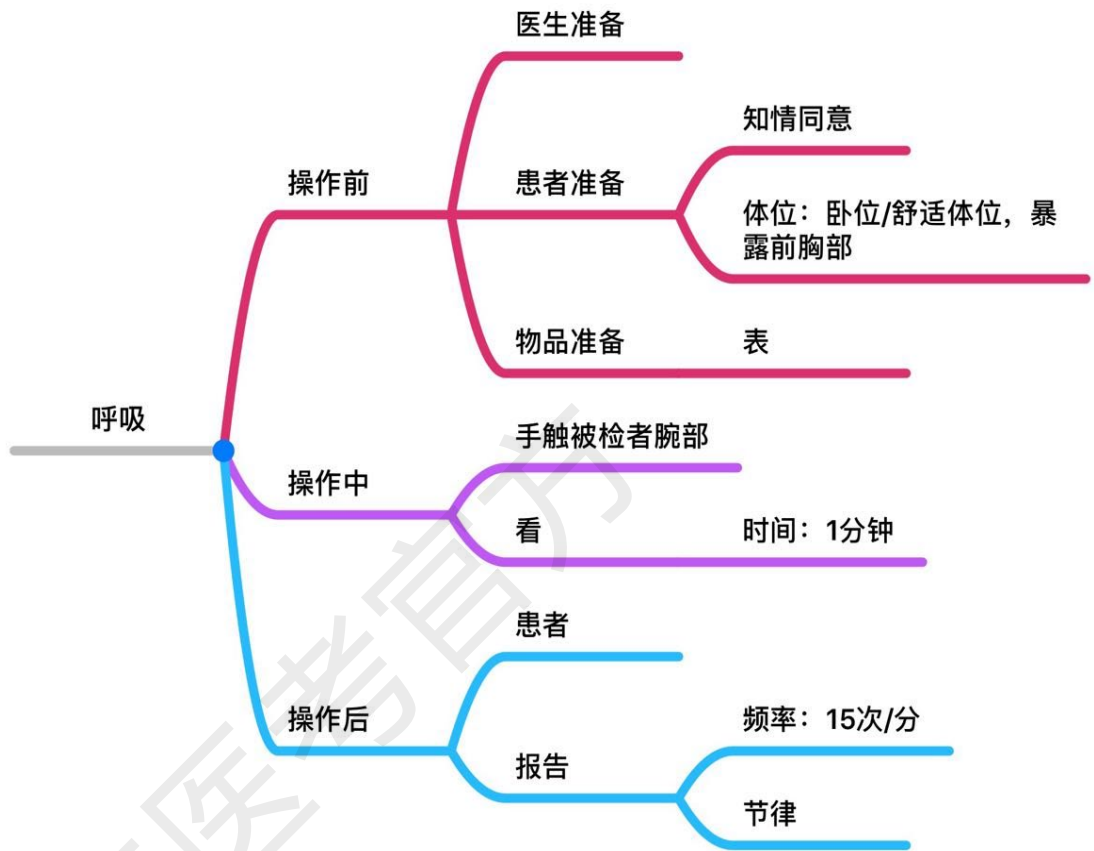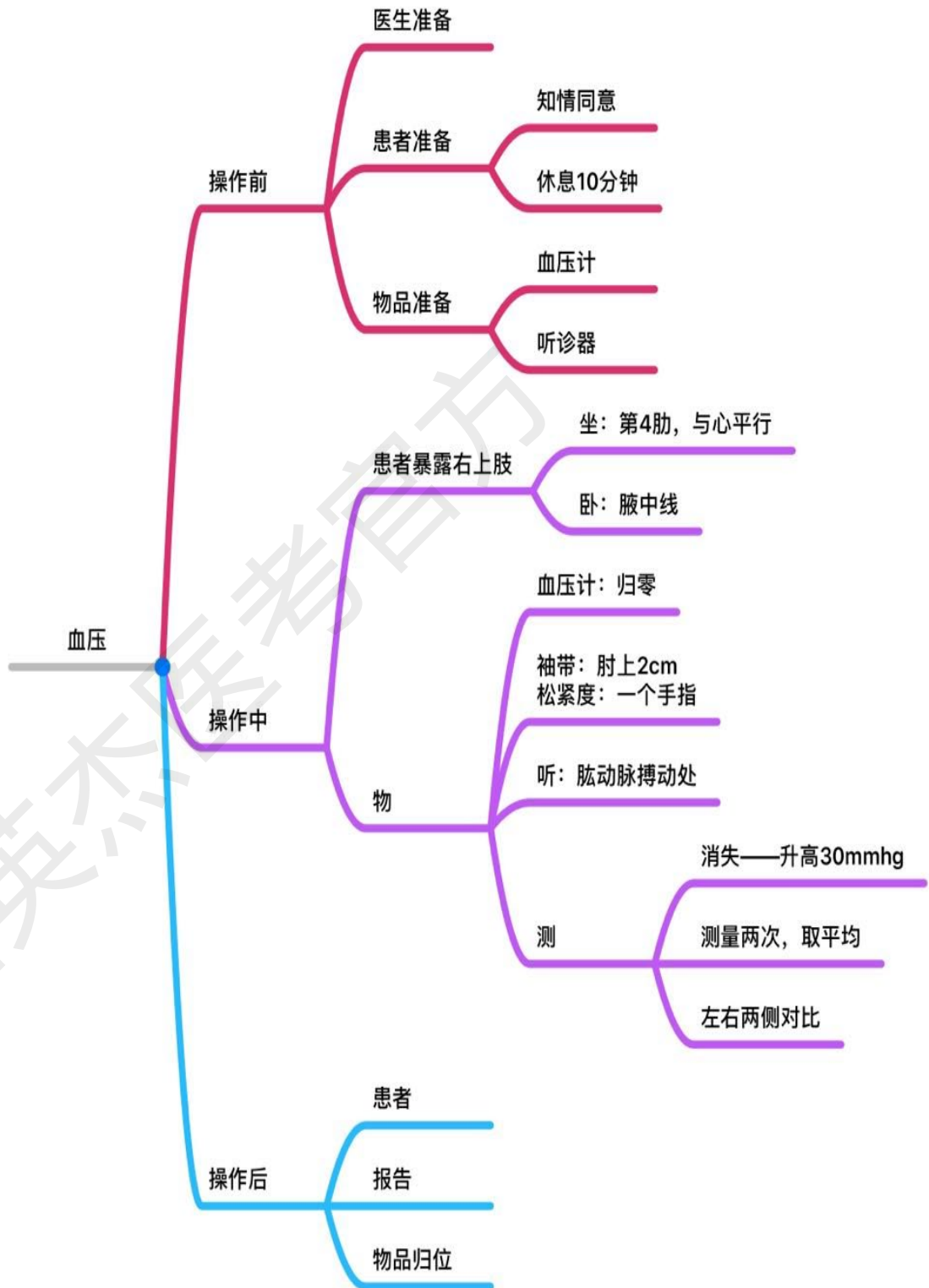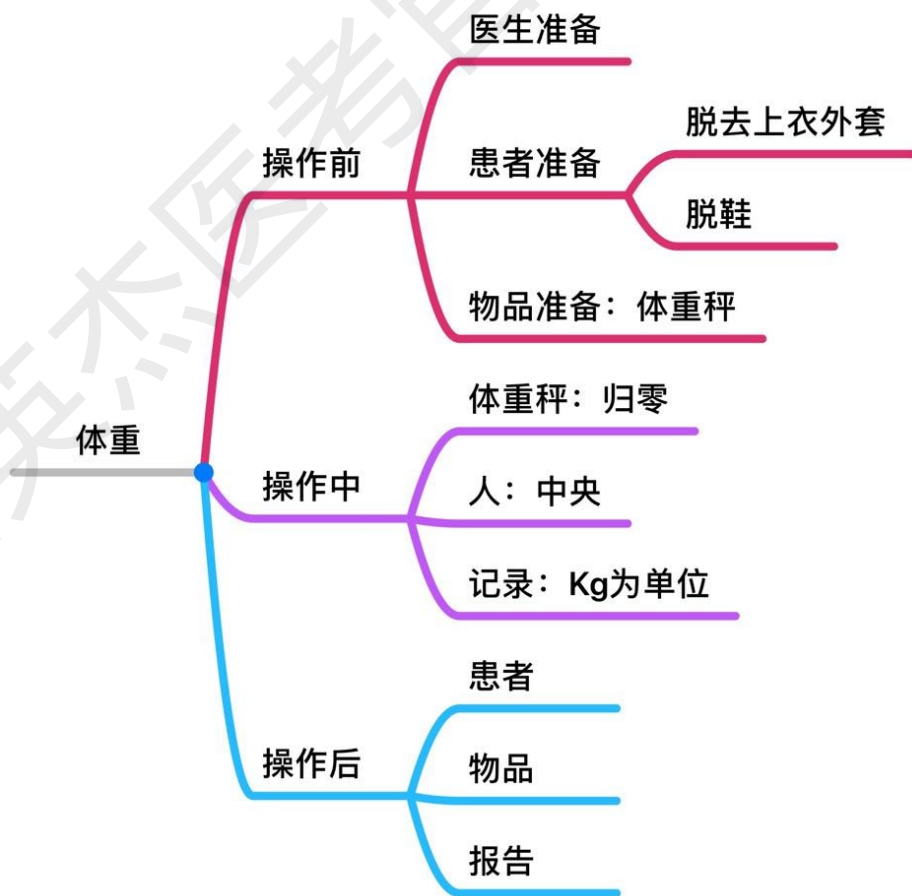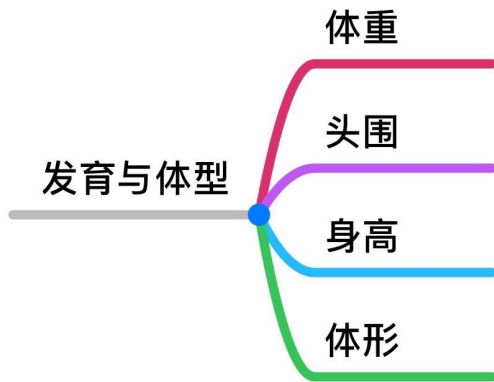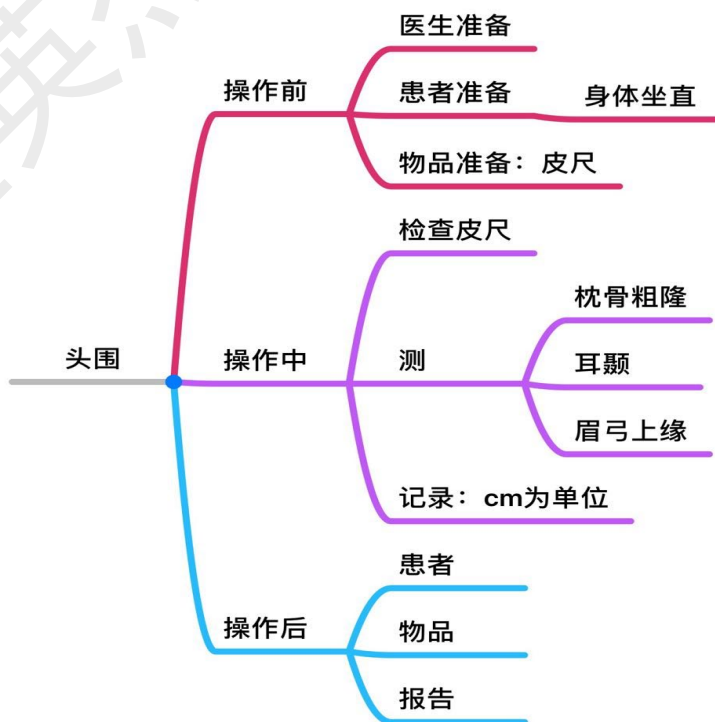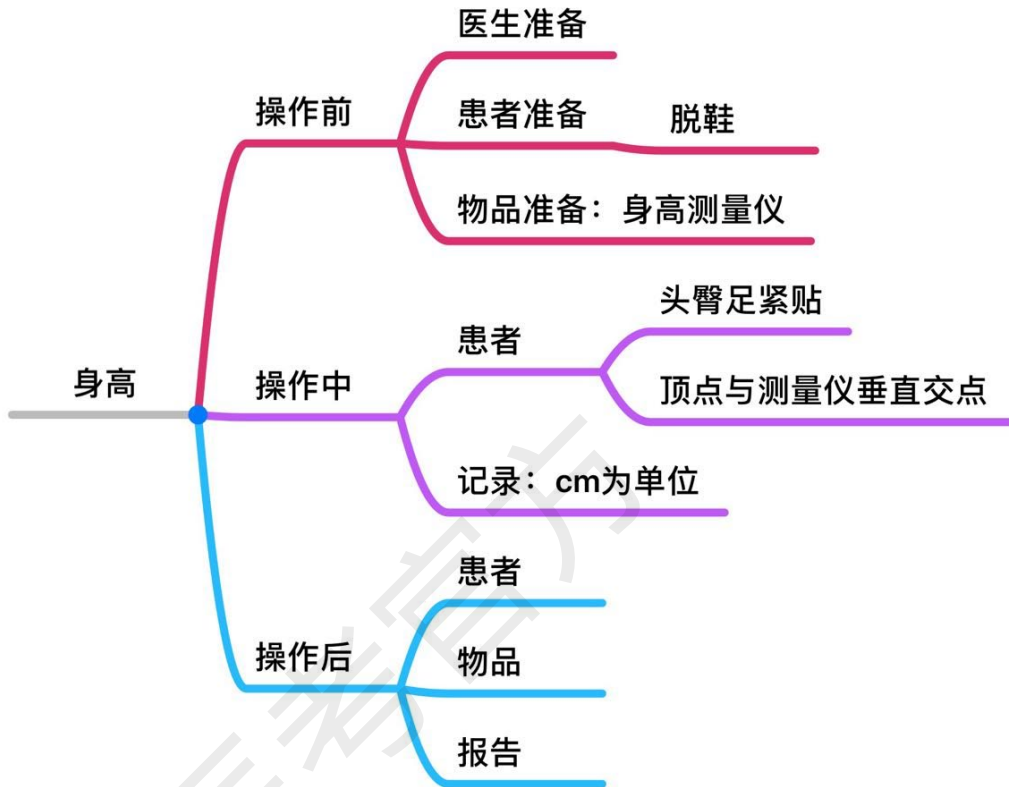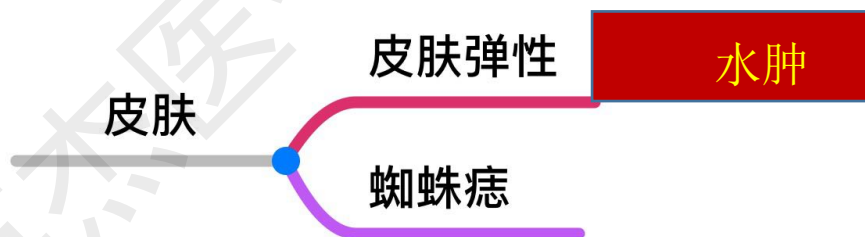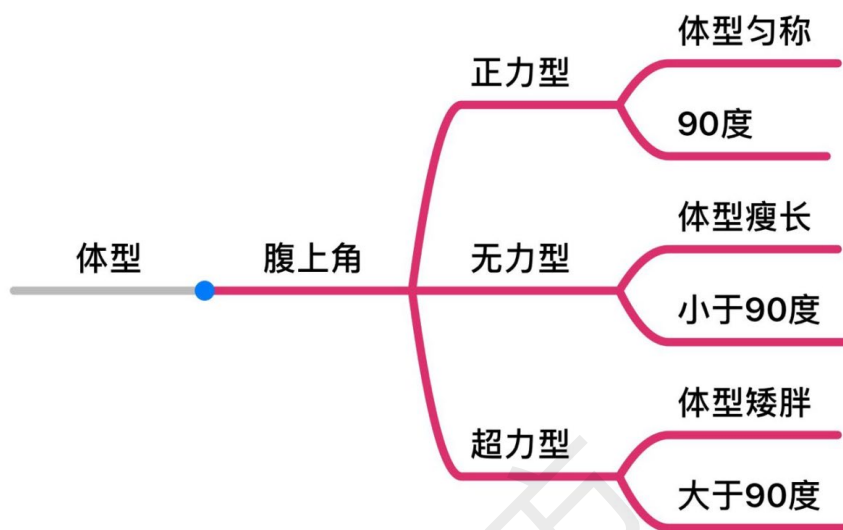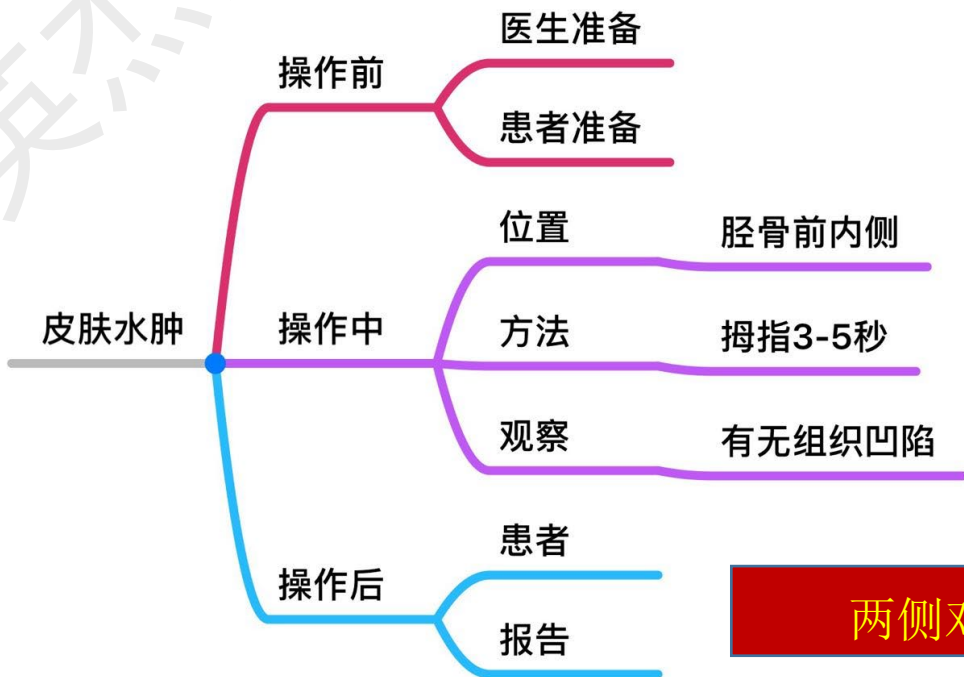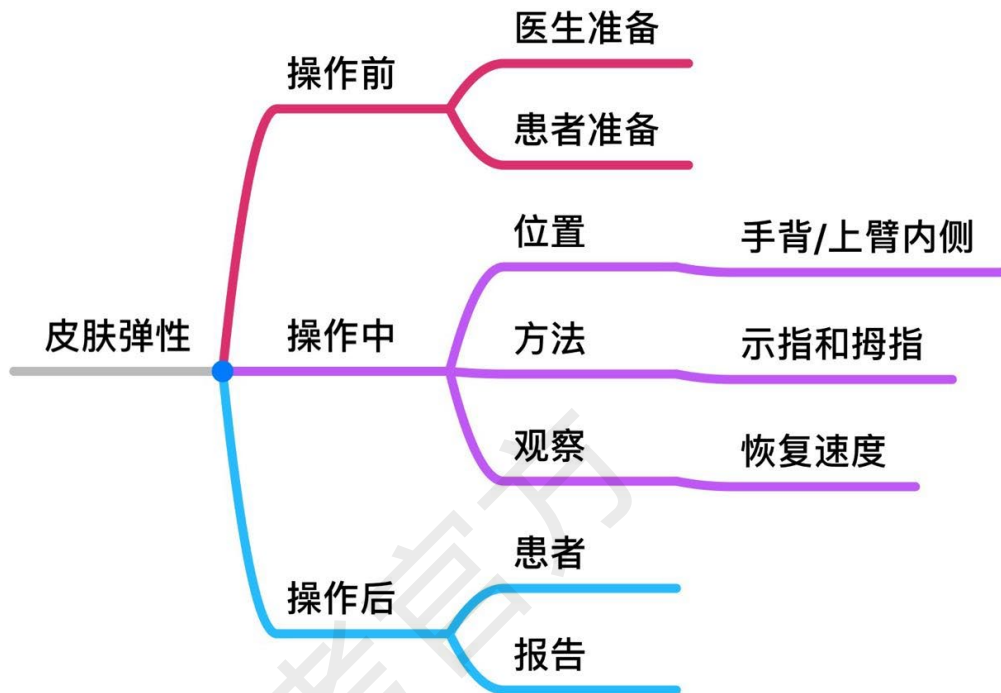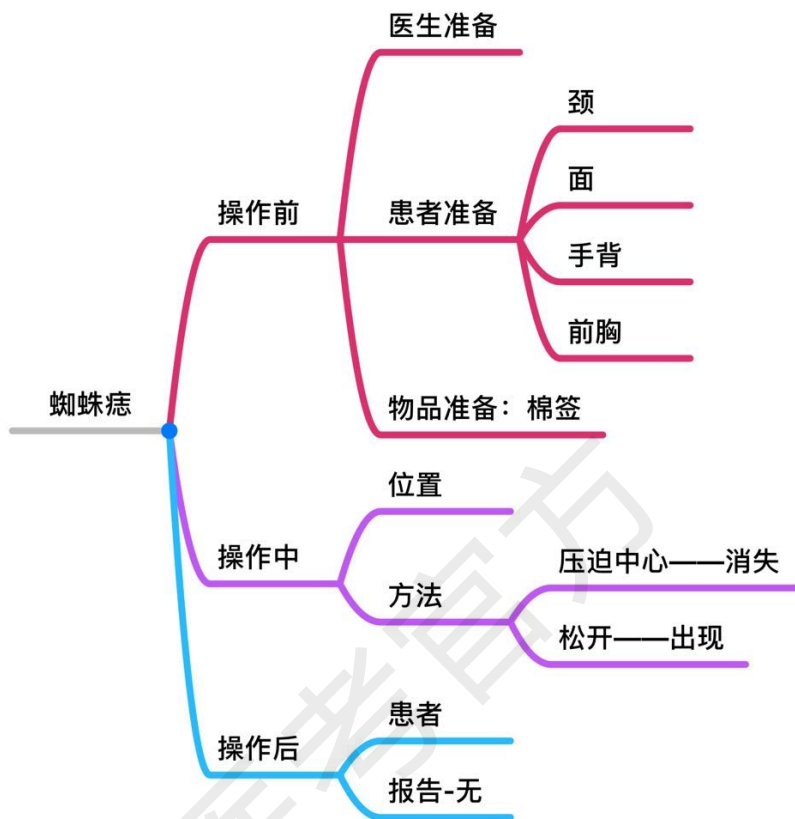
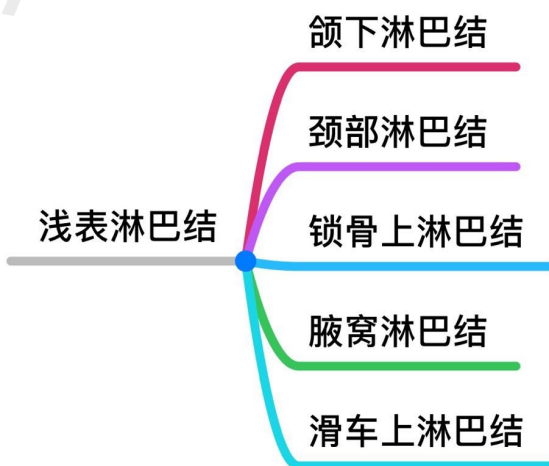


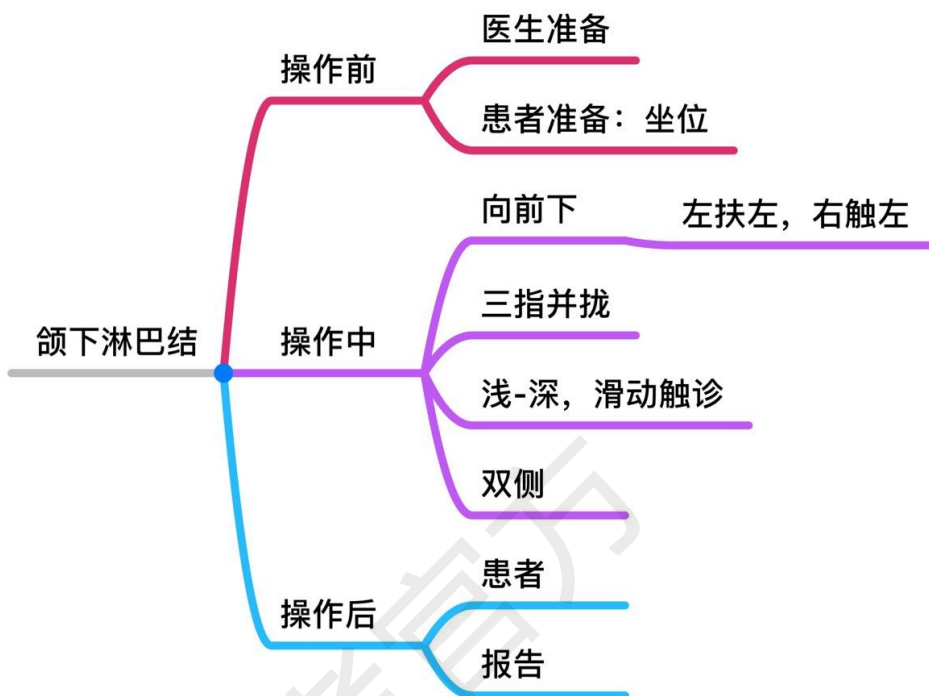两侧对比

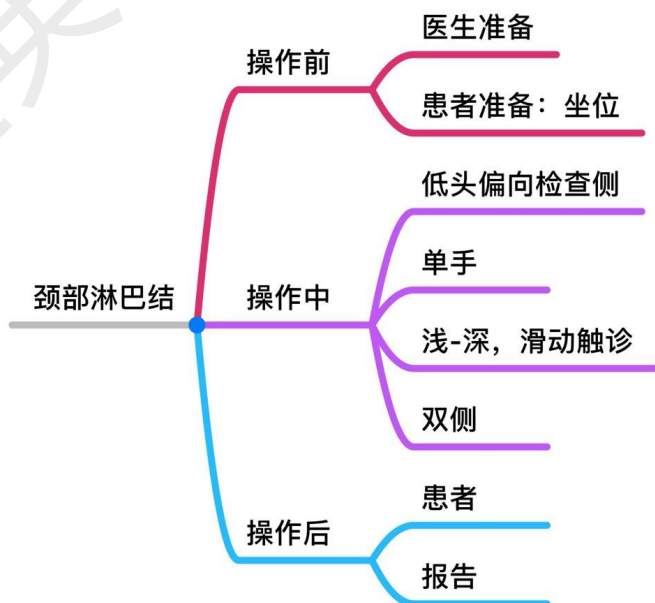


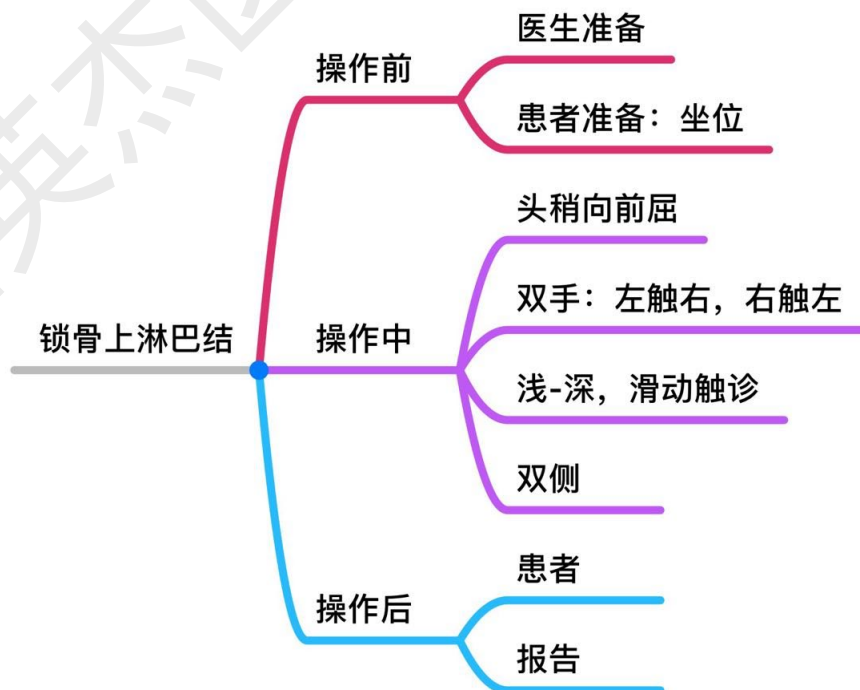
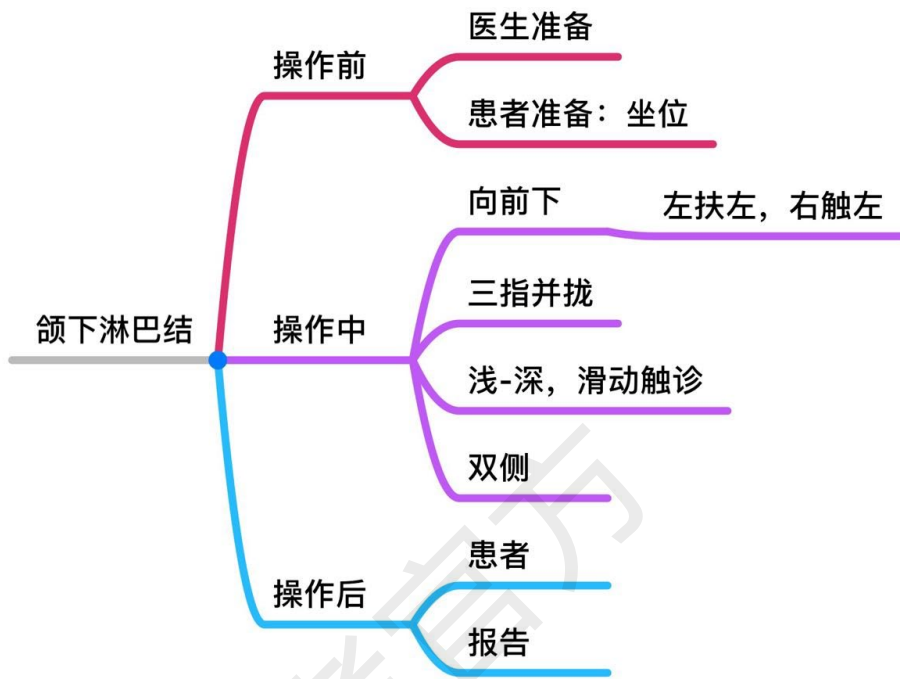
描述：部位、大小、质地、数量、活动度、有无粘连、压痛、局部皮肤有无红肿、瘢痕、瘰管



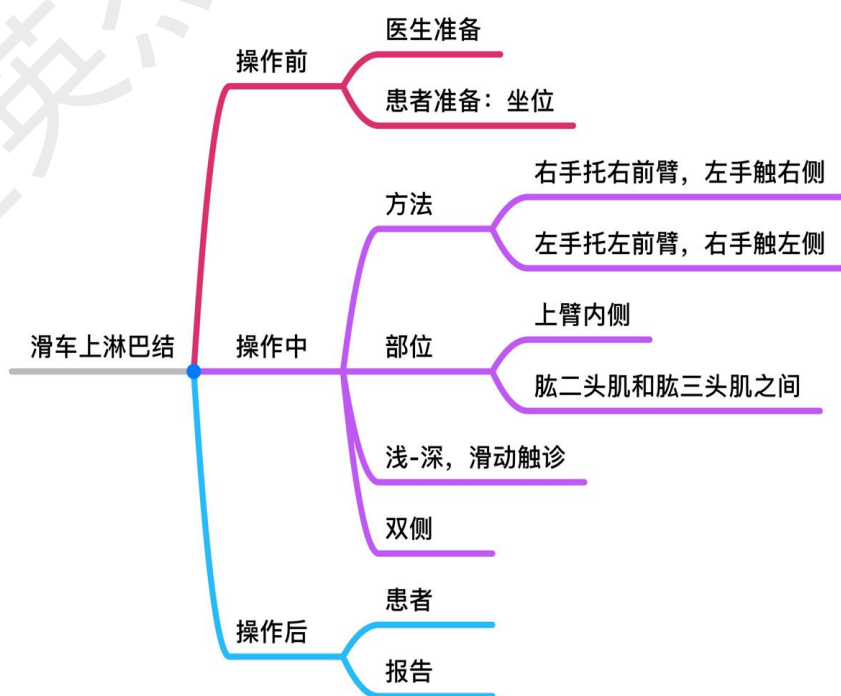
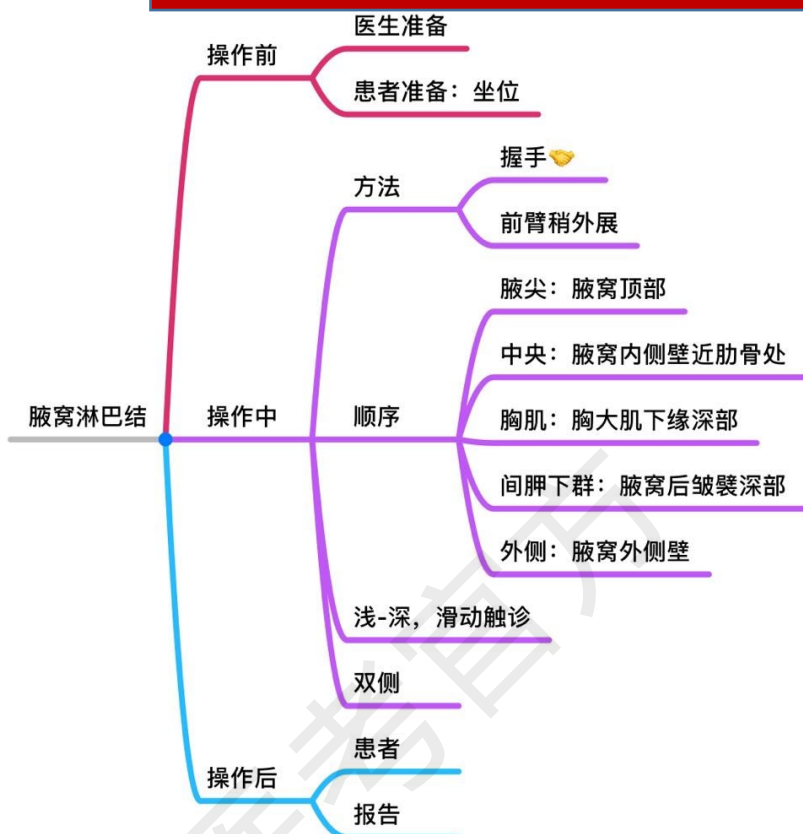


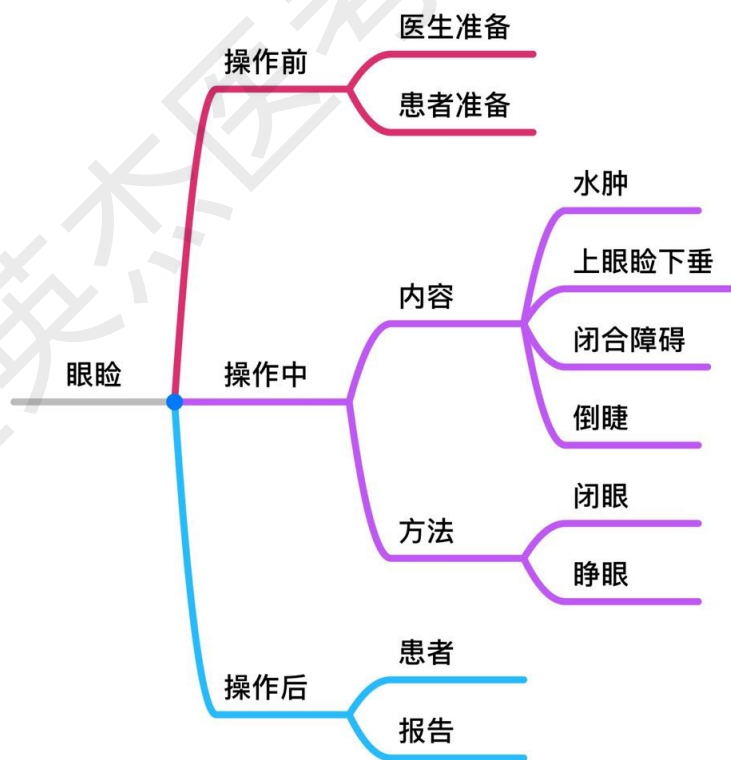
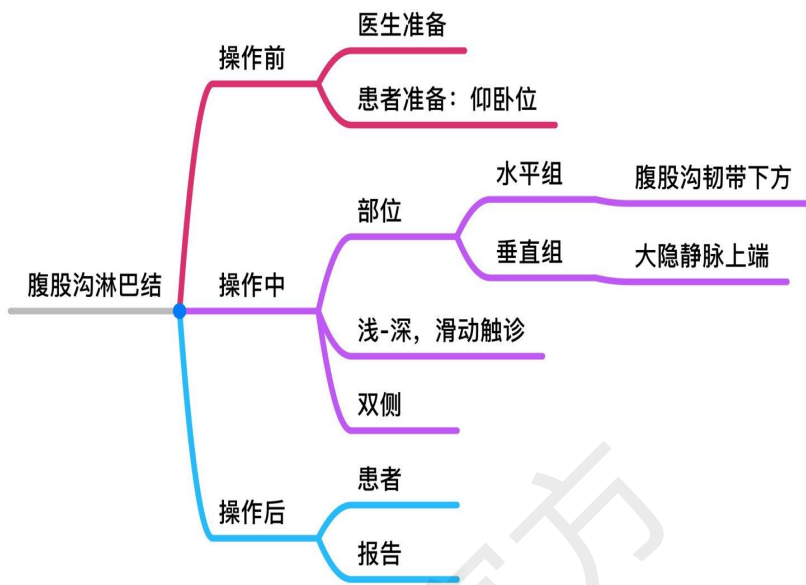
顺序：颈前三角、颈后三角、斜方肌前缘

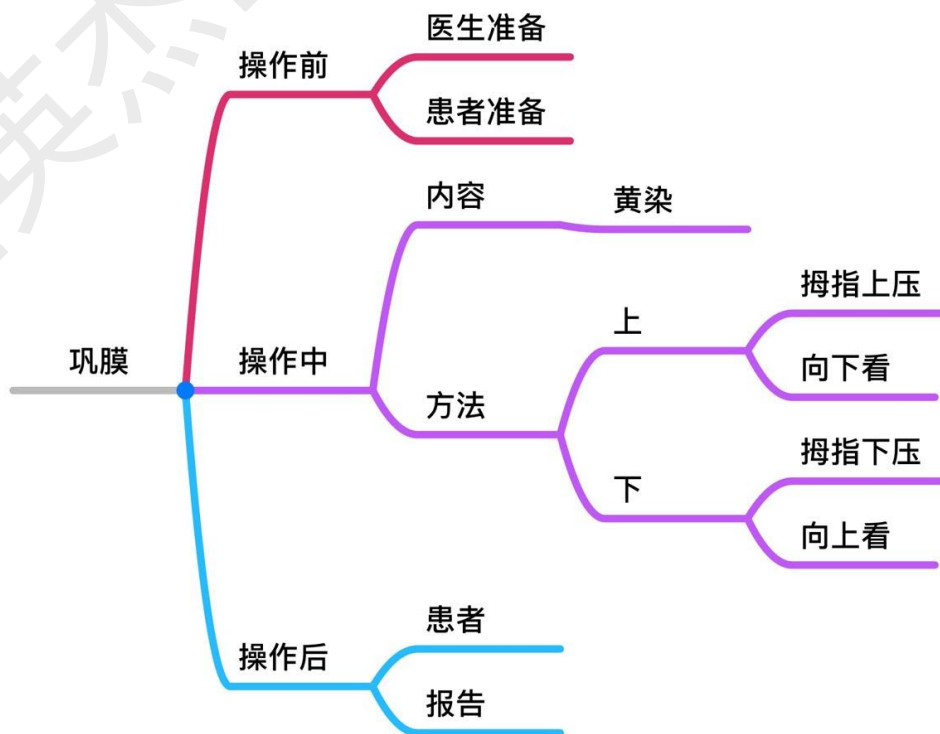
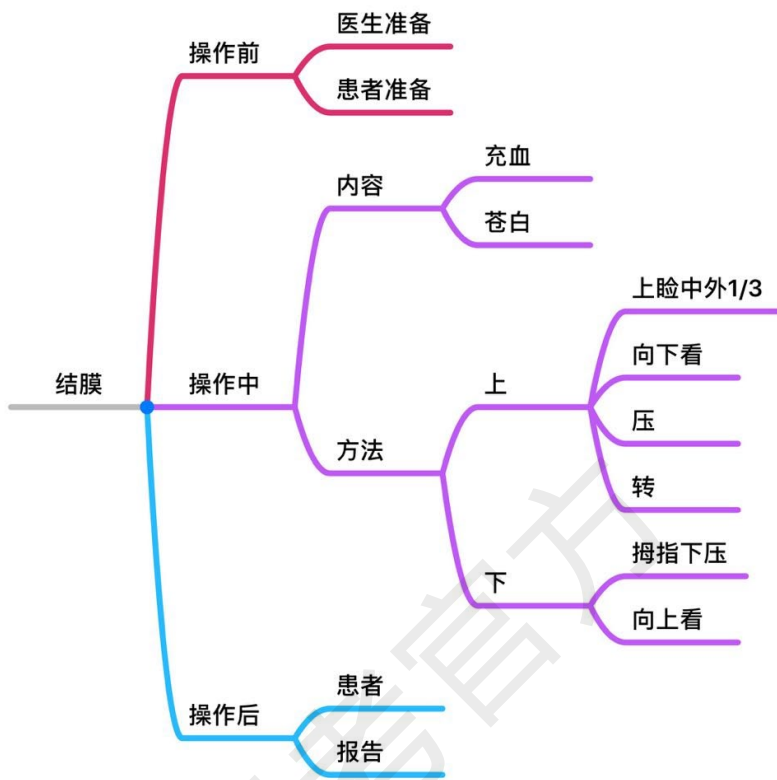


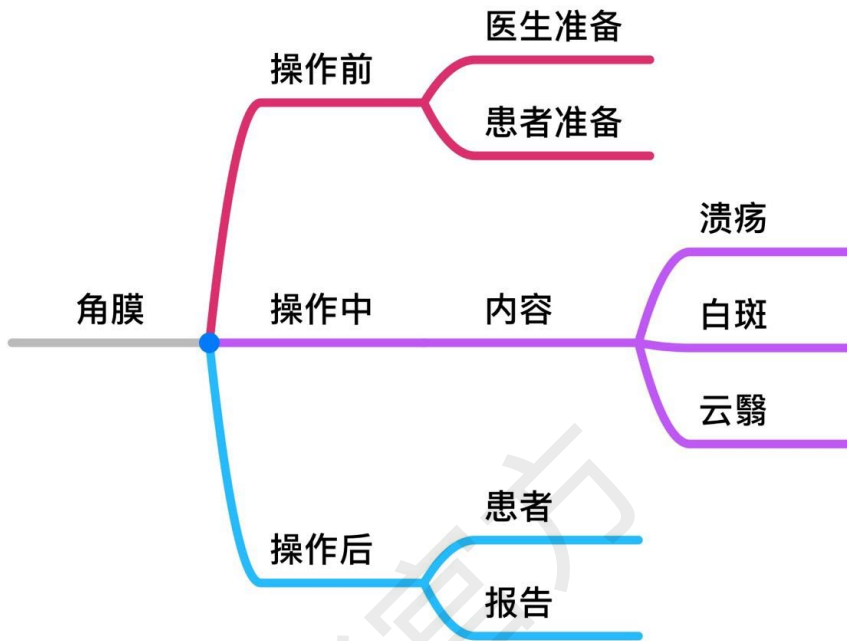


尖内前后外

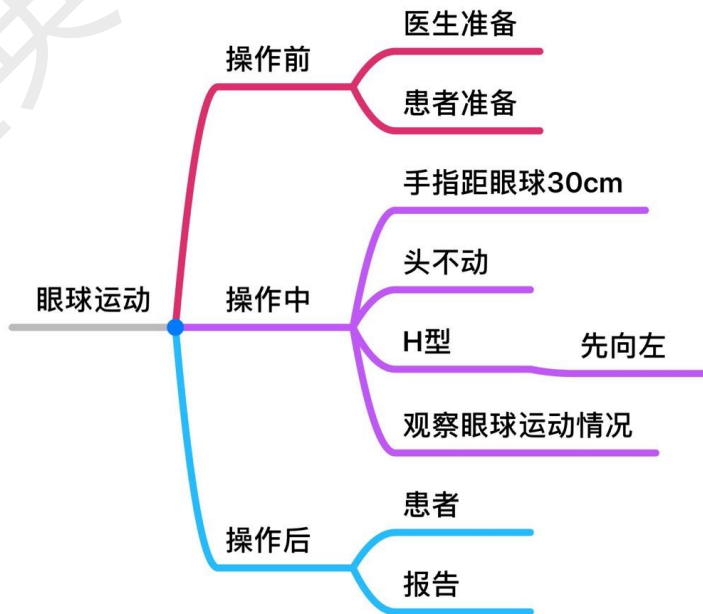

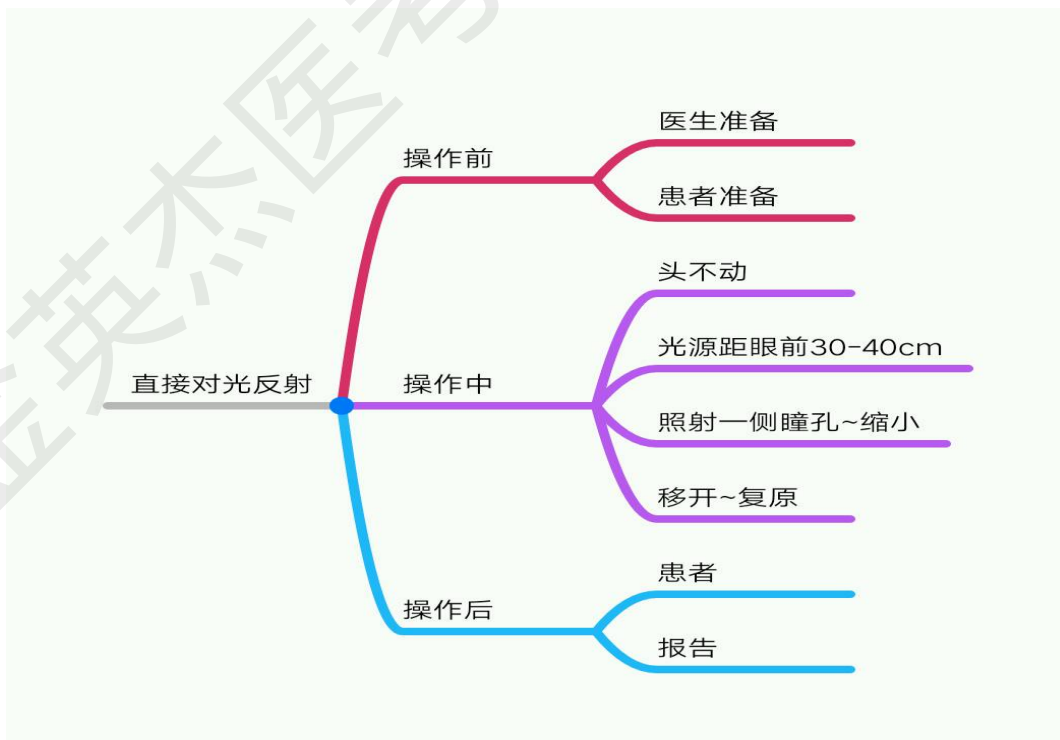
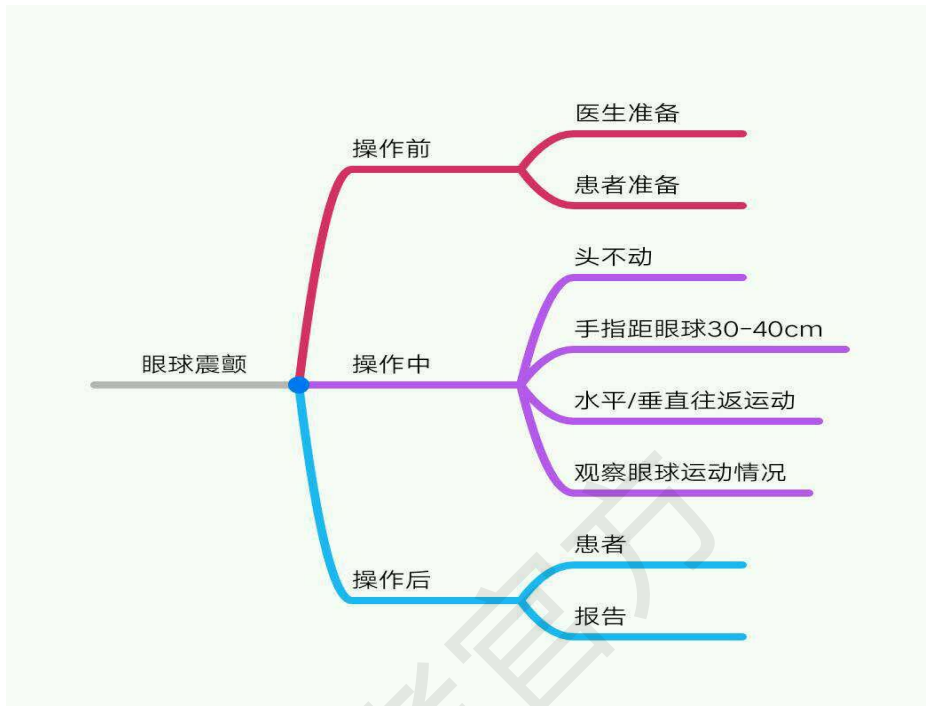


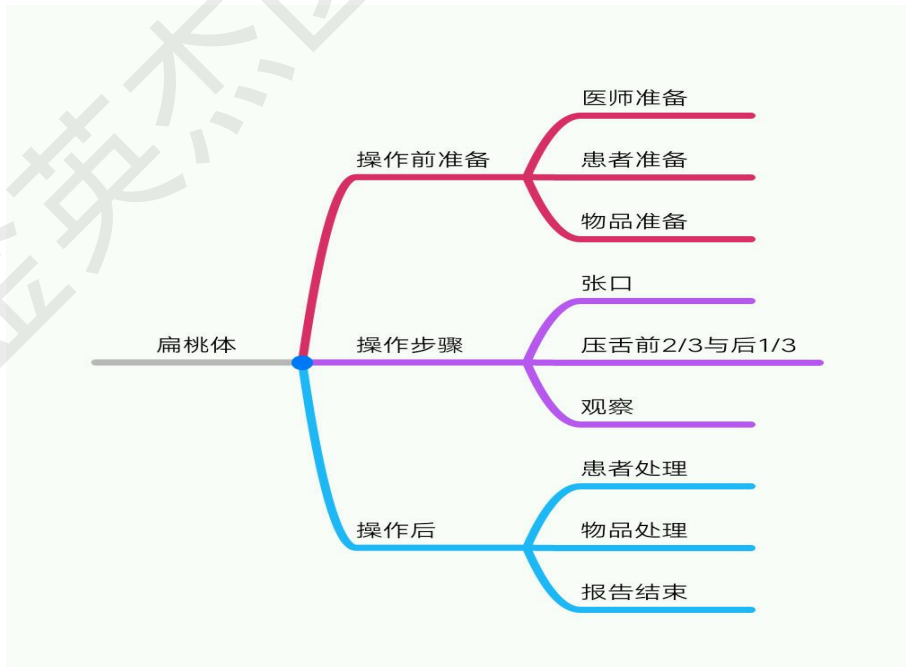
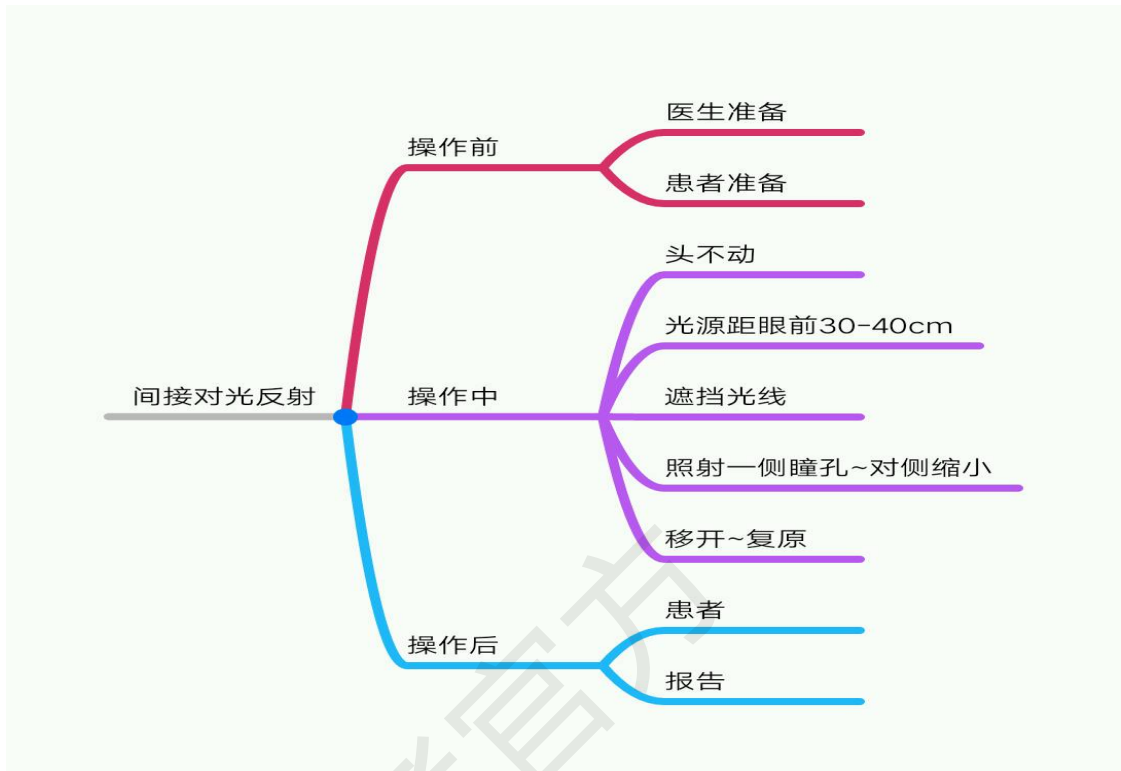


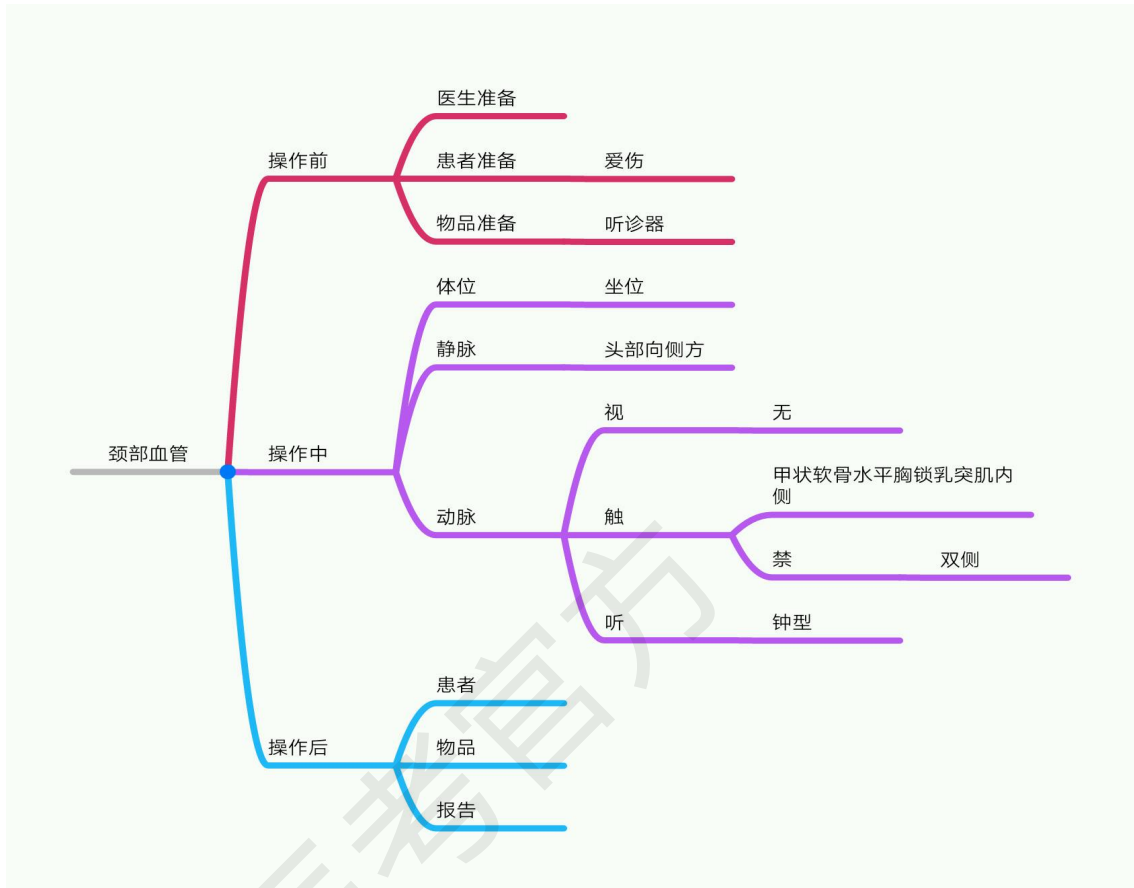


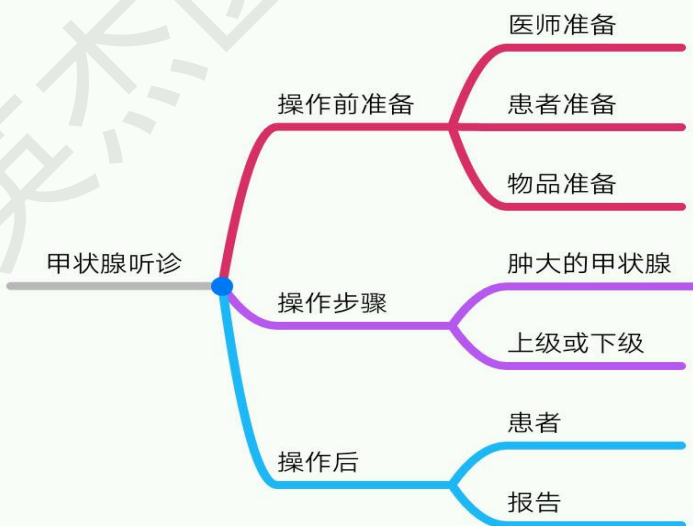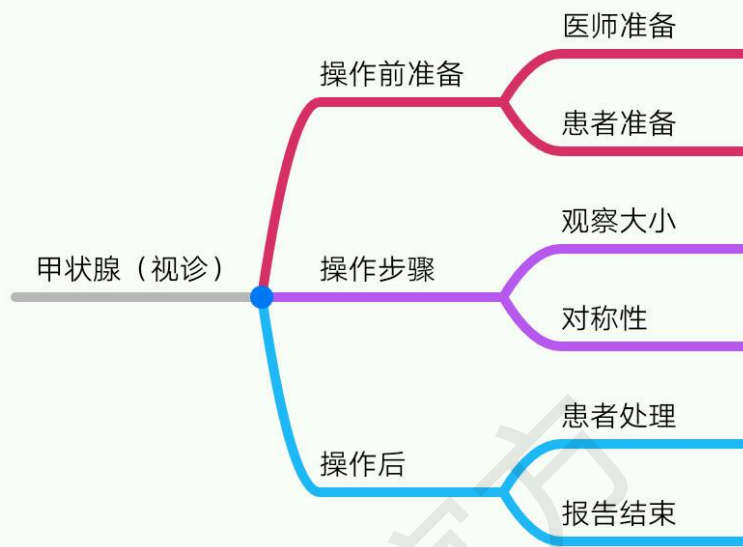
左, 左上, 左下
 右, 右上, 右下

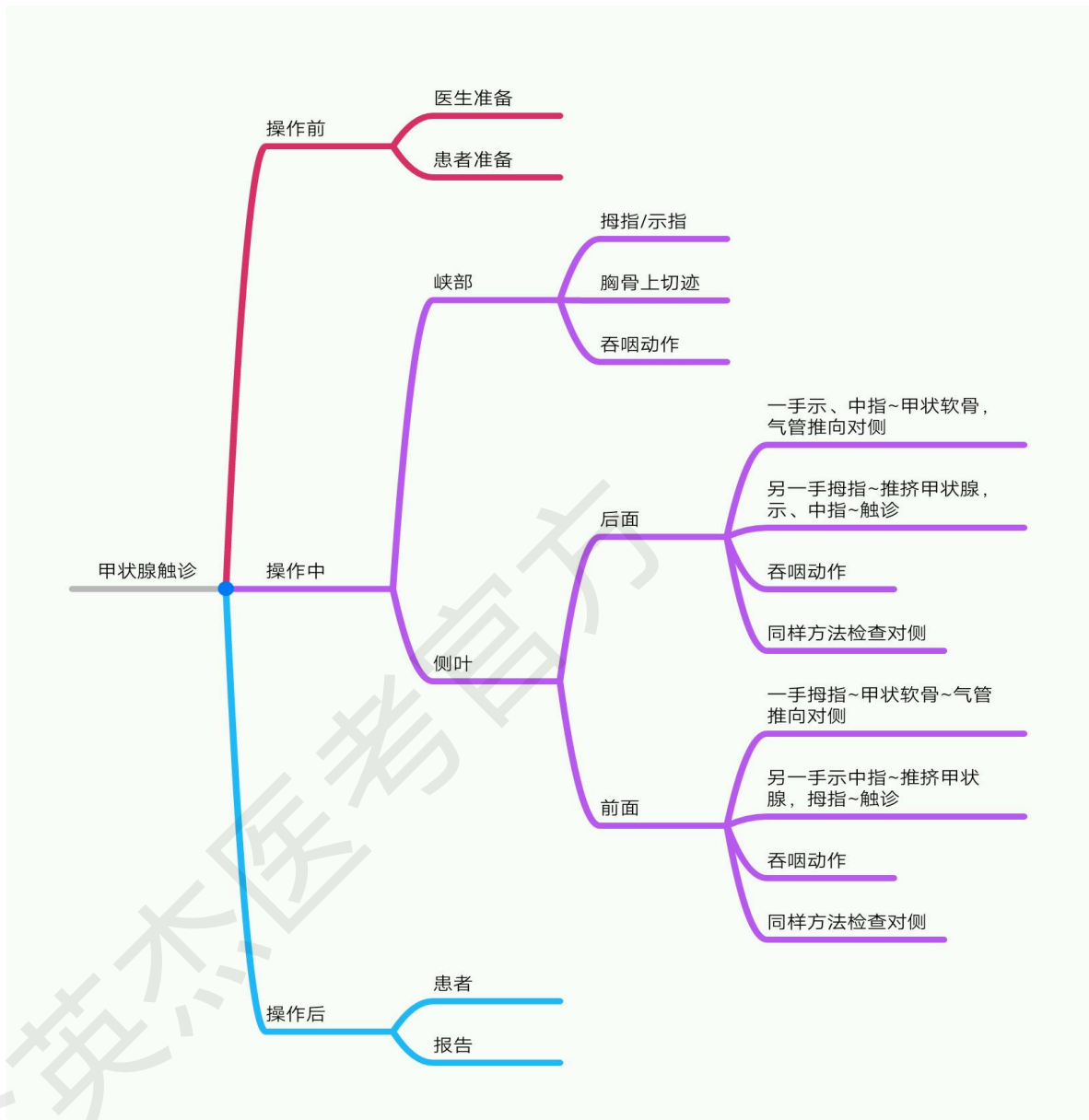


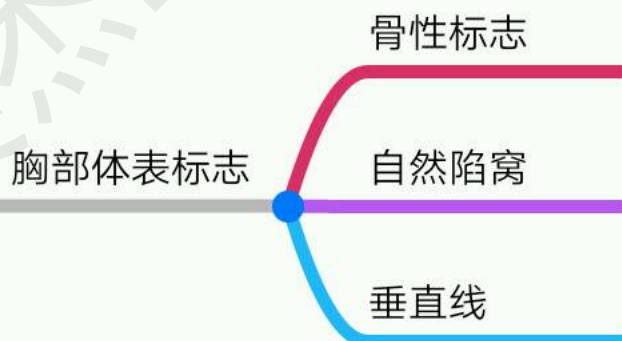
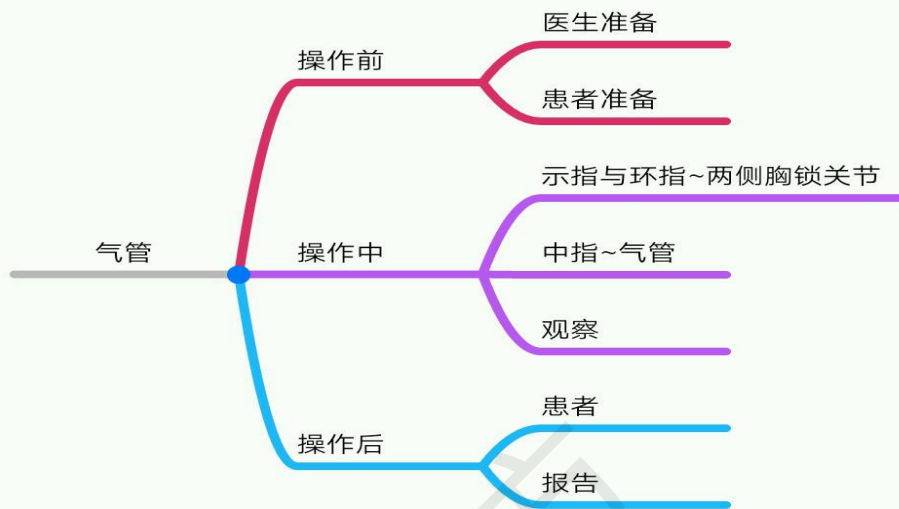
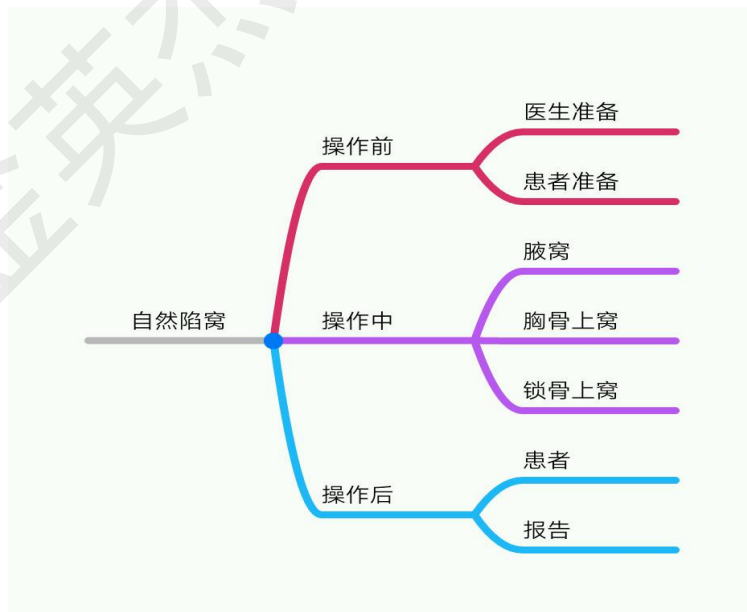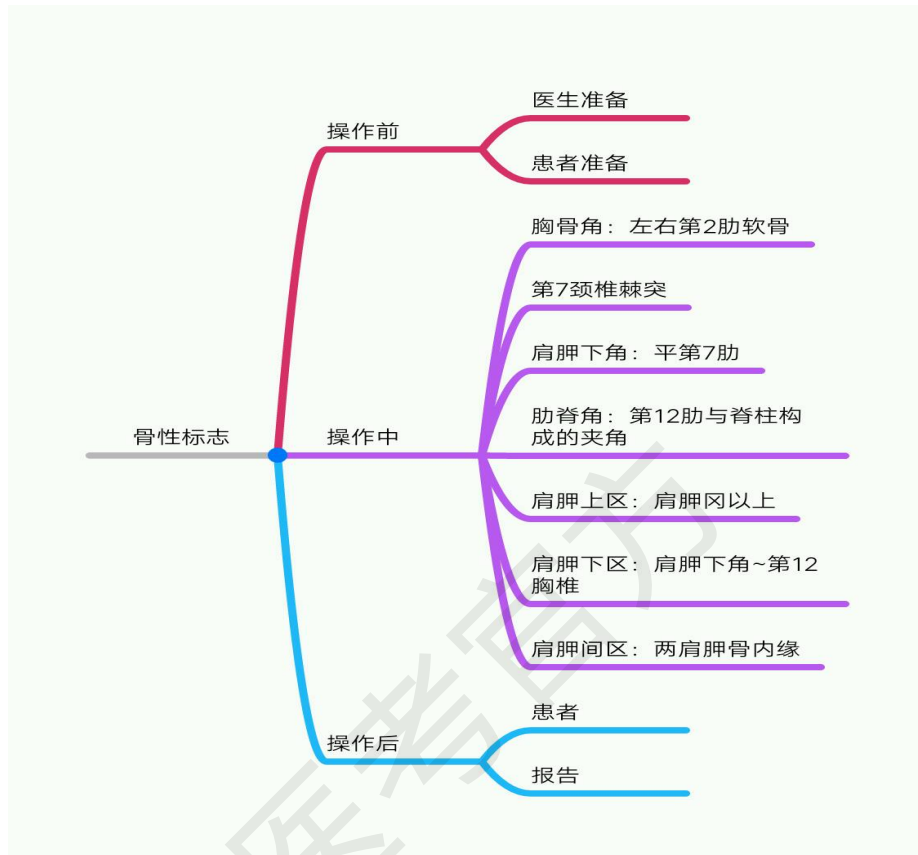


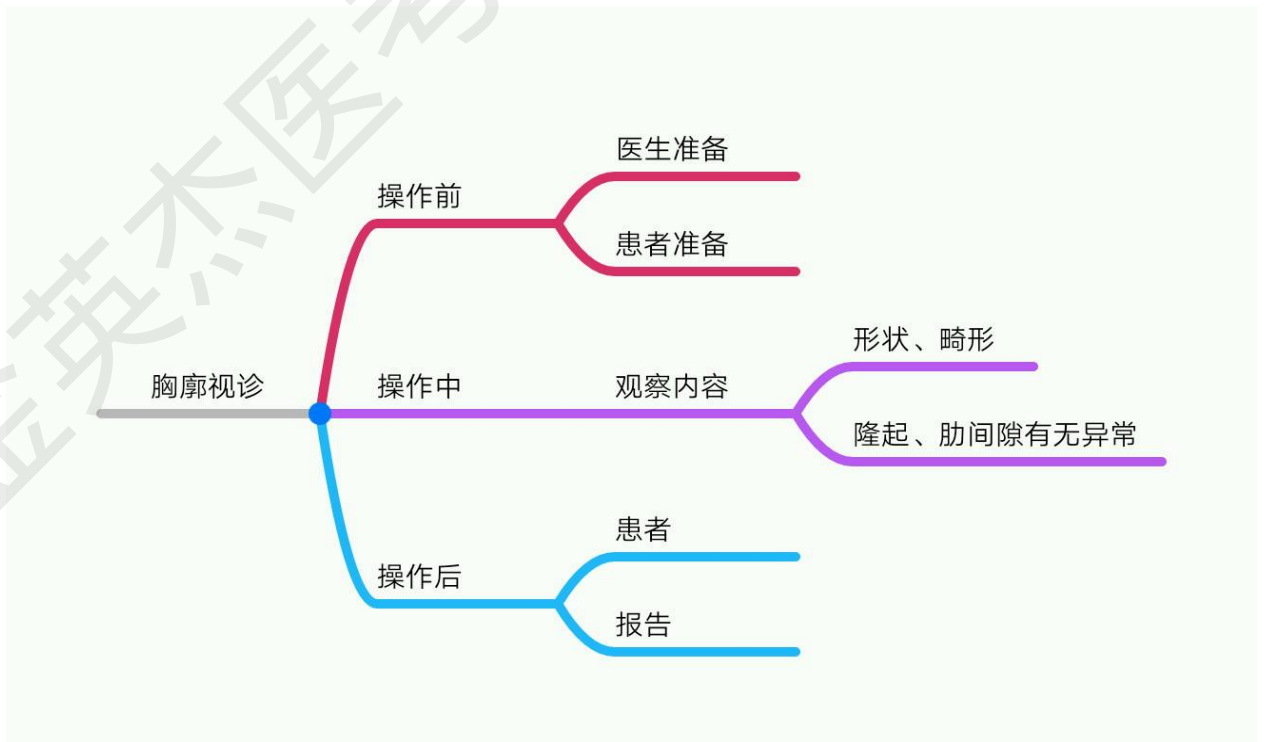
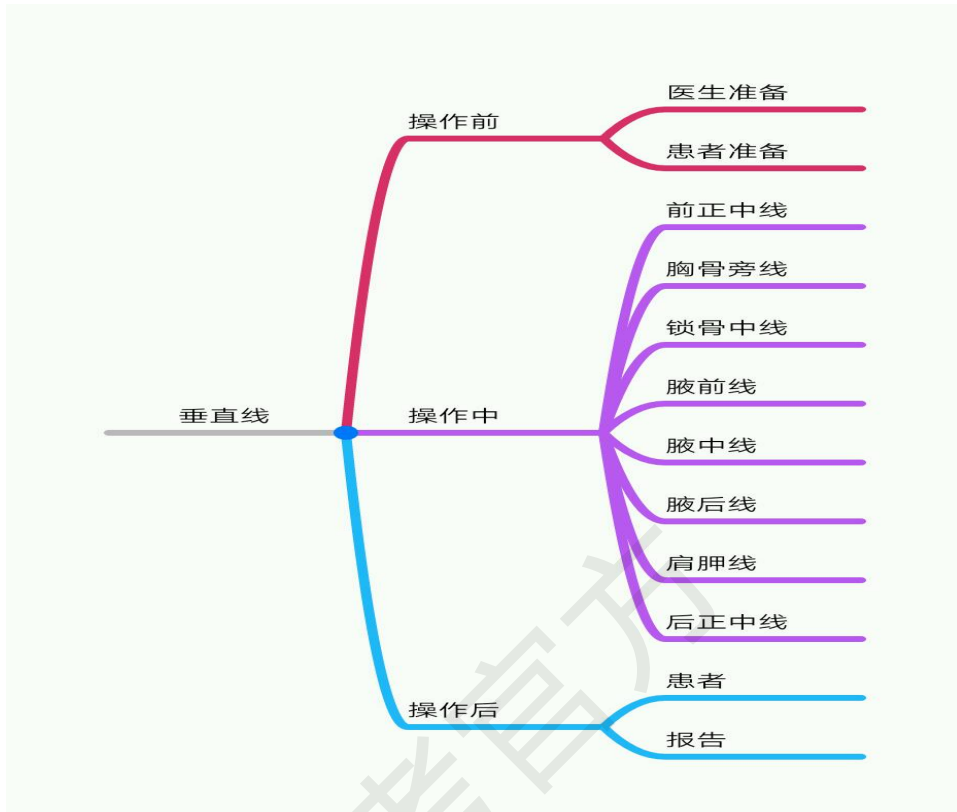


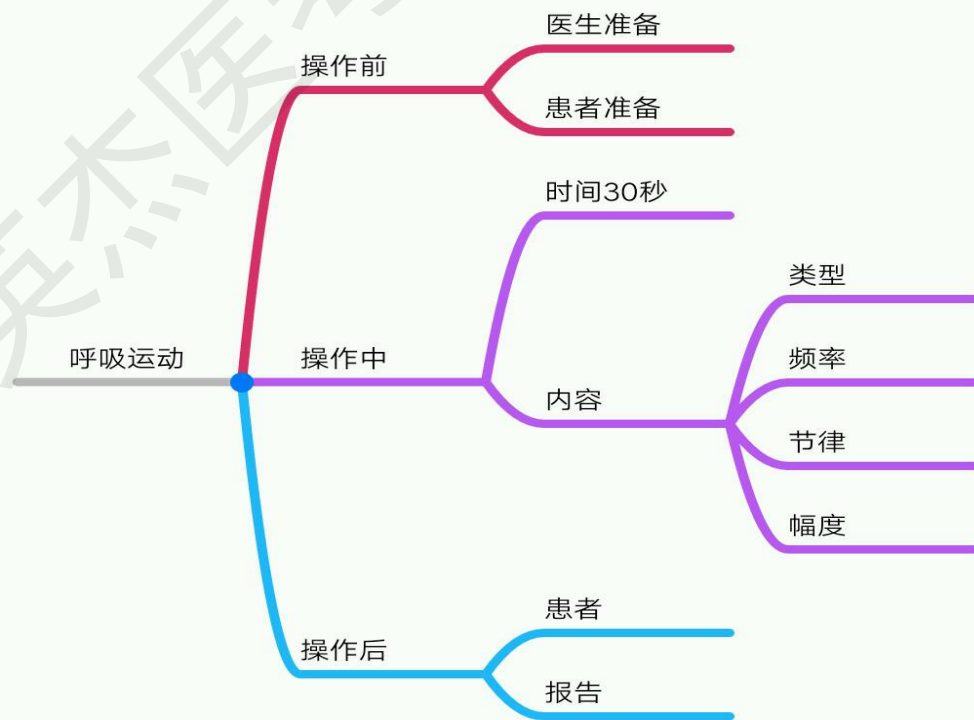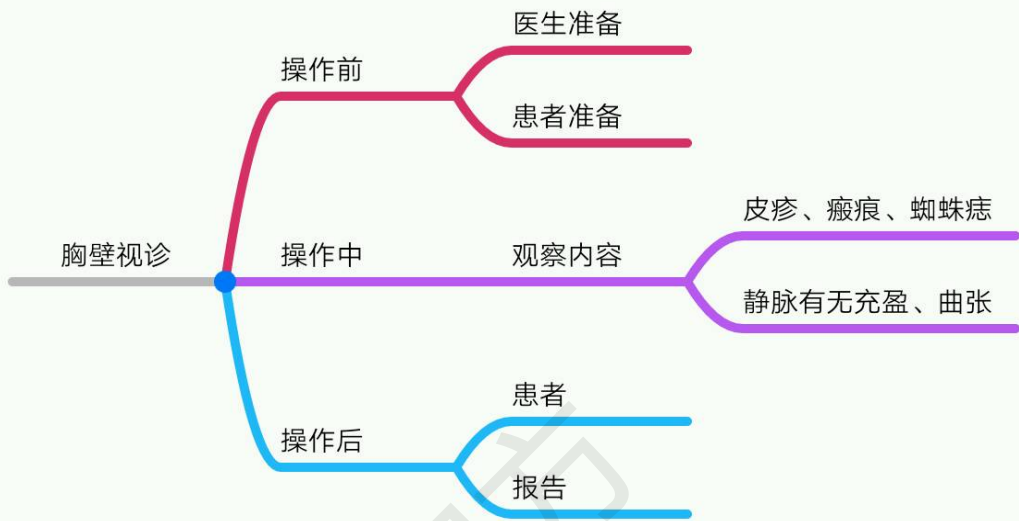


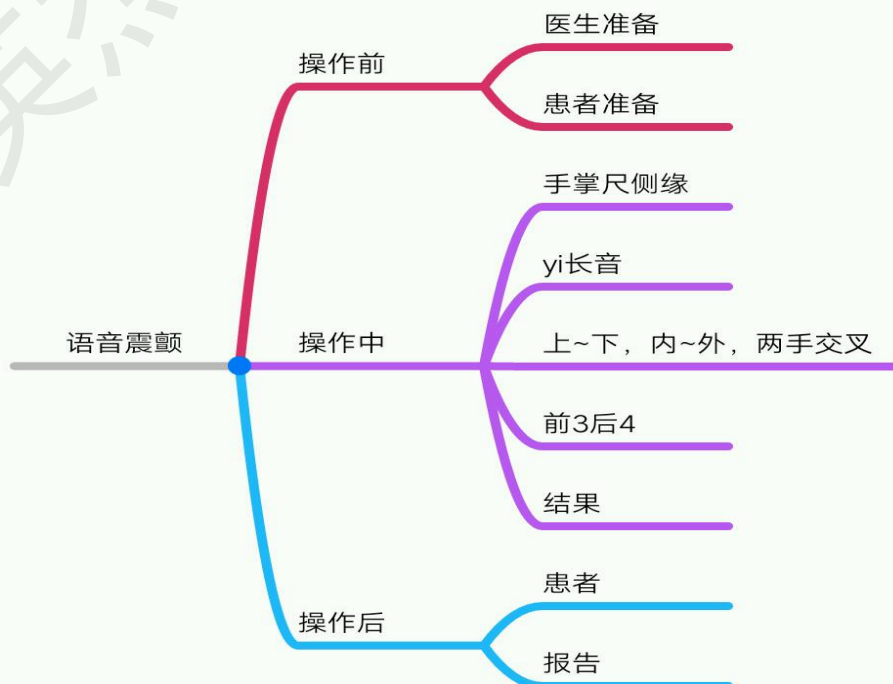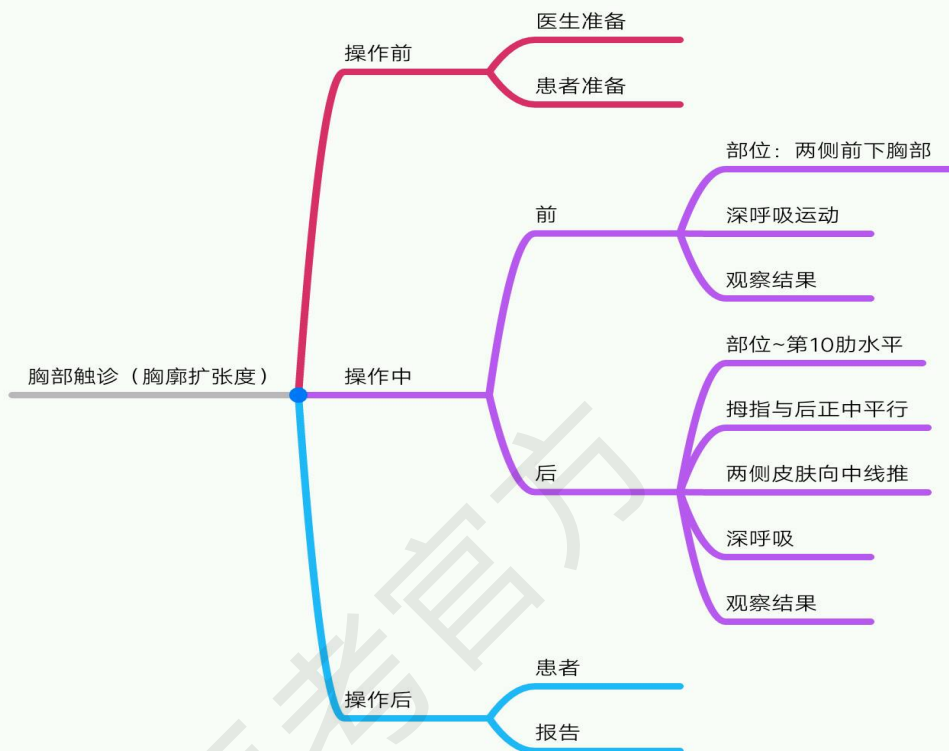


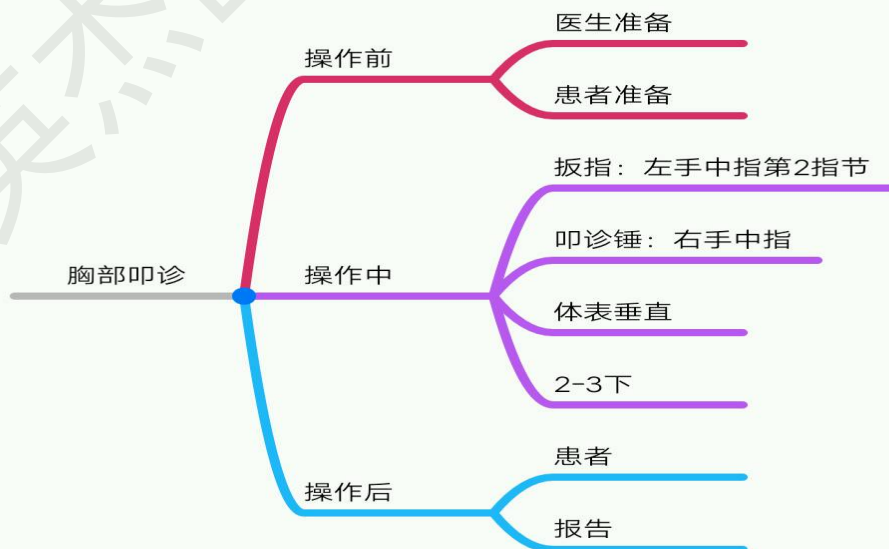


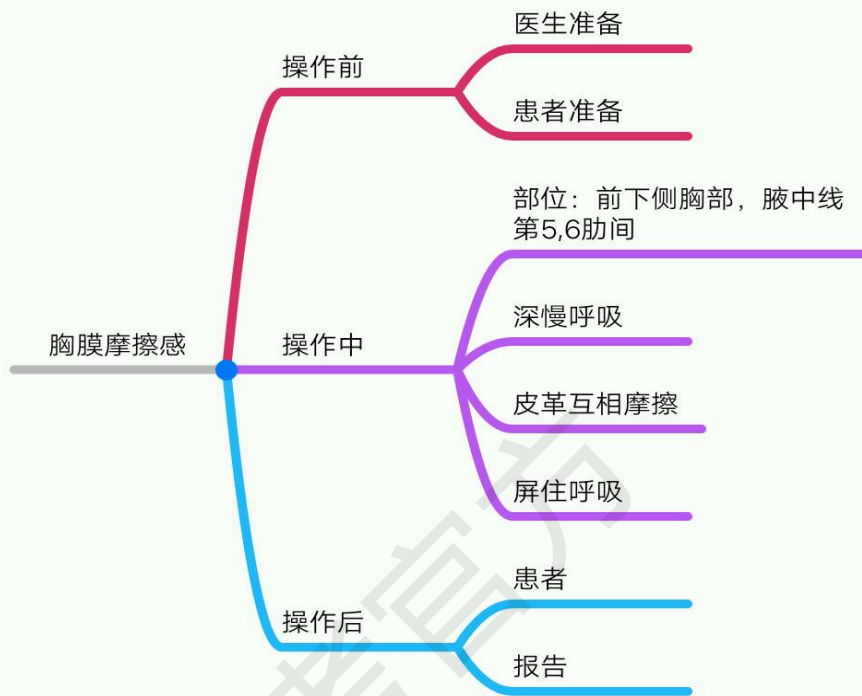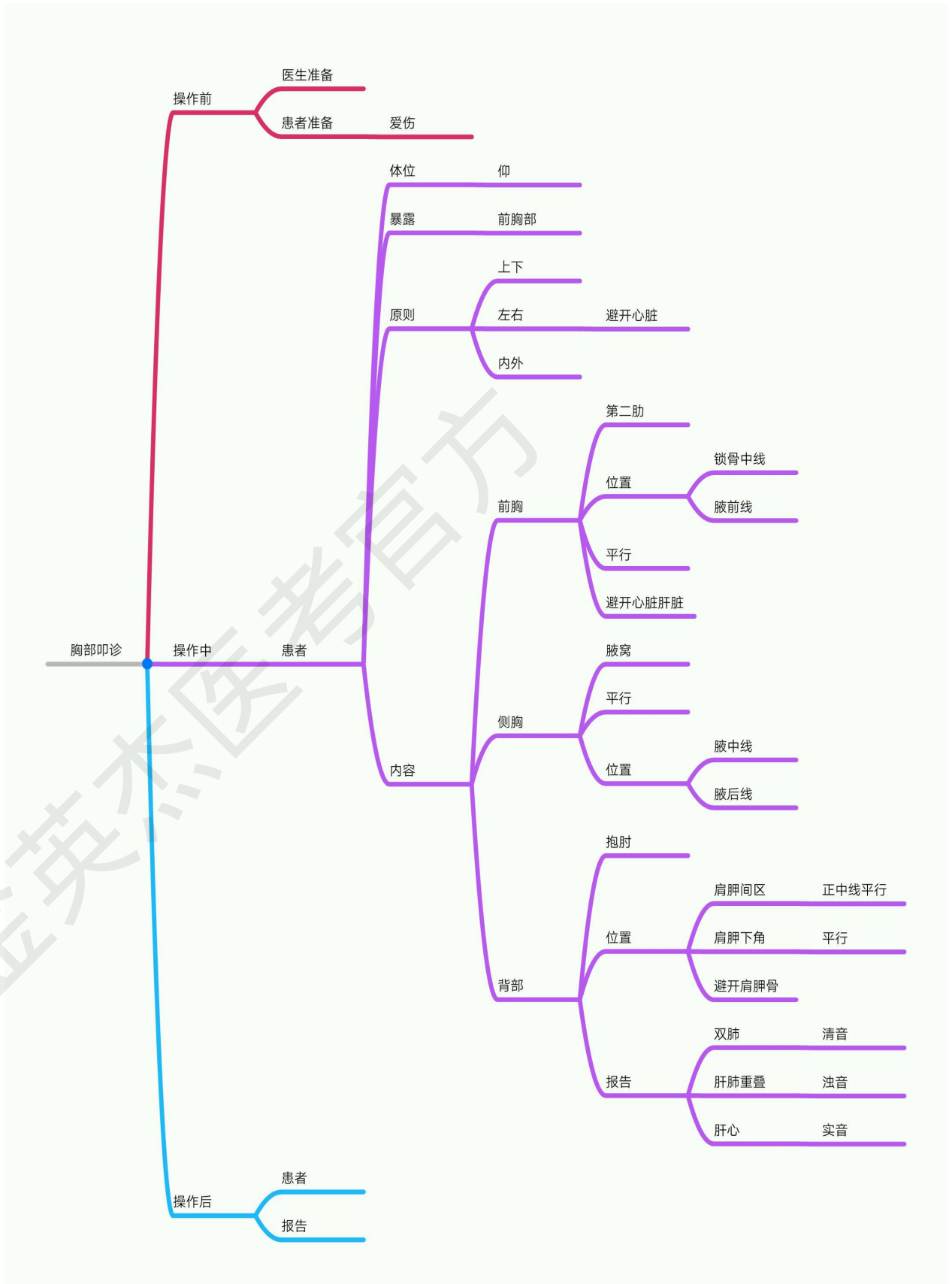


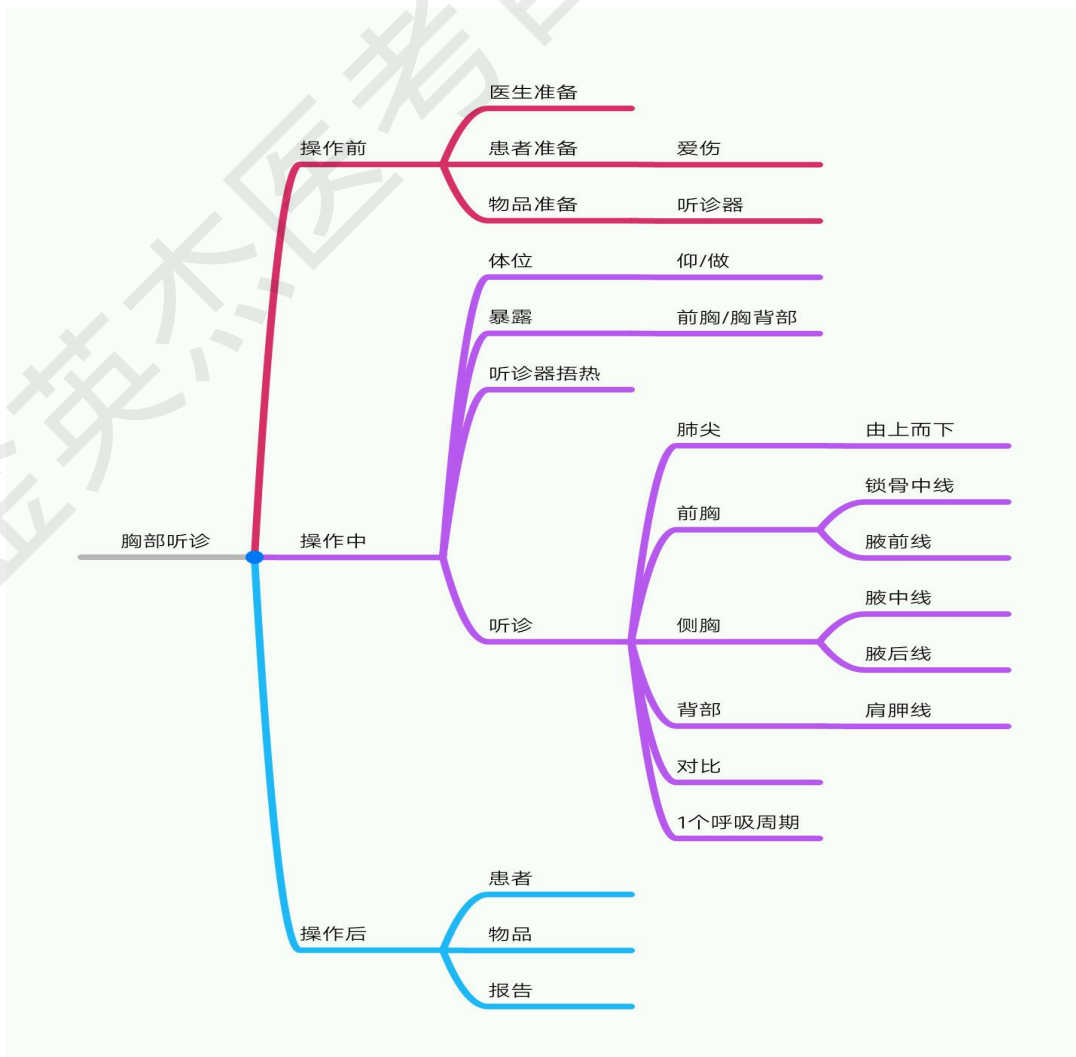
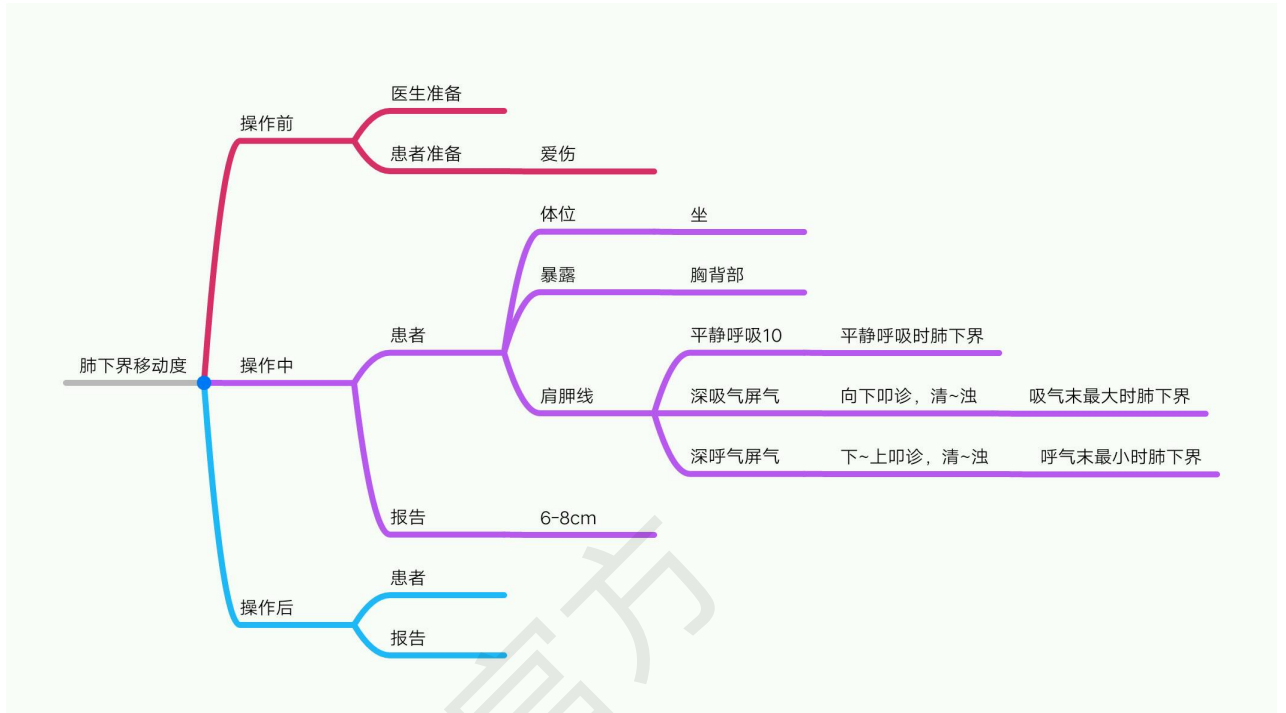


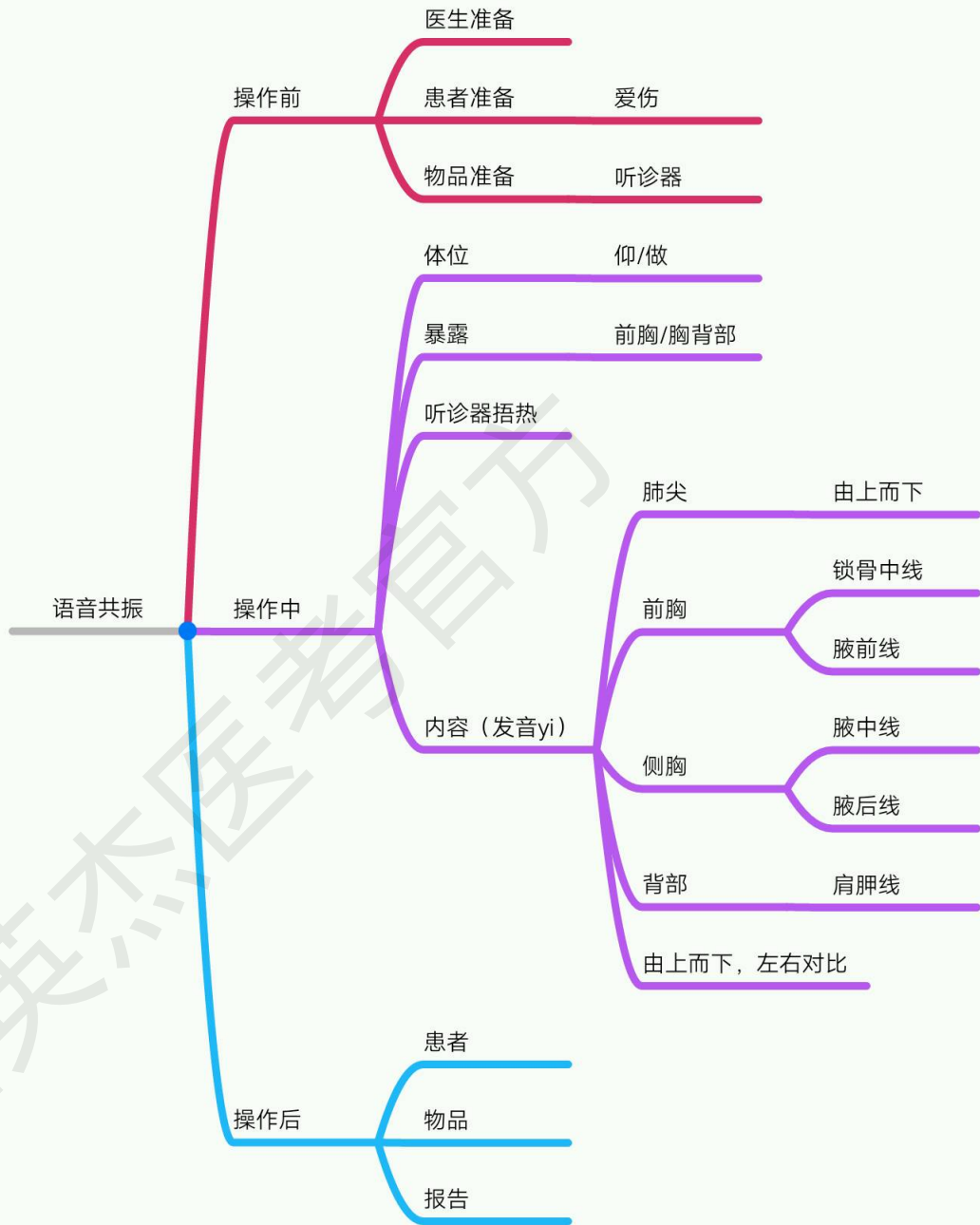


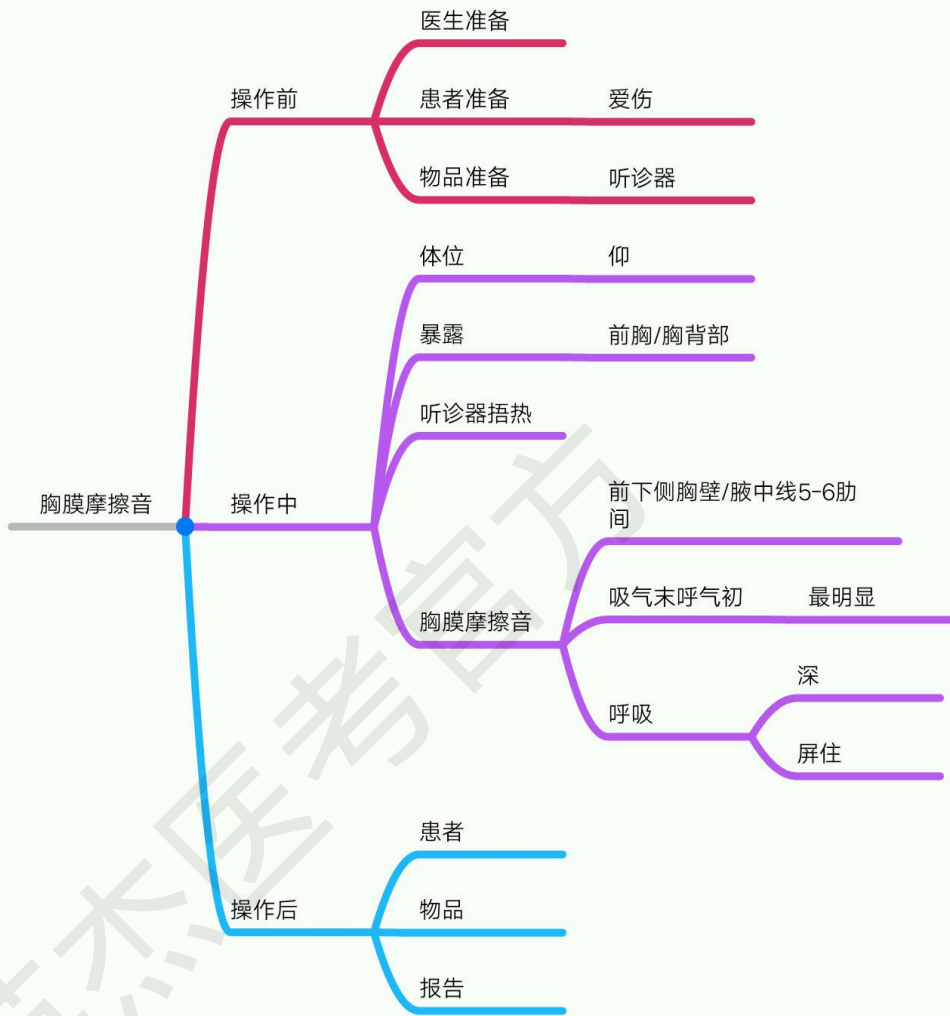


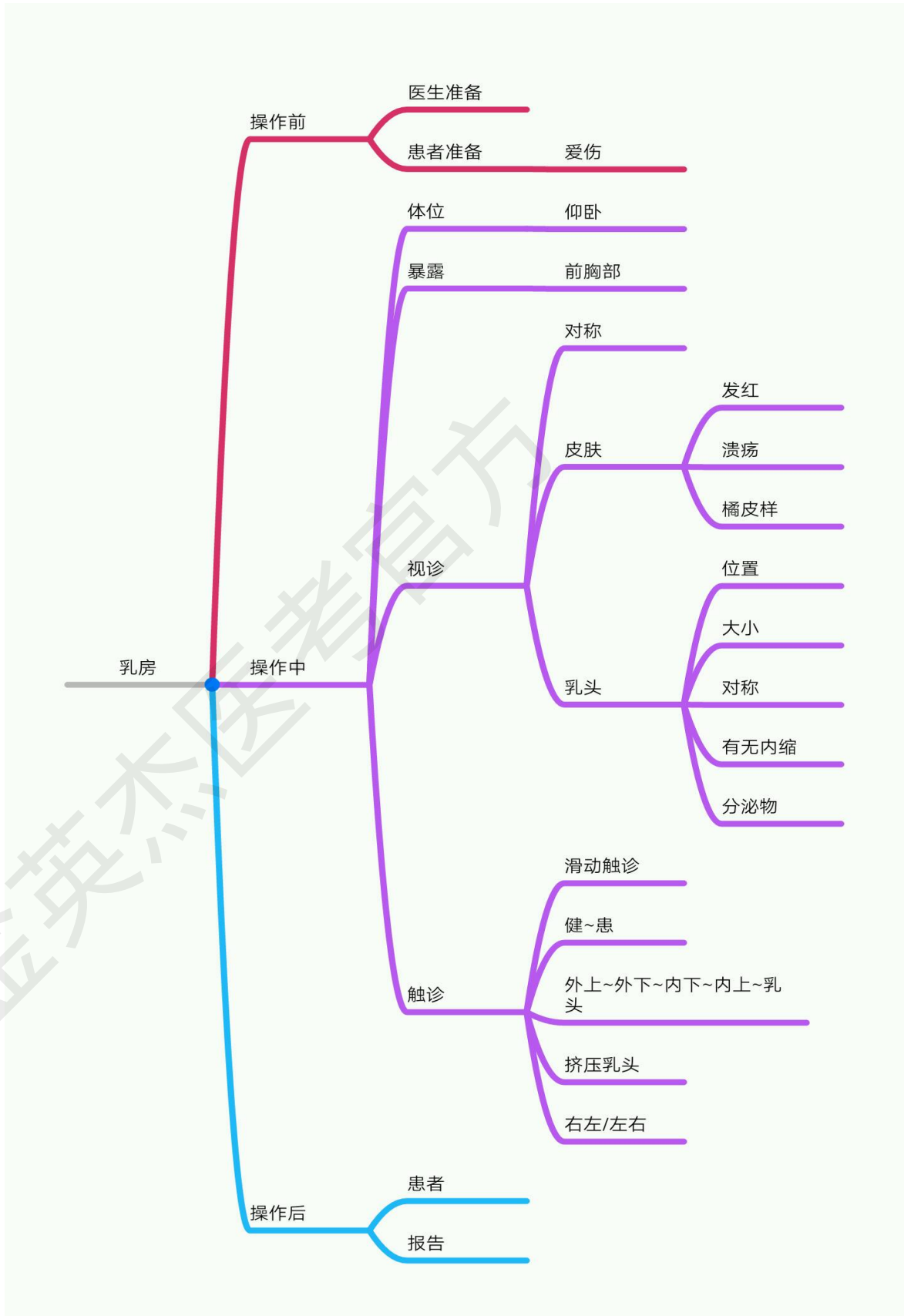


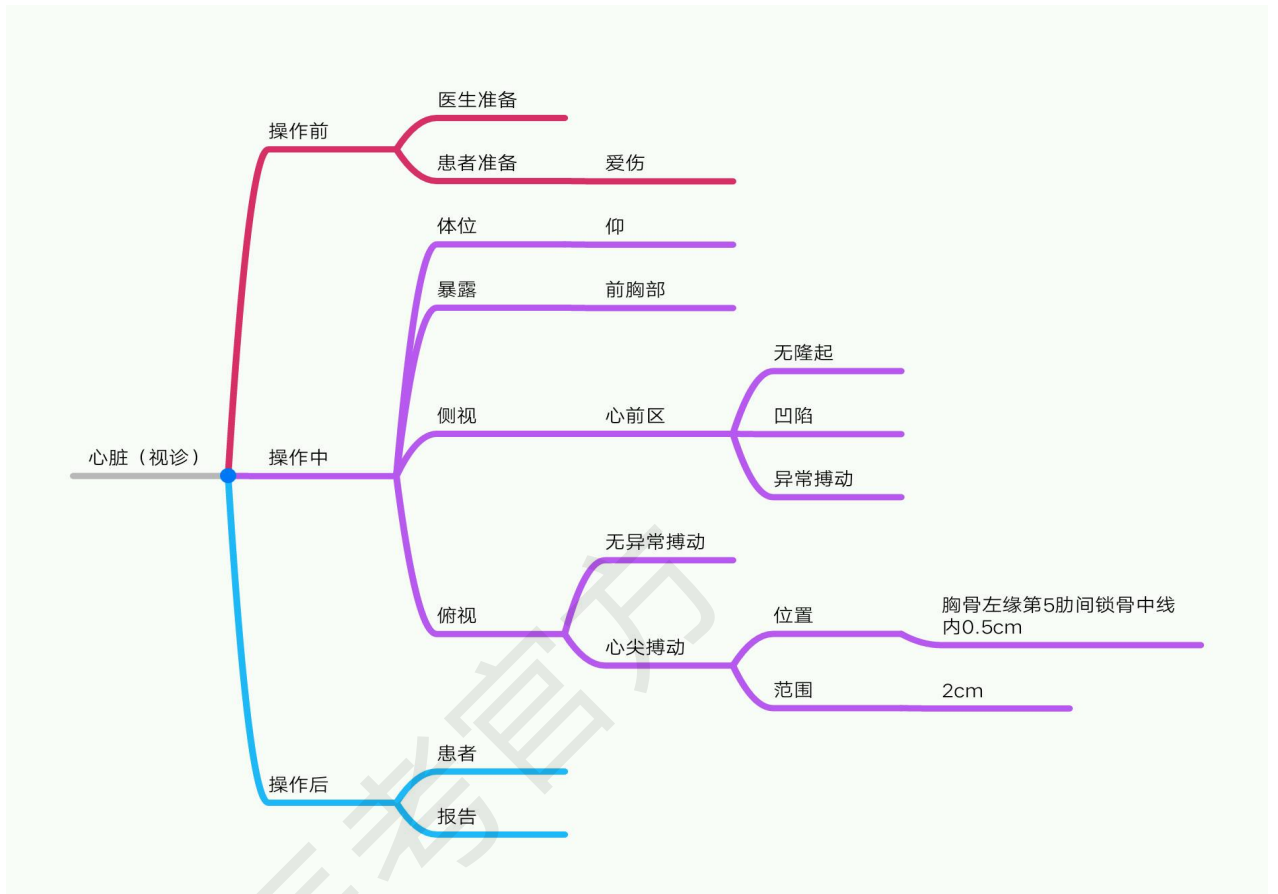


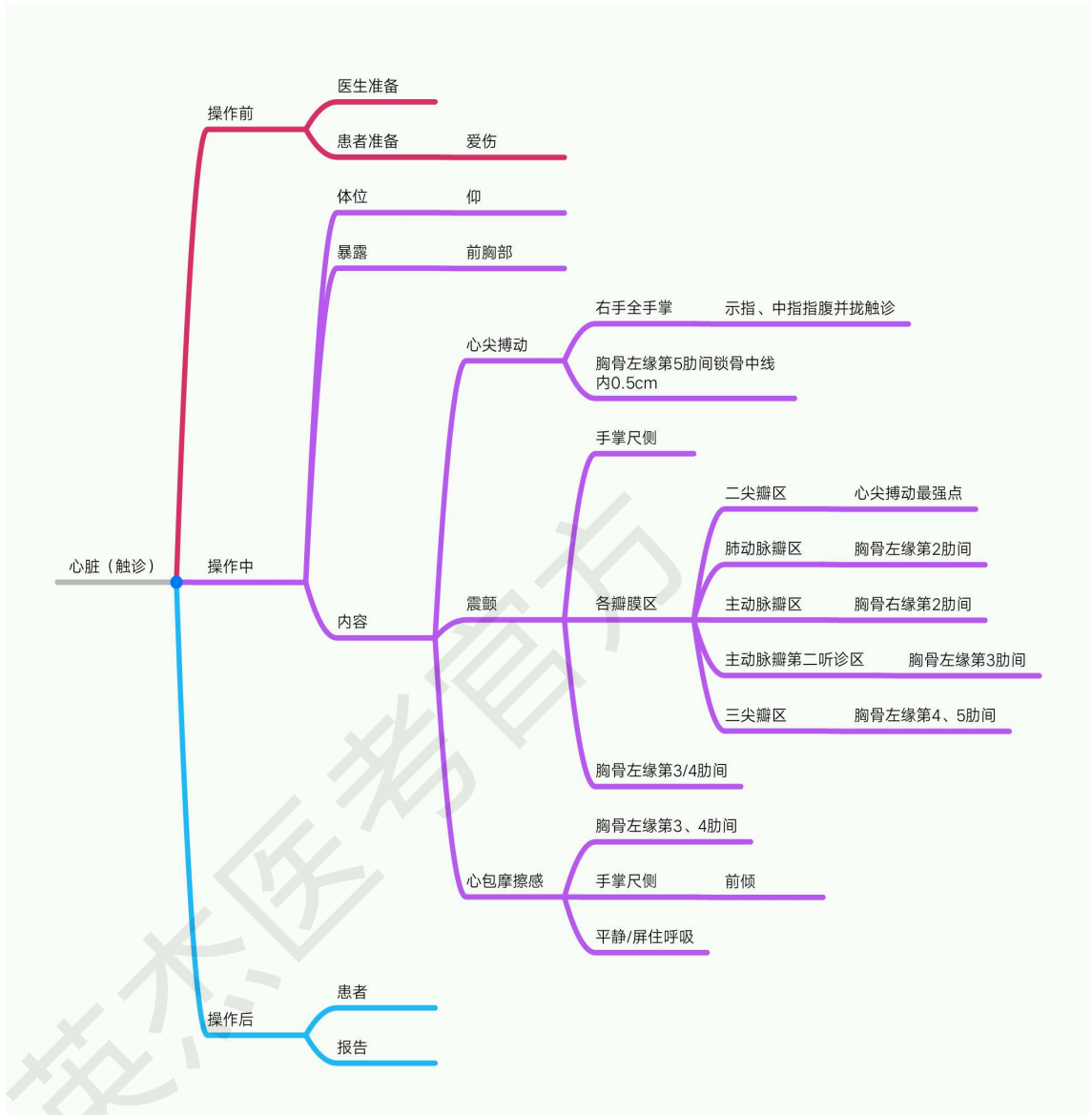


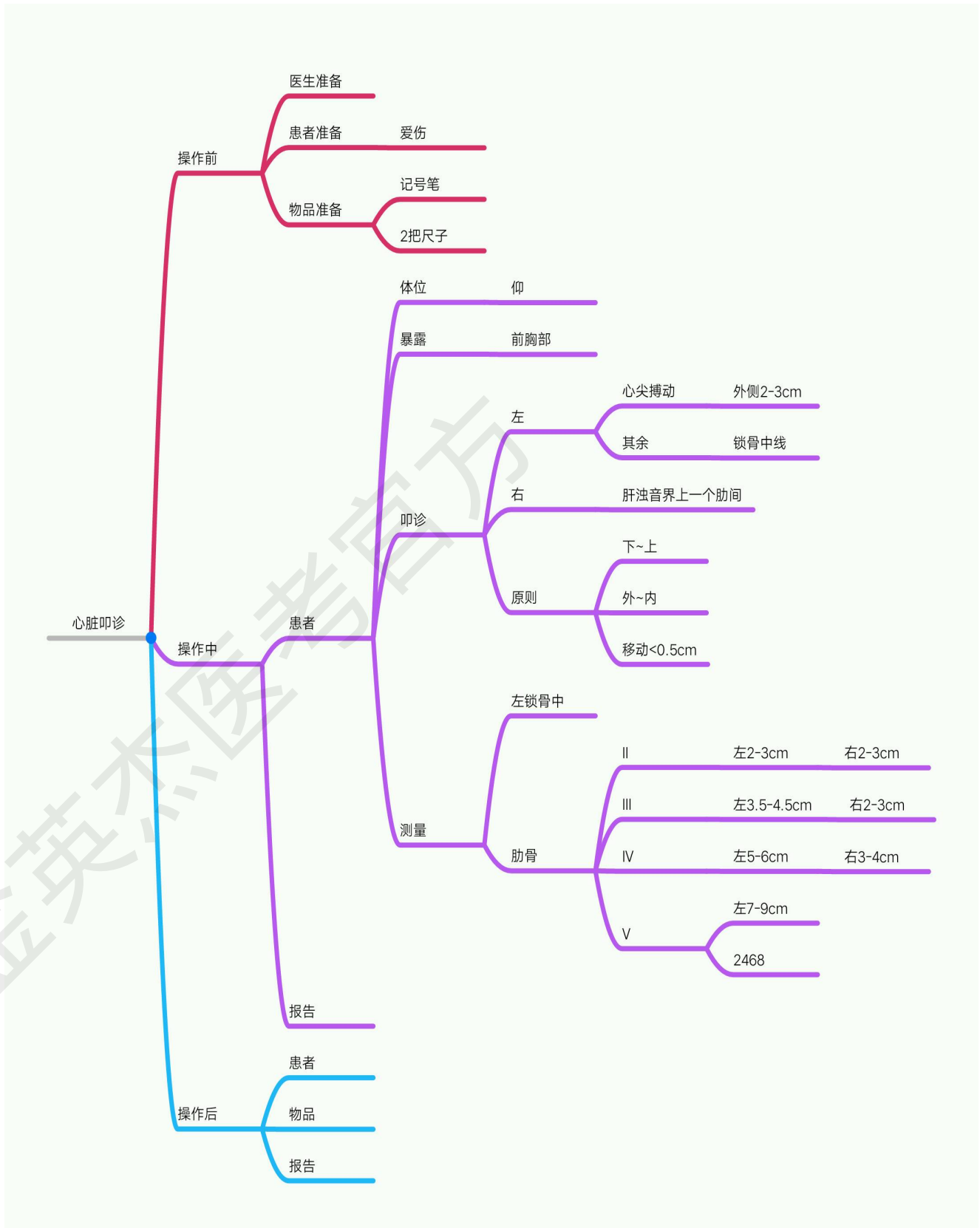


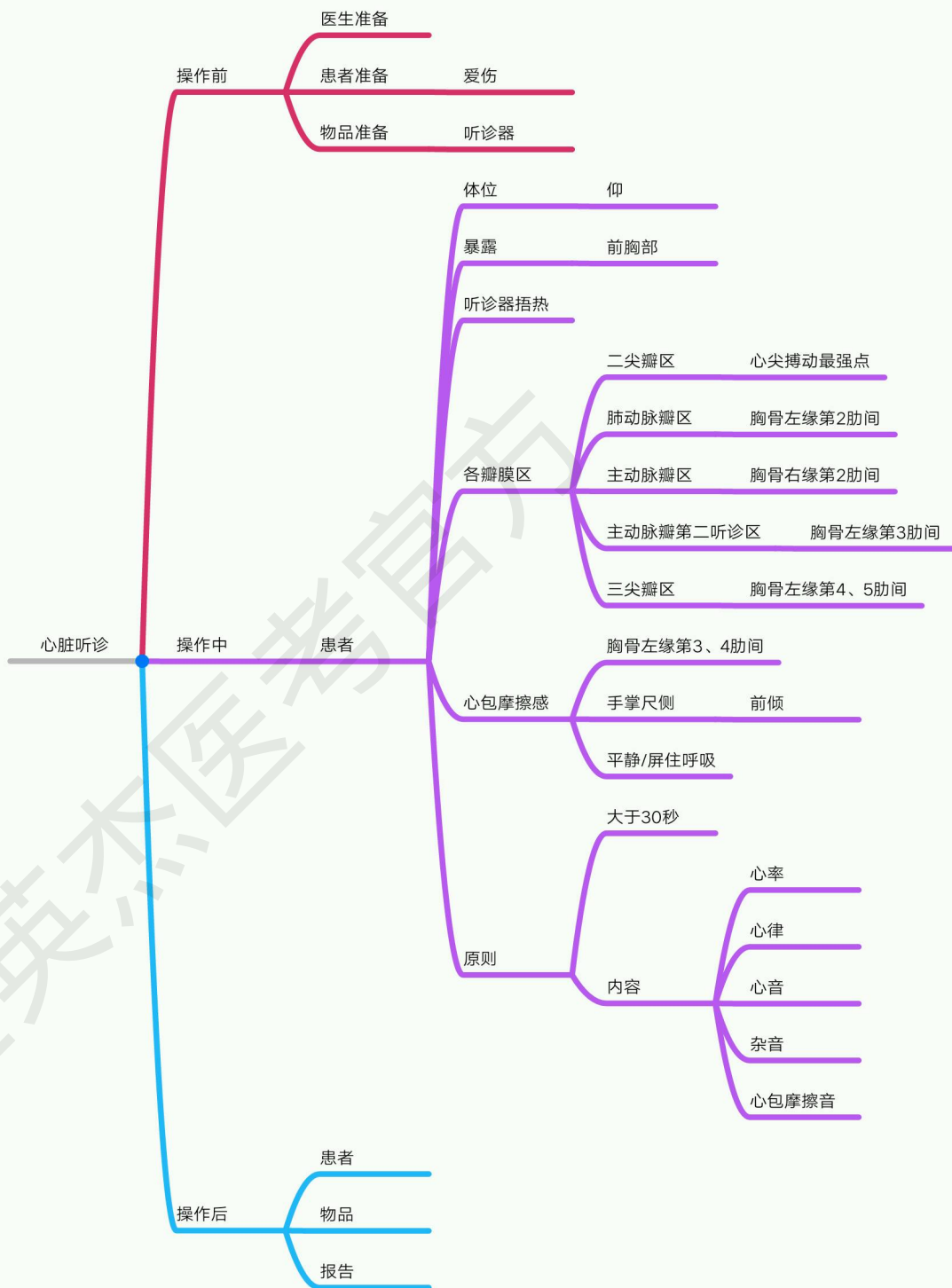


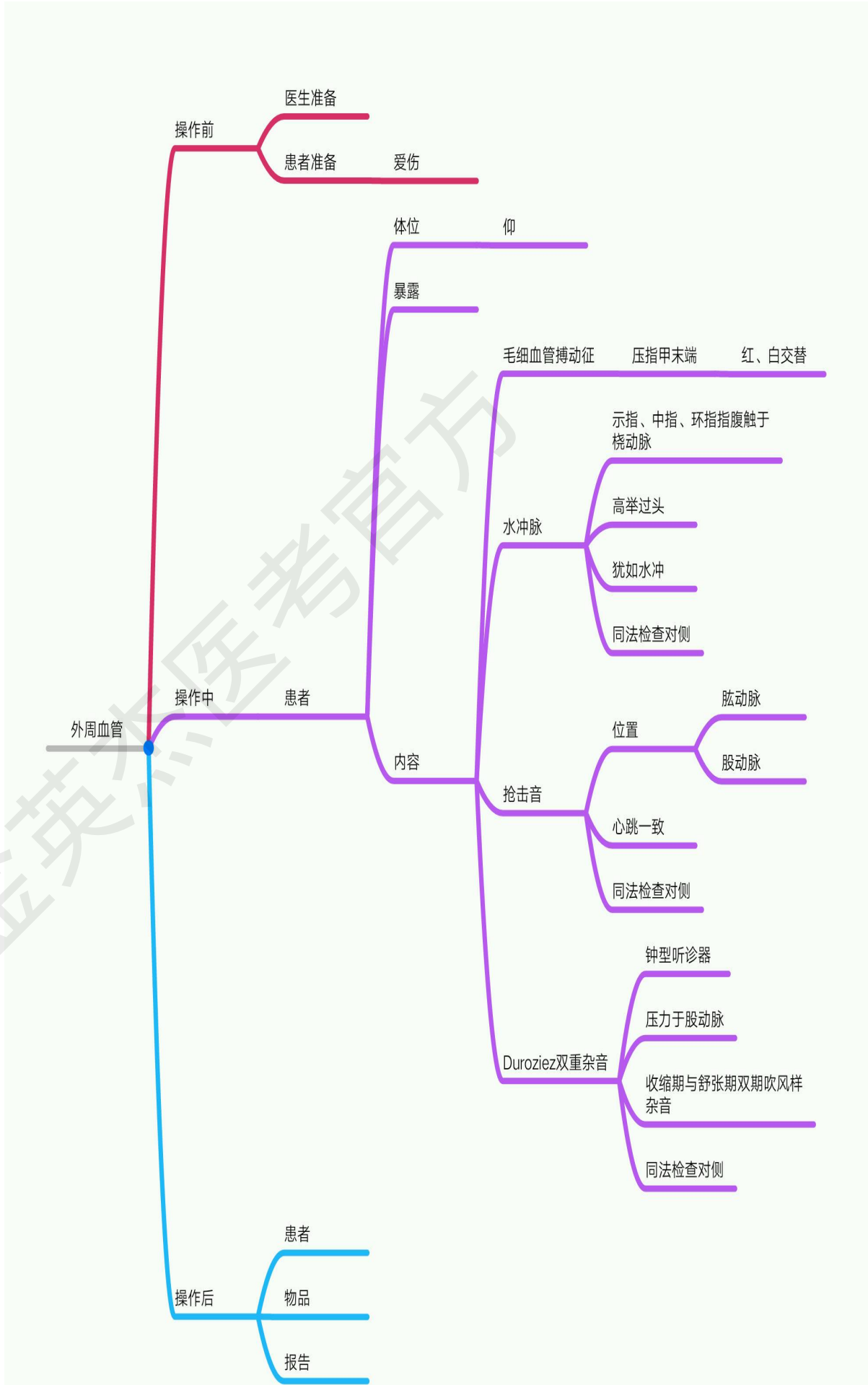


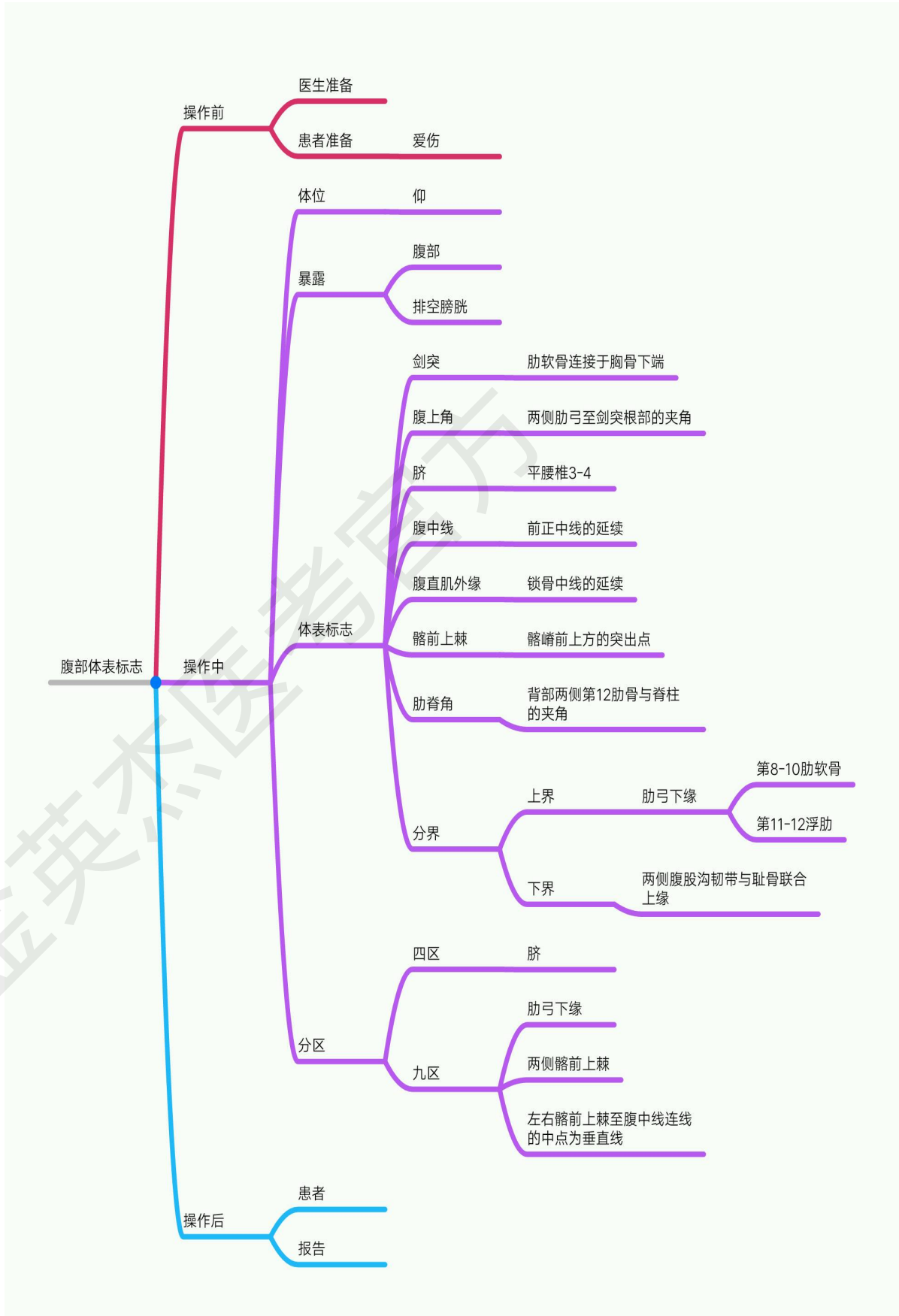


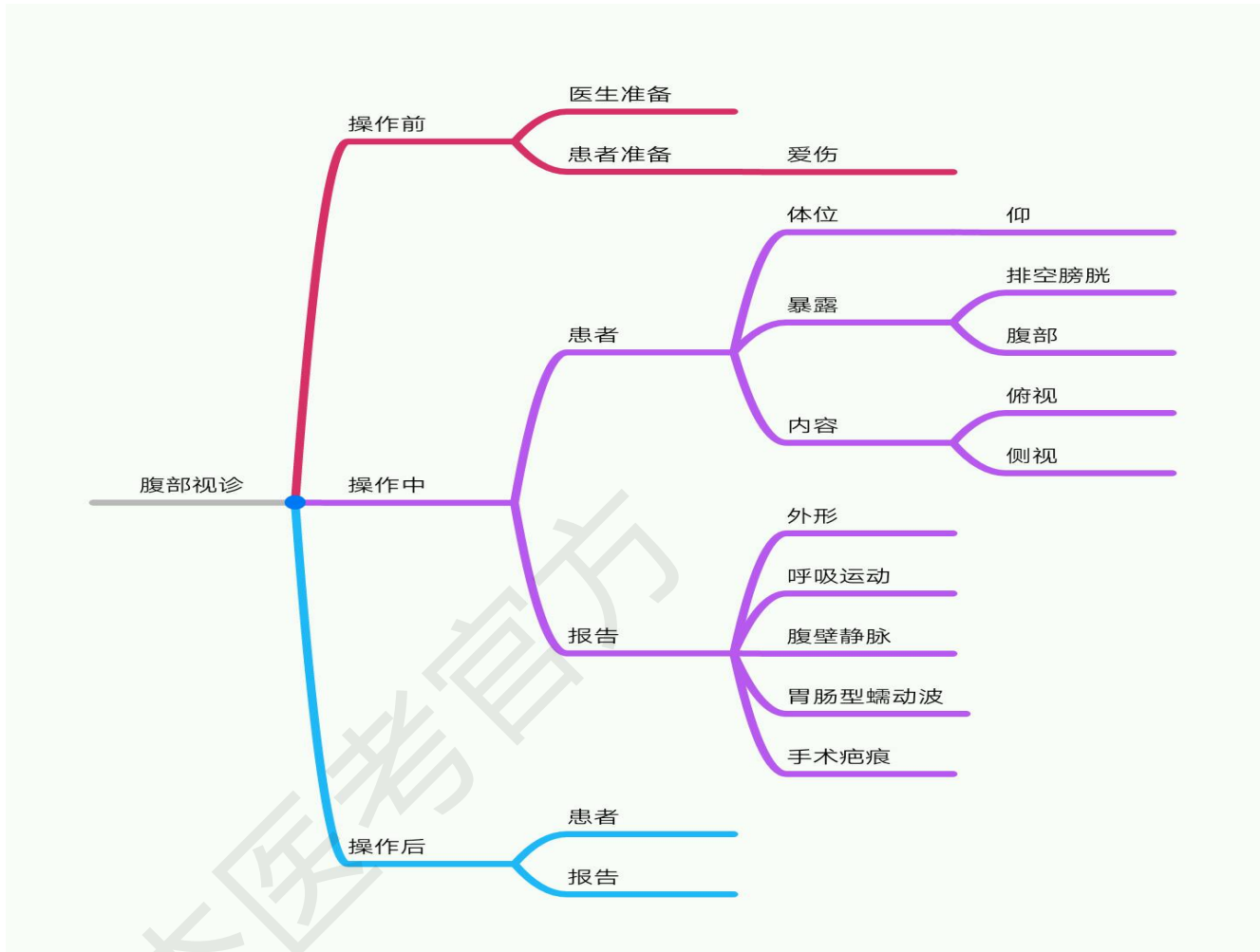


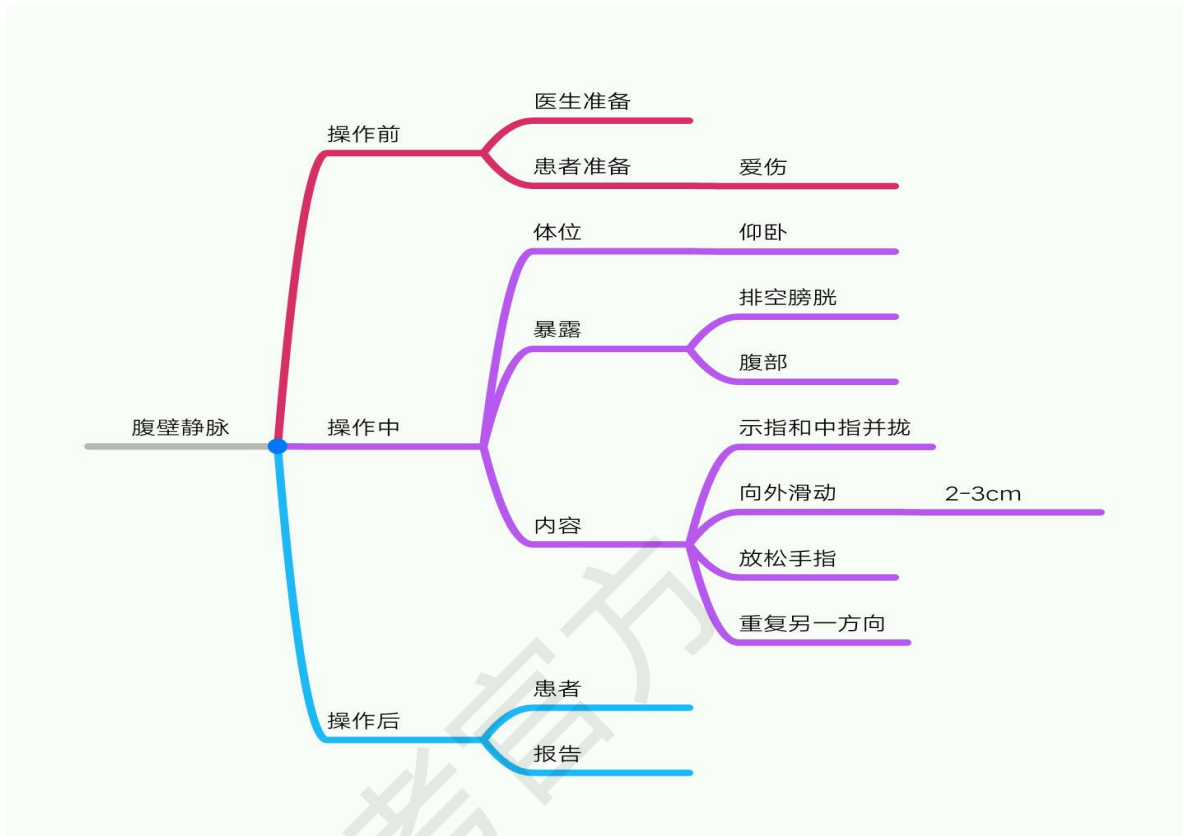




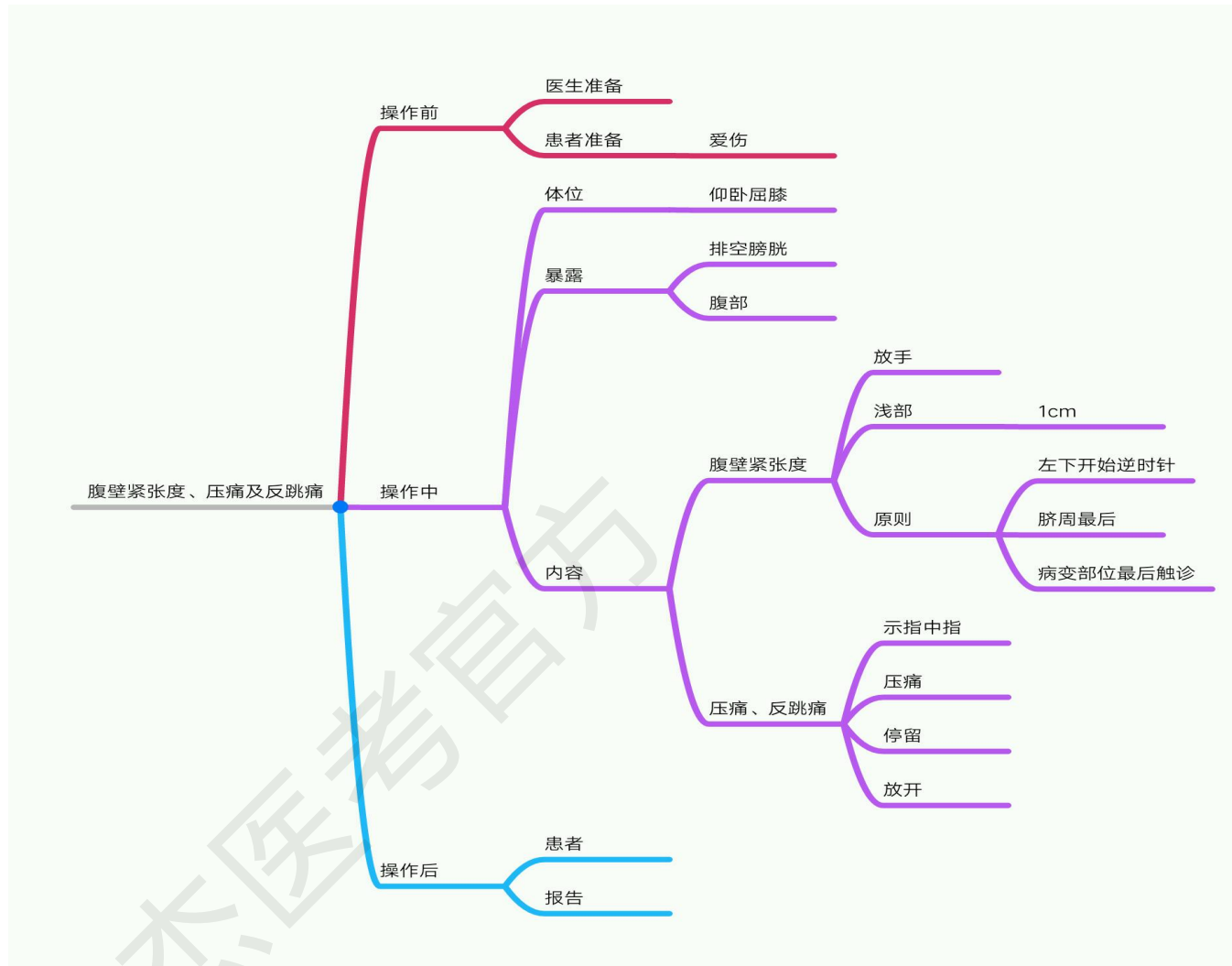


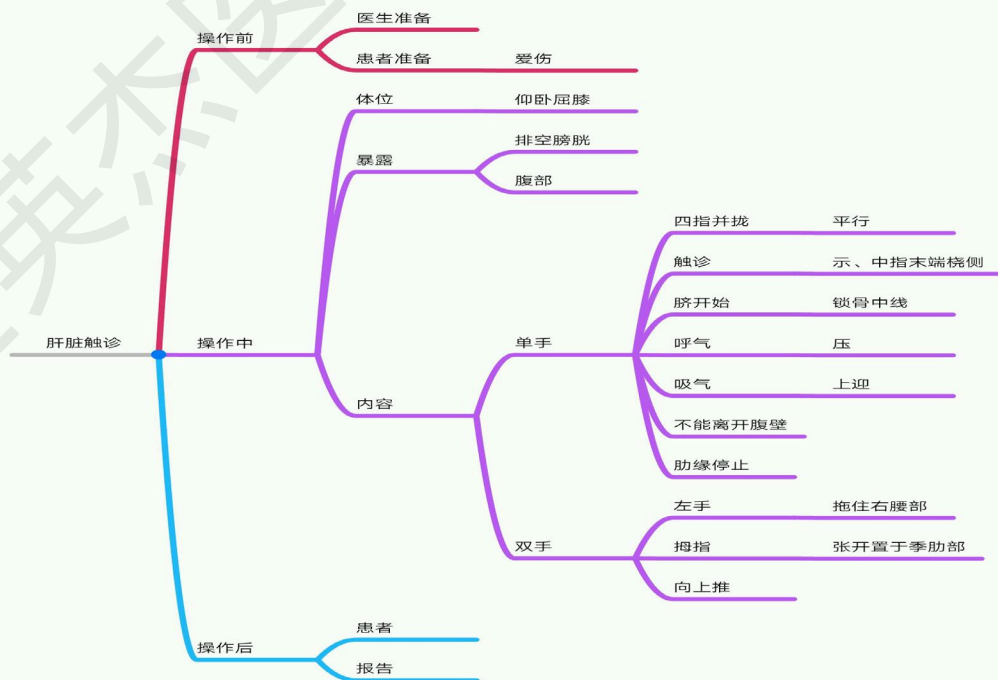
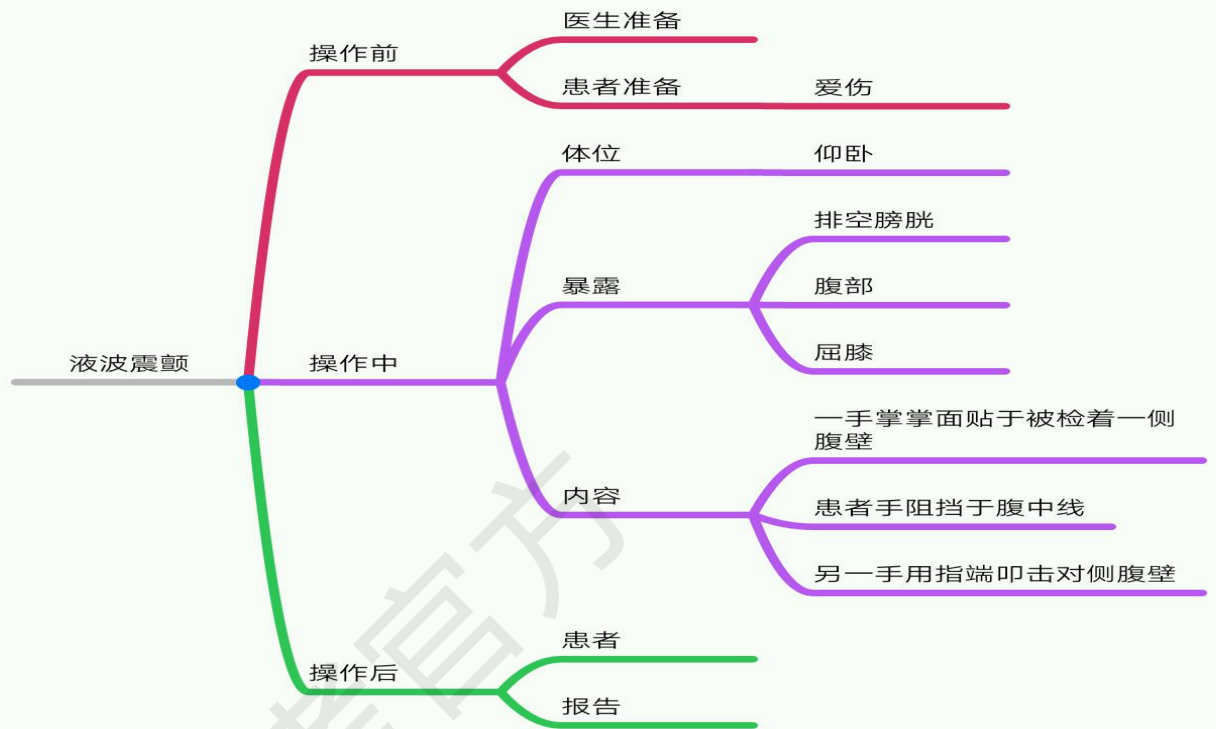


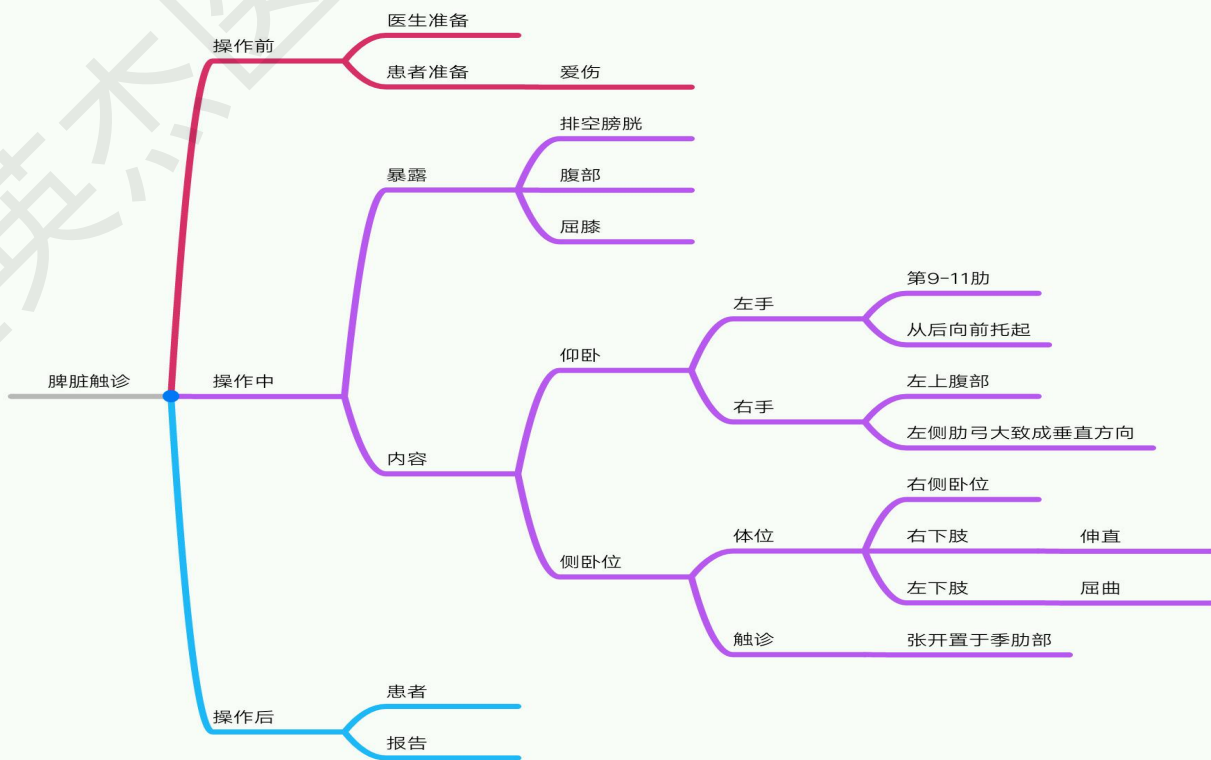
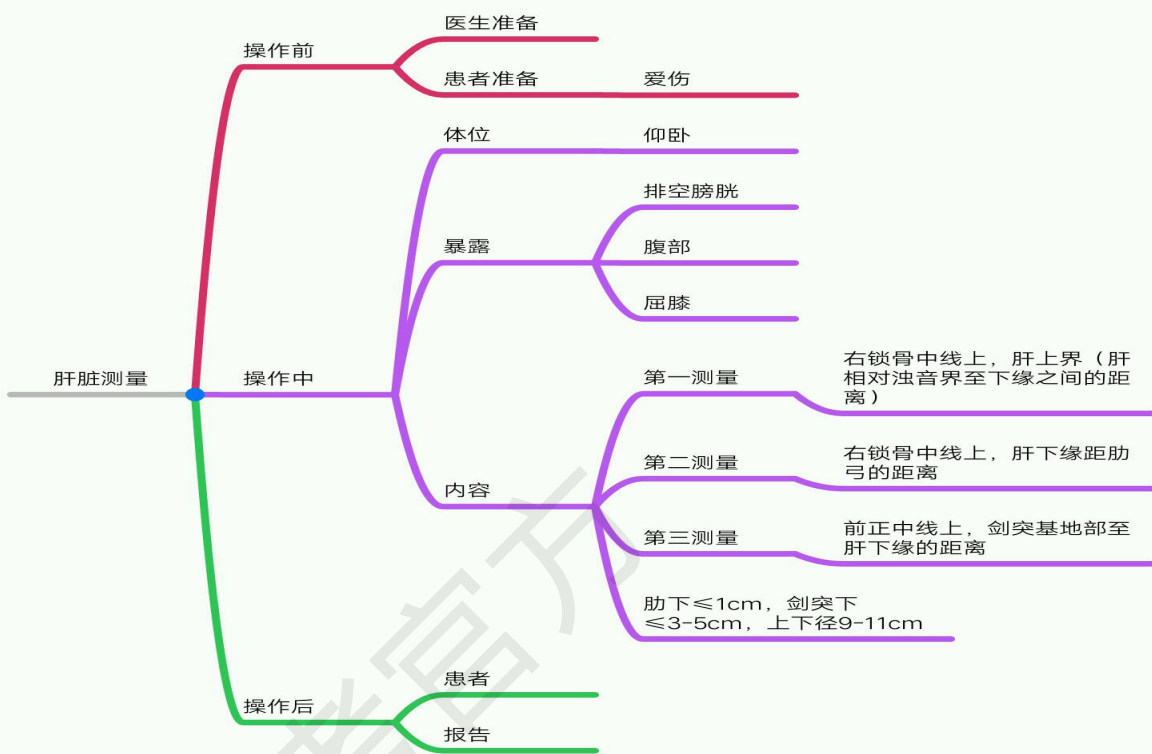


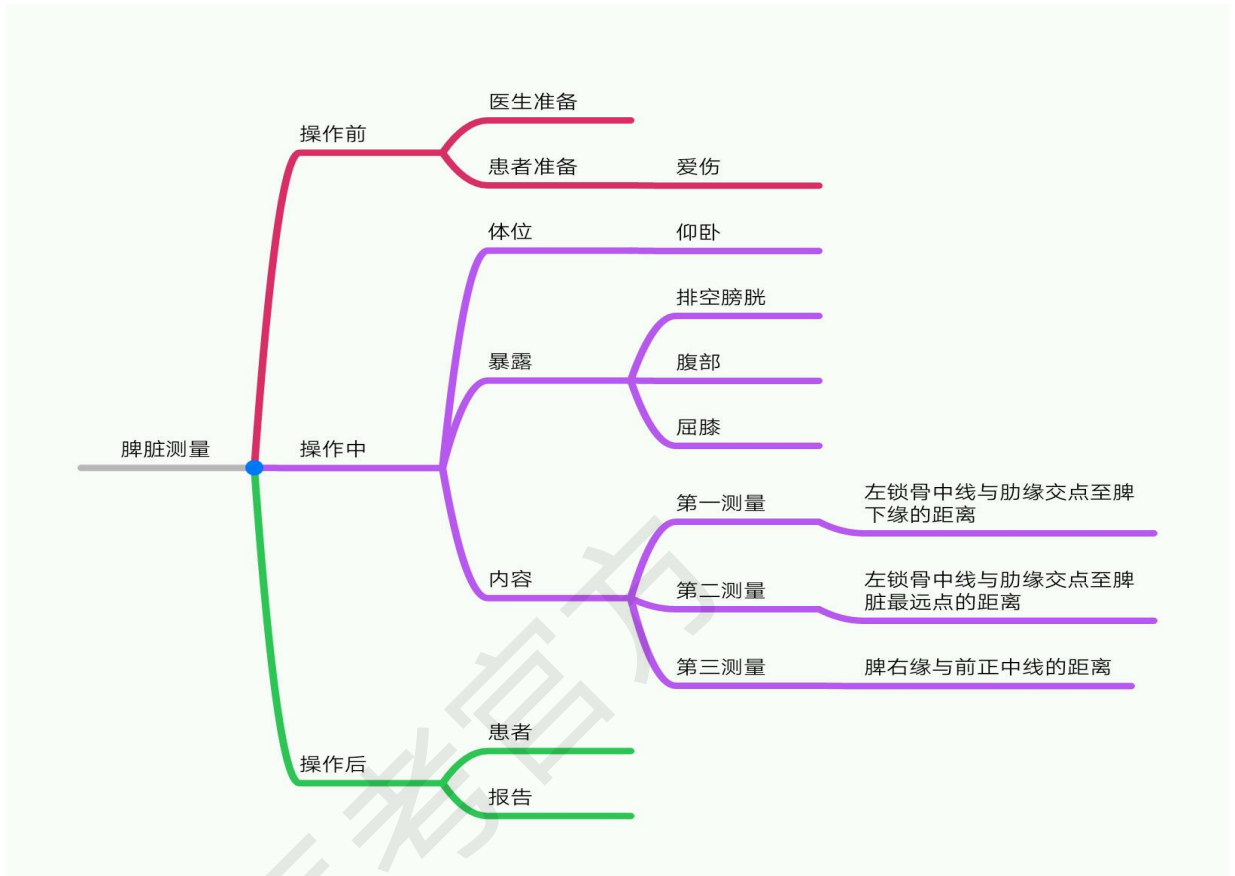


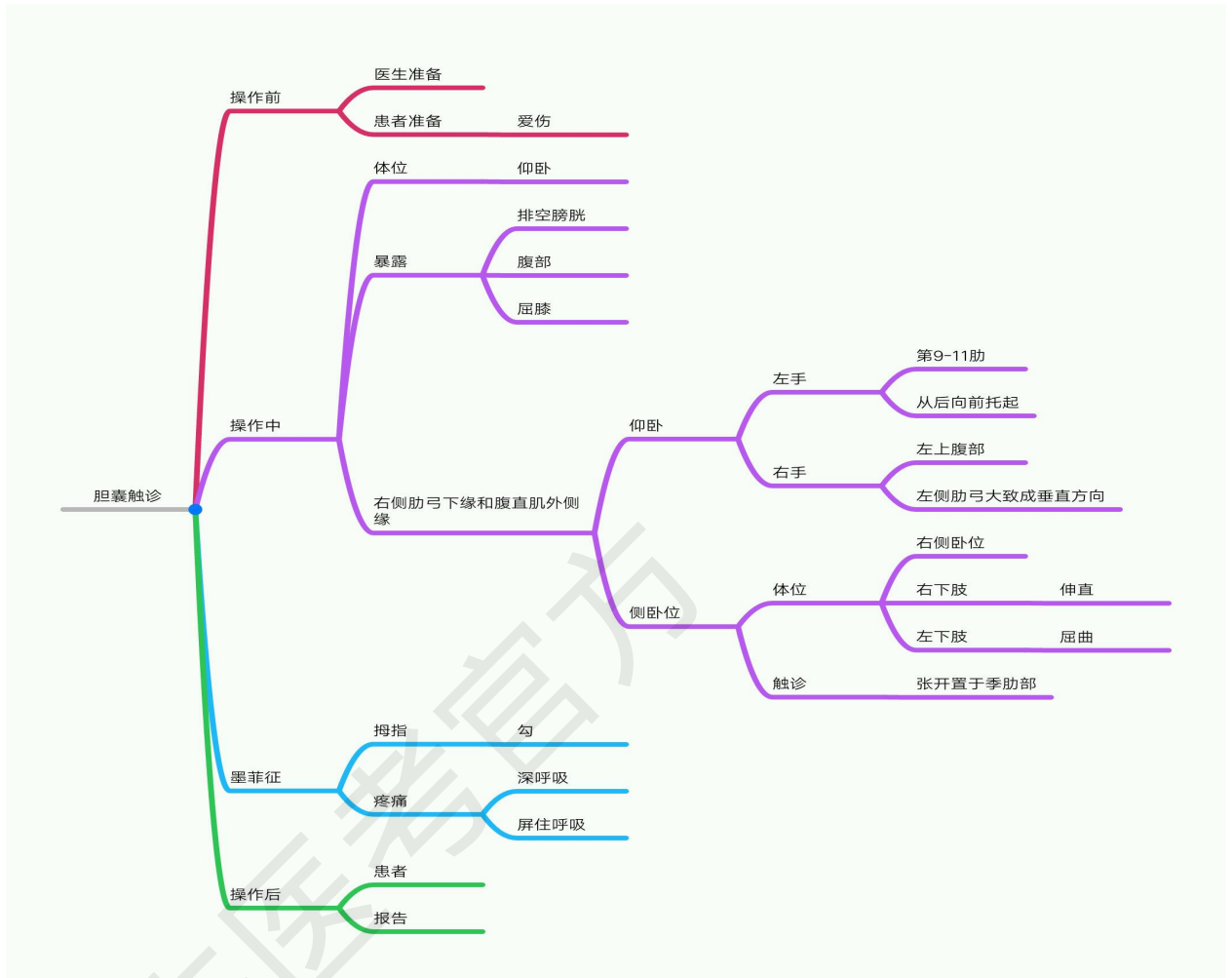
金英杰医考官方

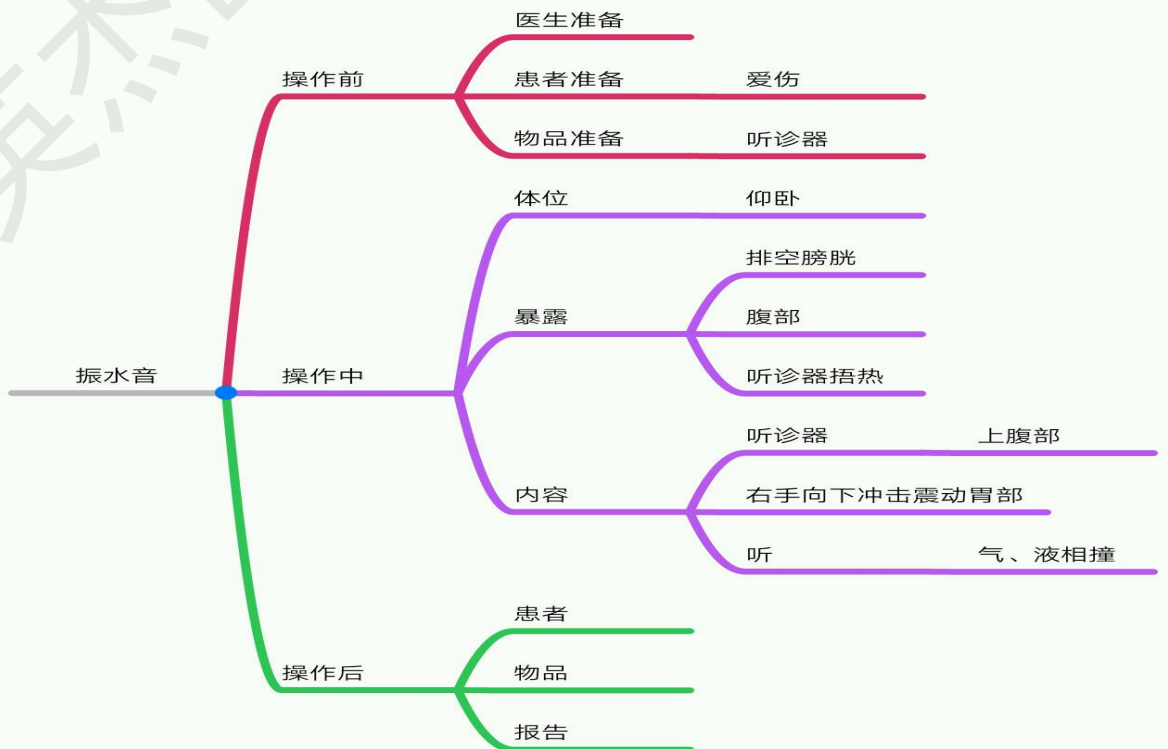
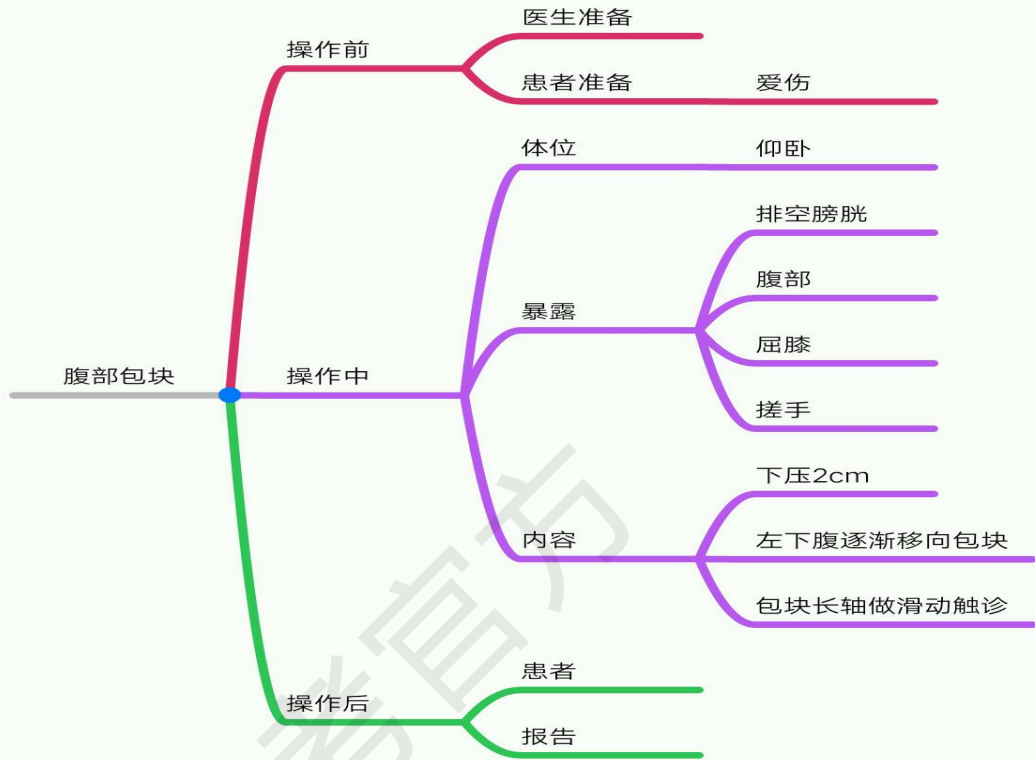


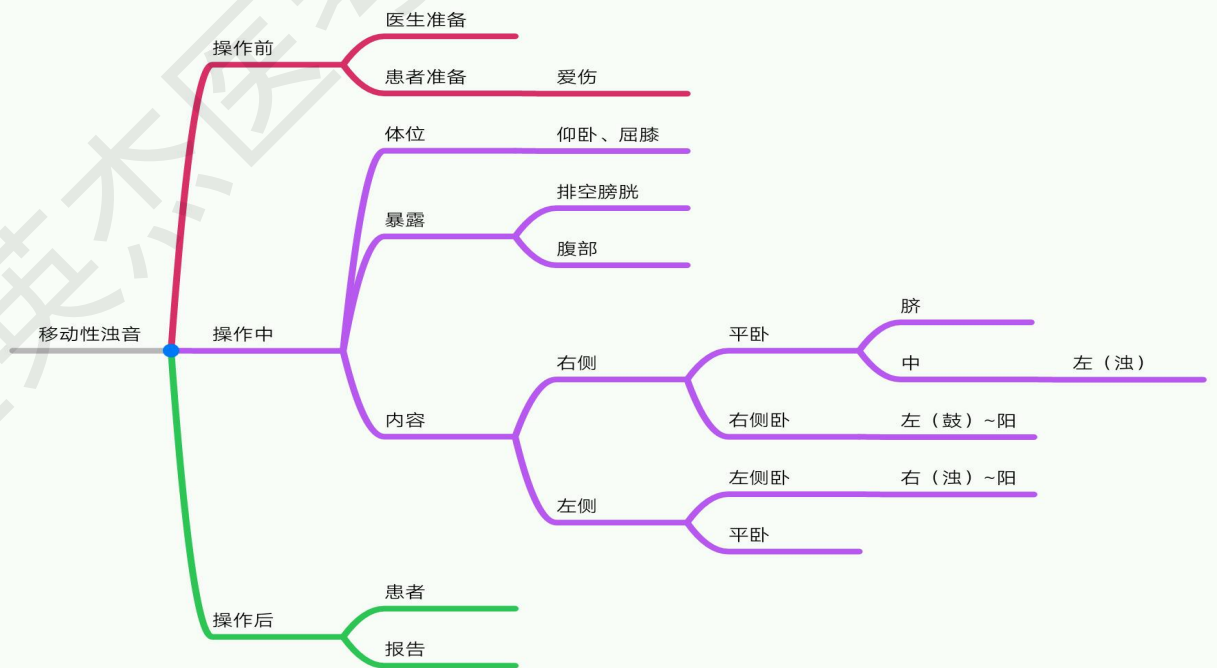
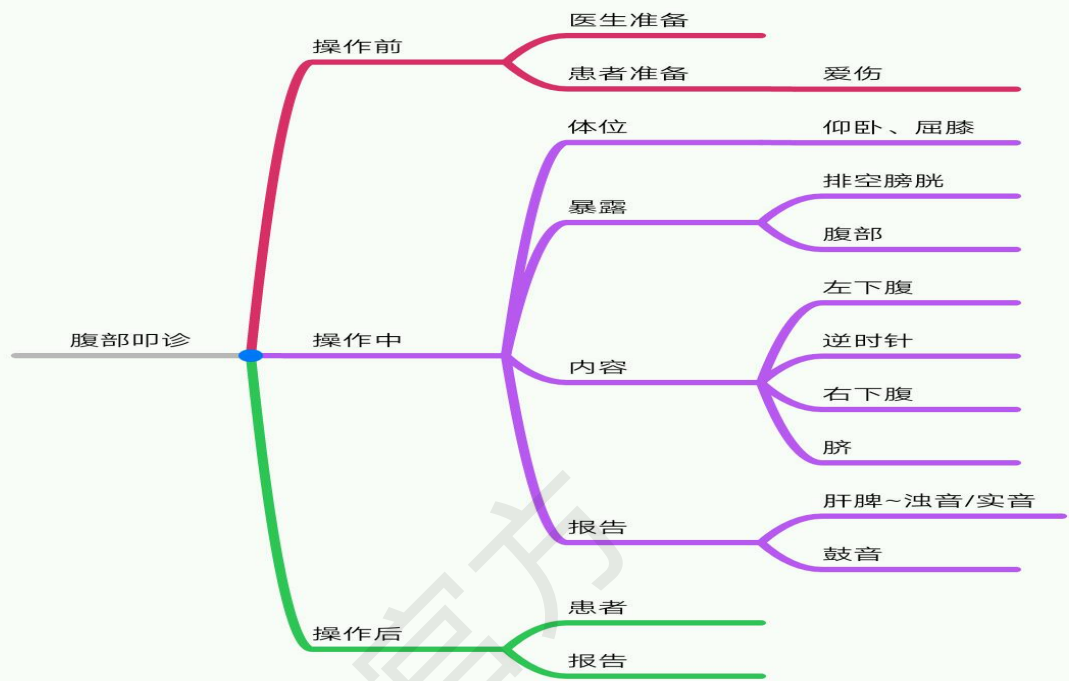


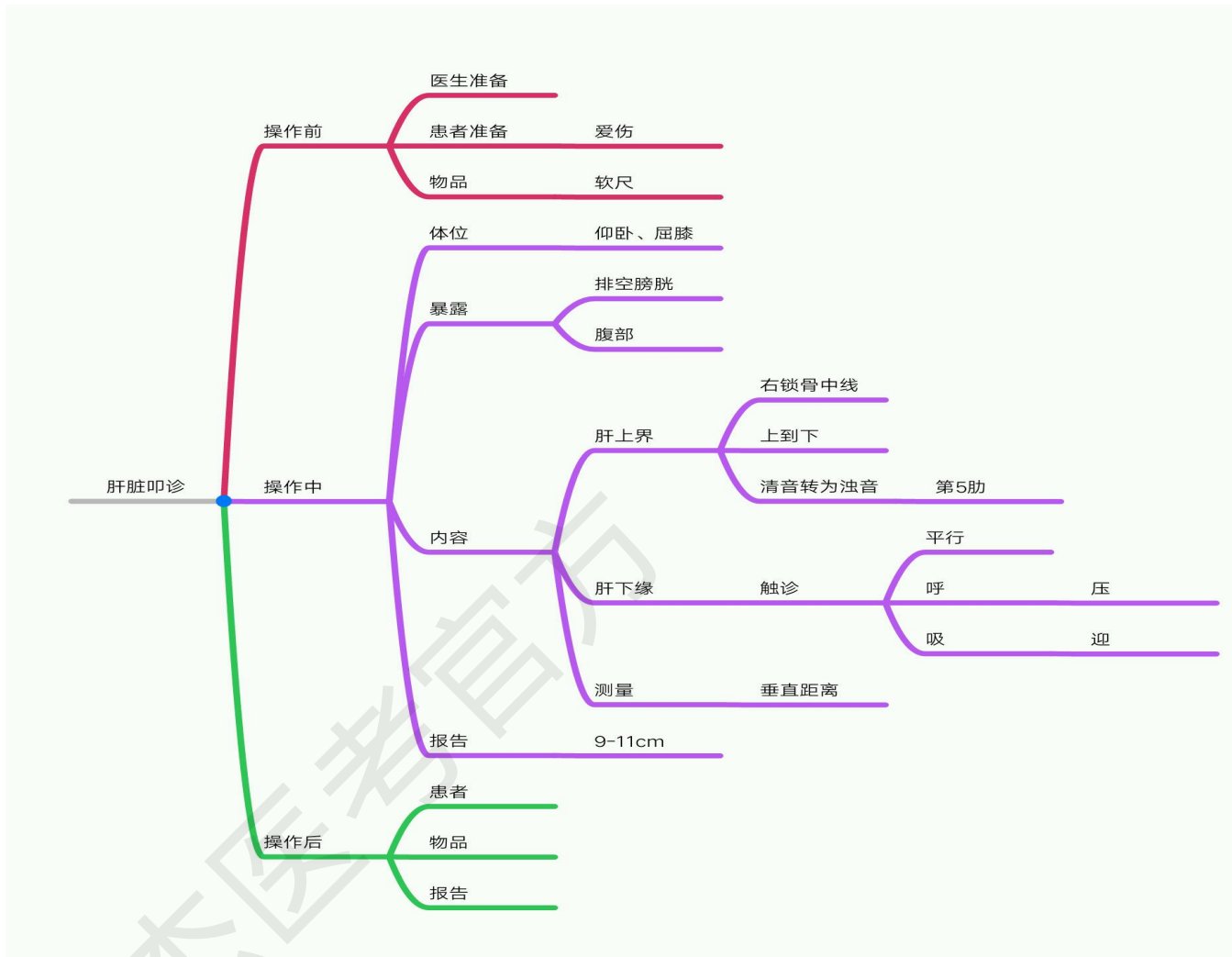


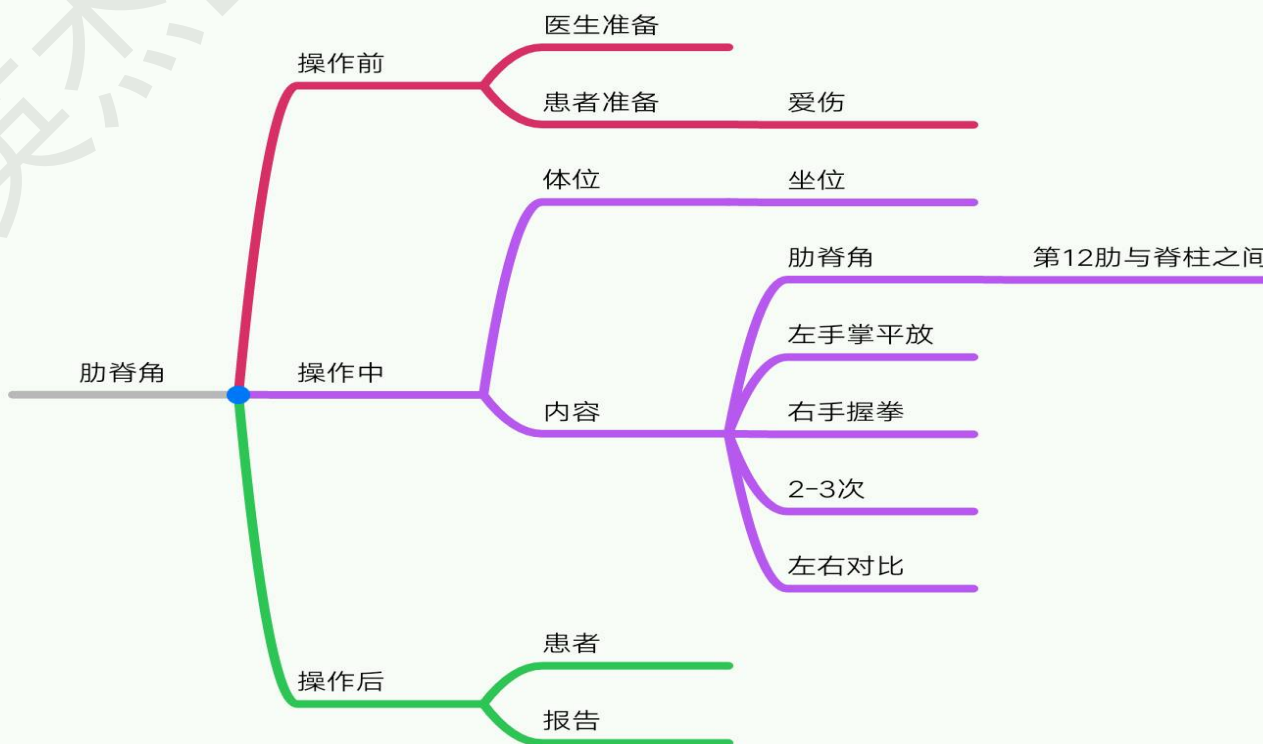
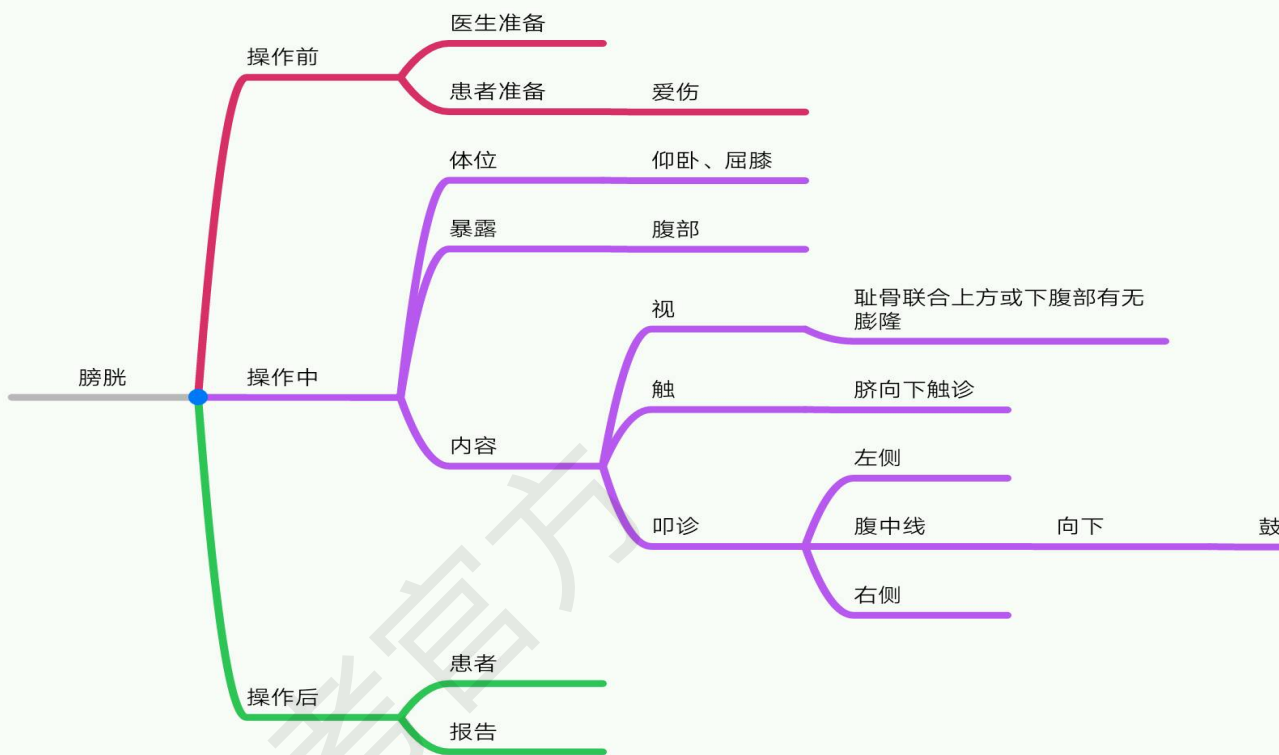


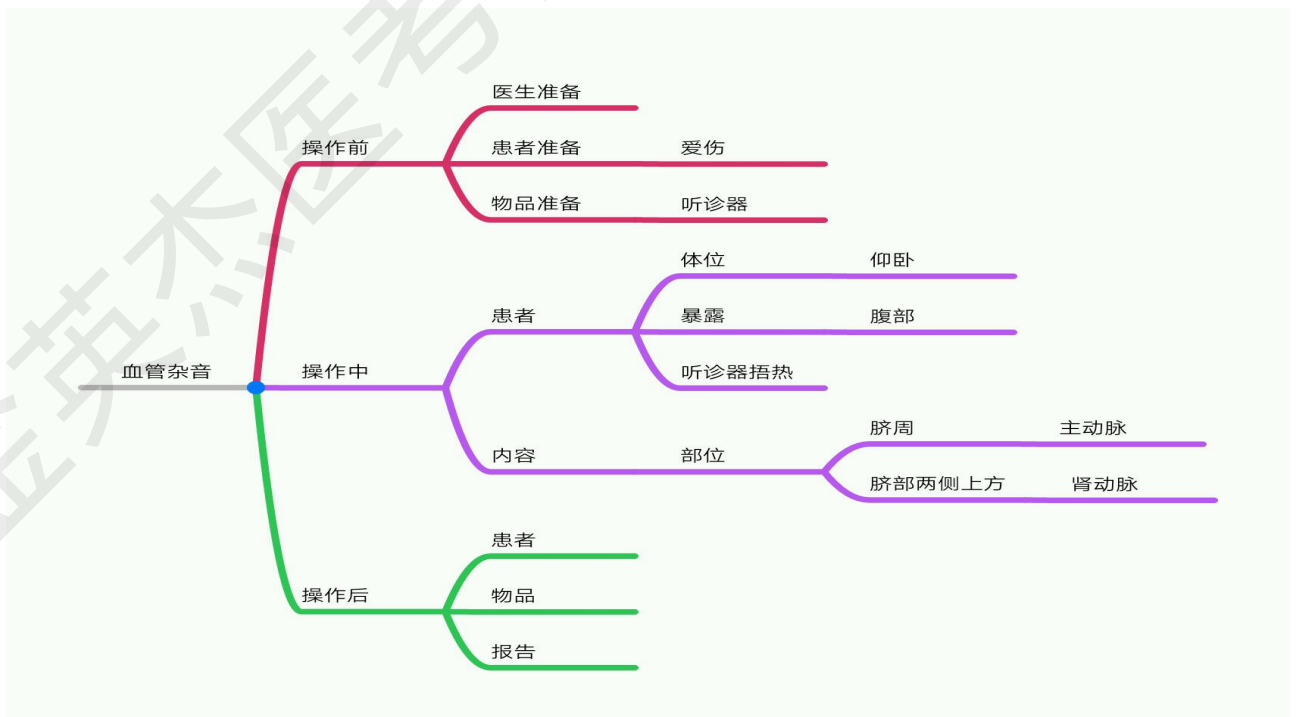
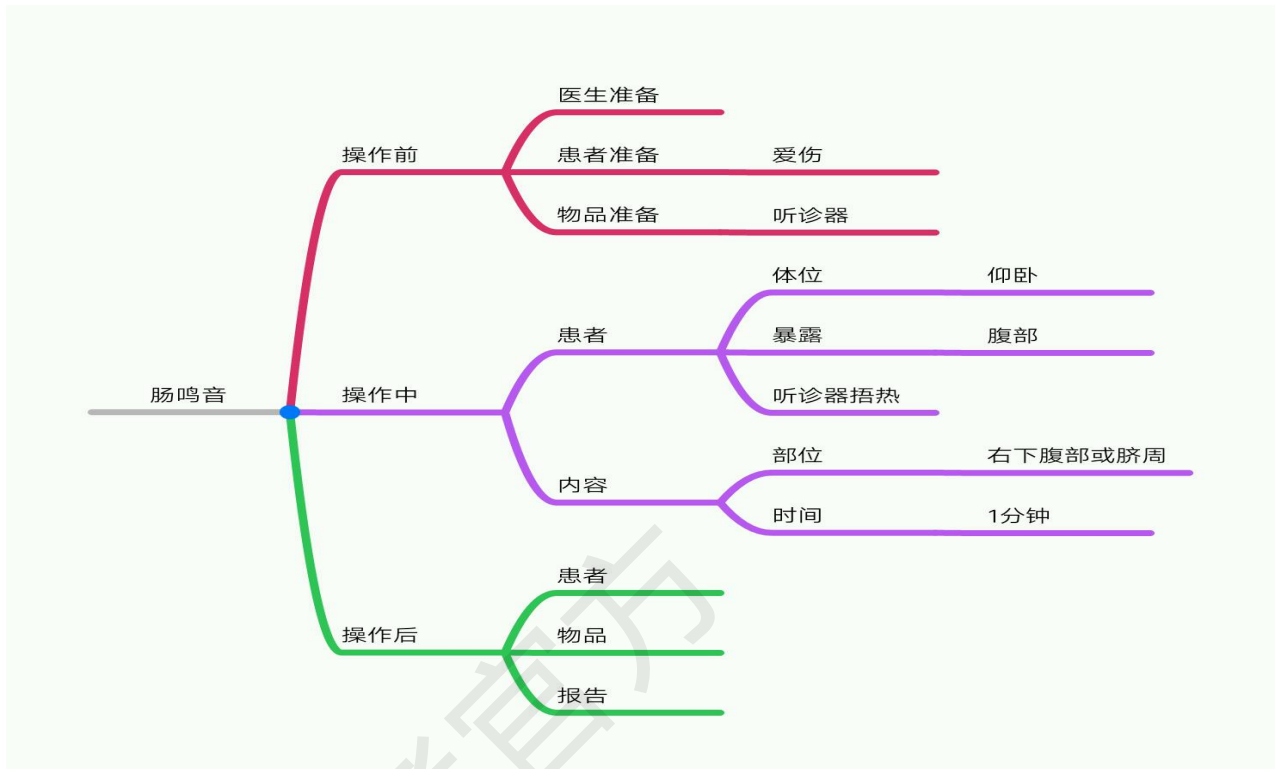


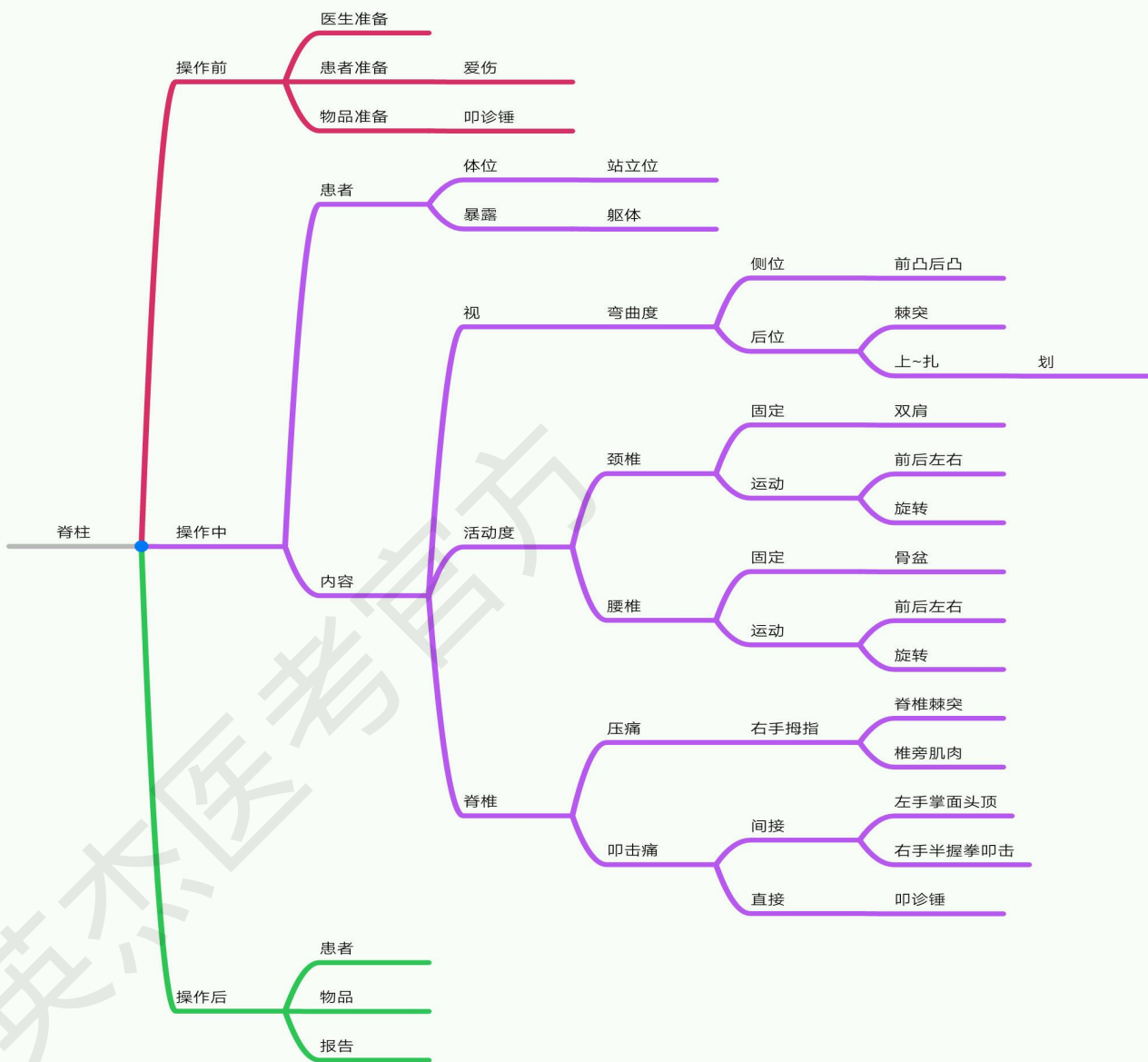


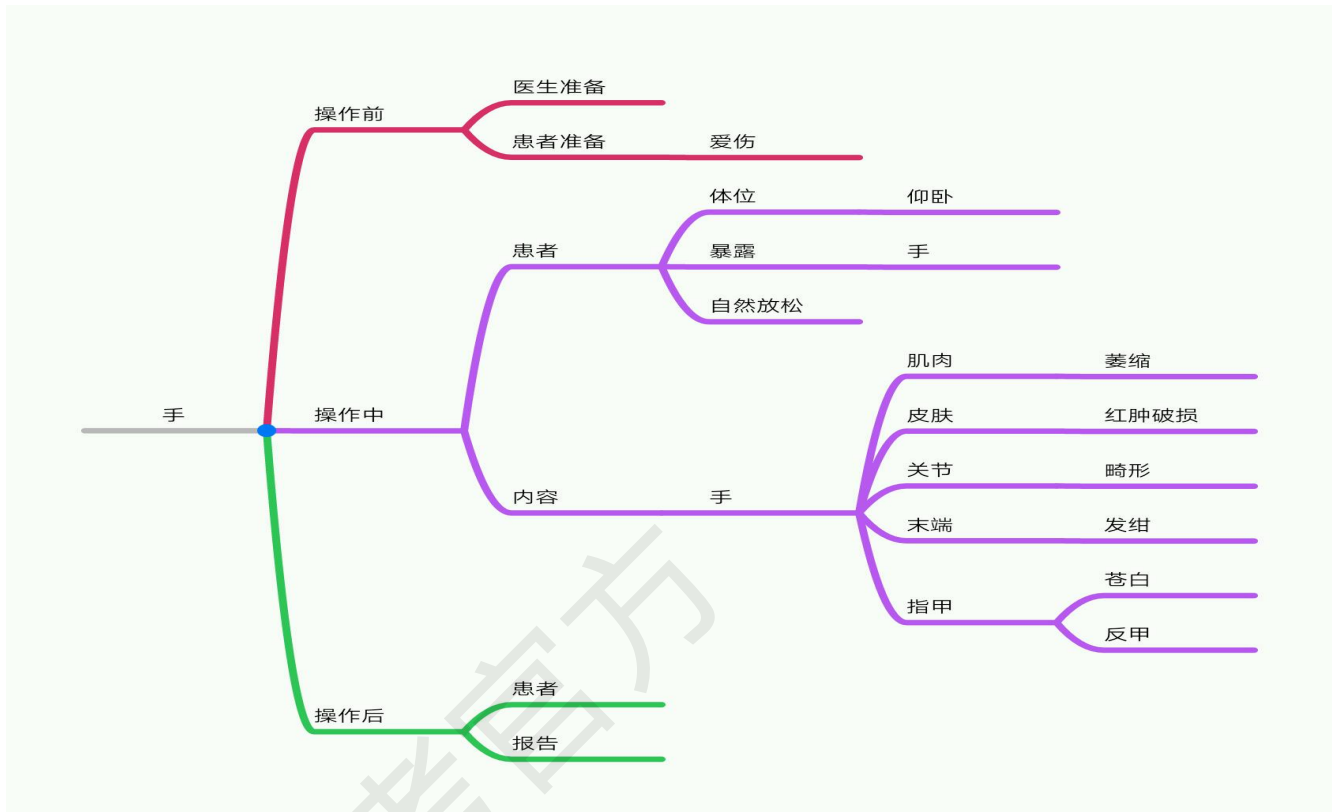




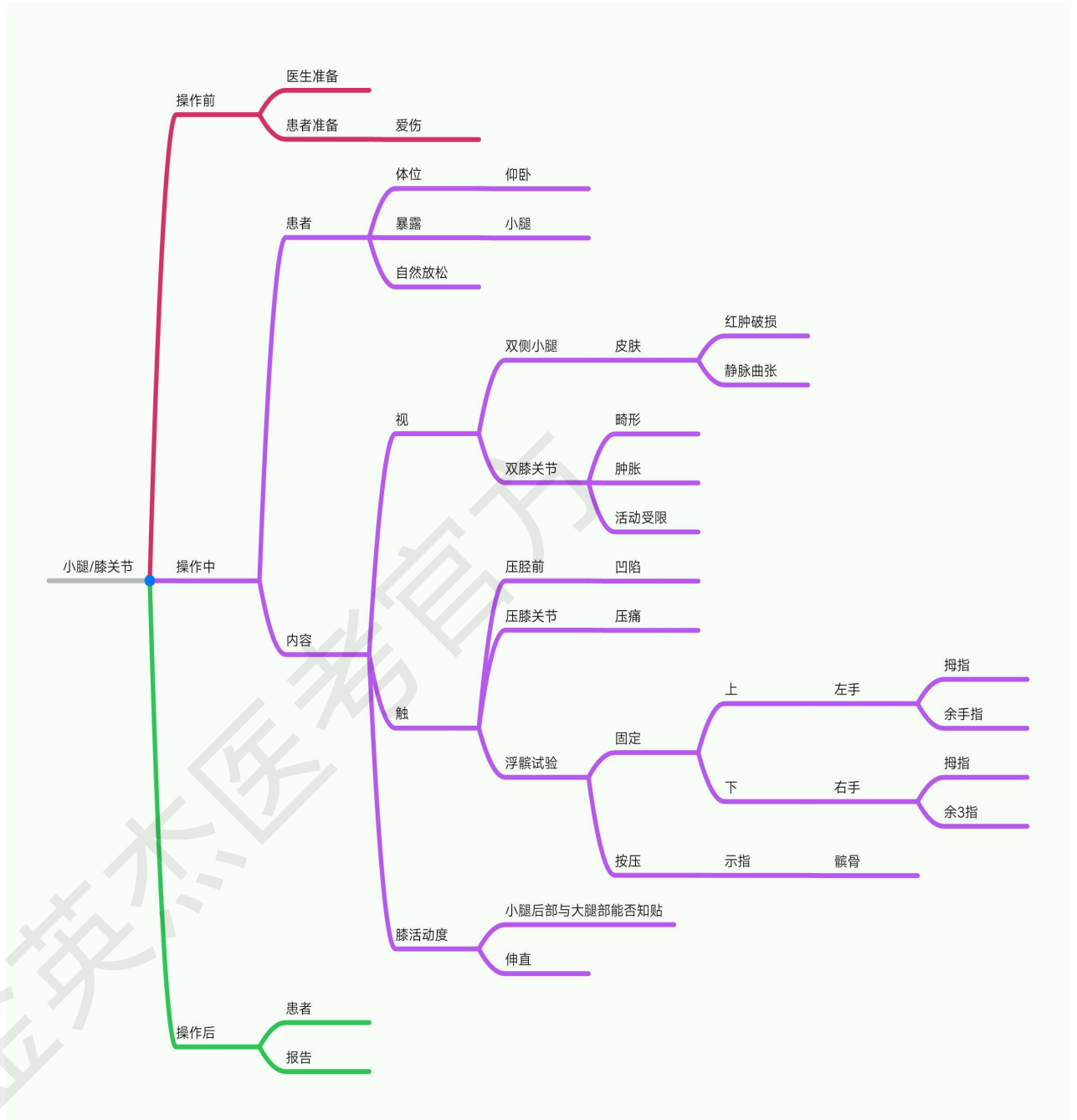


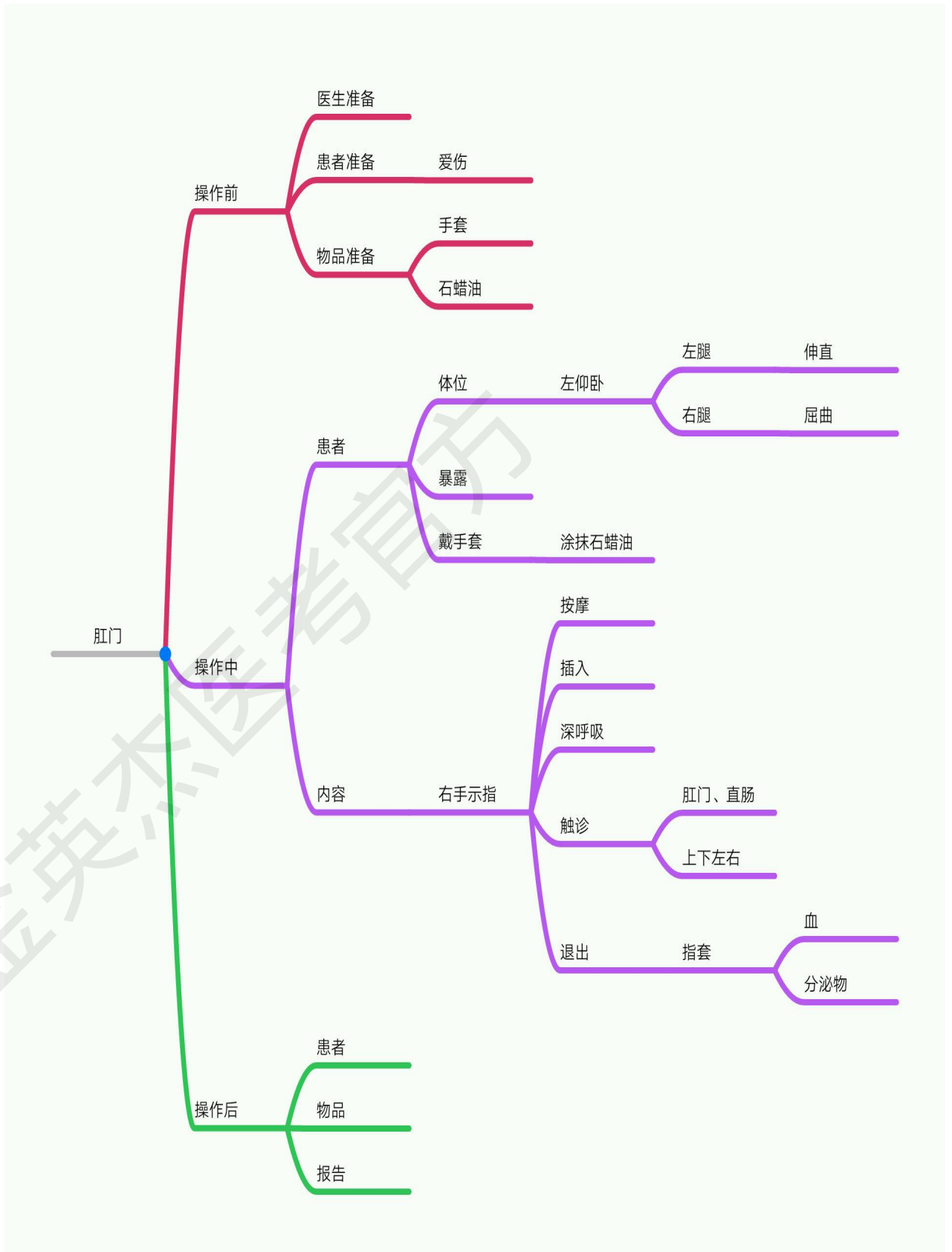


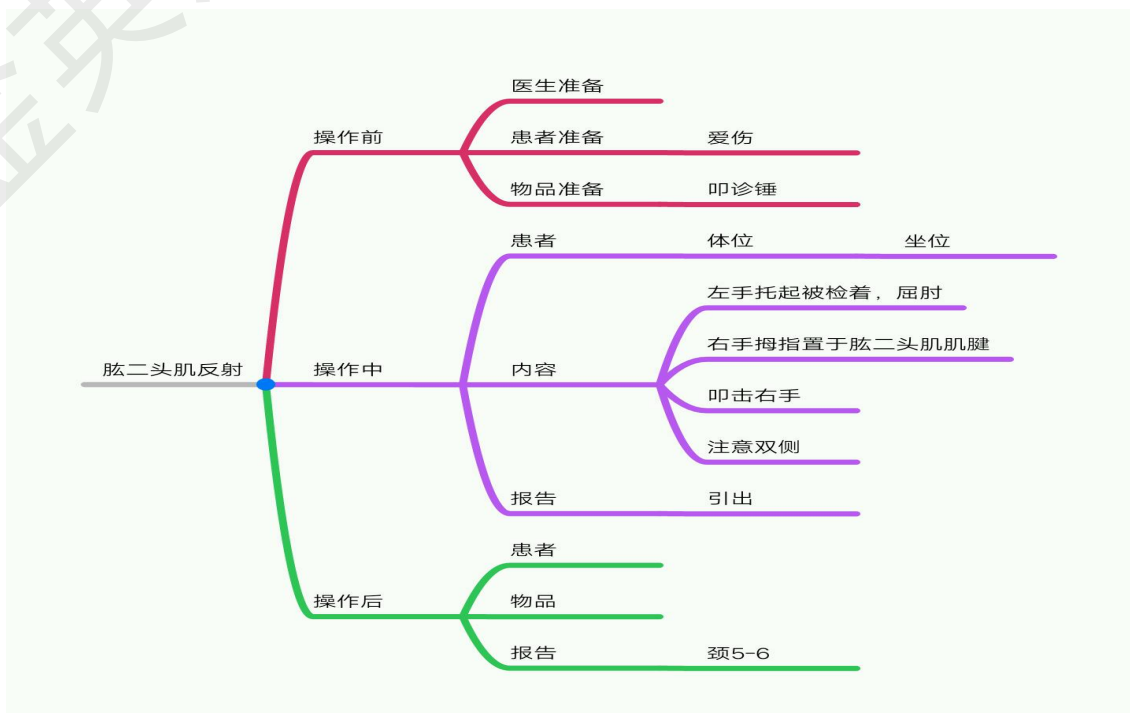
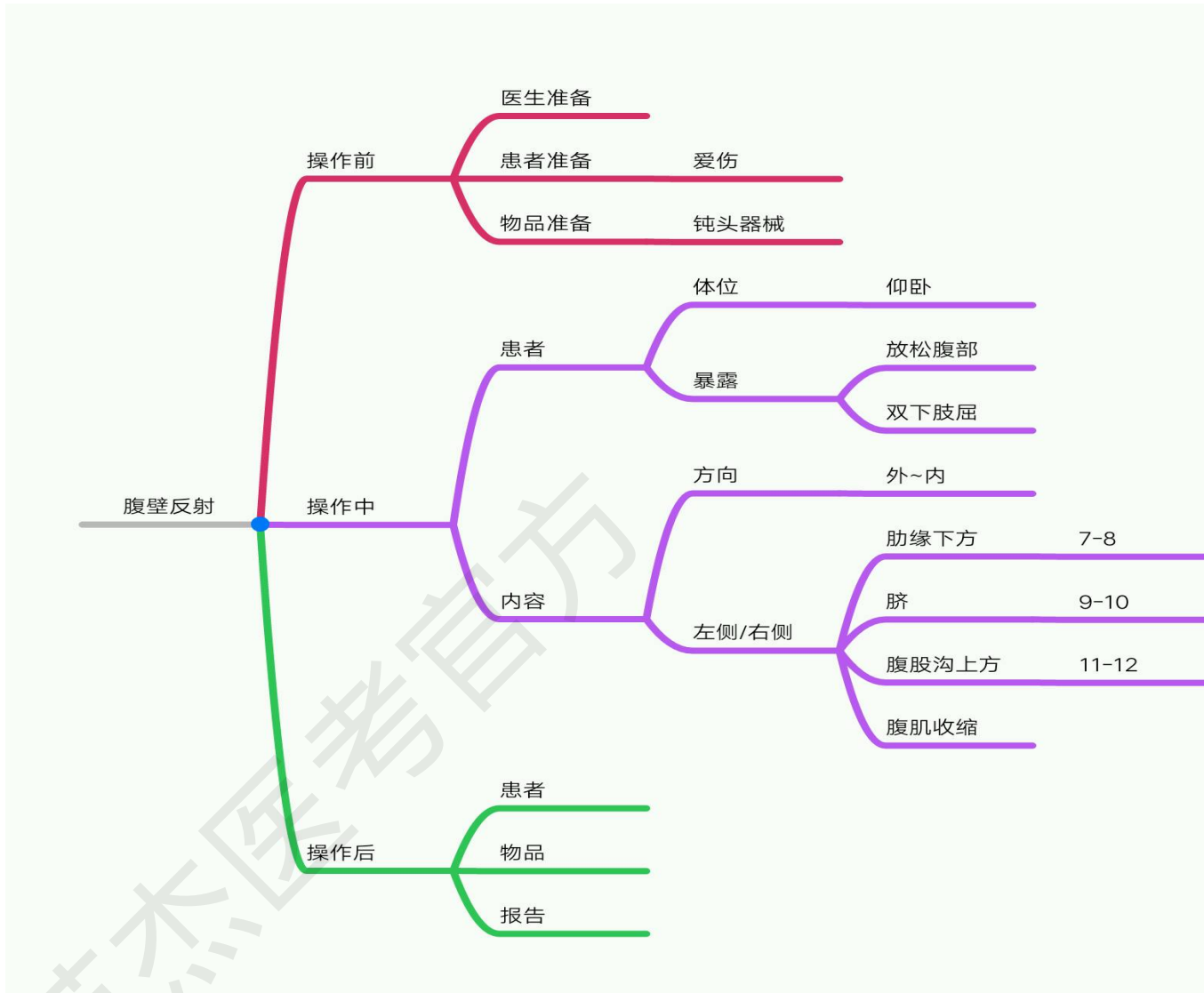


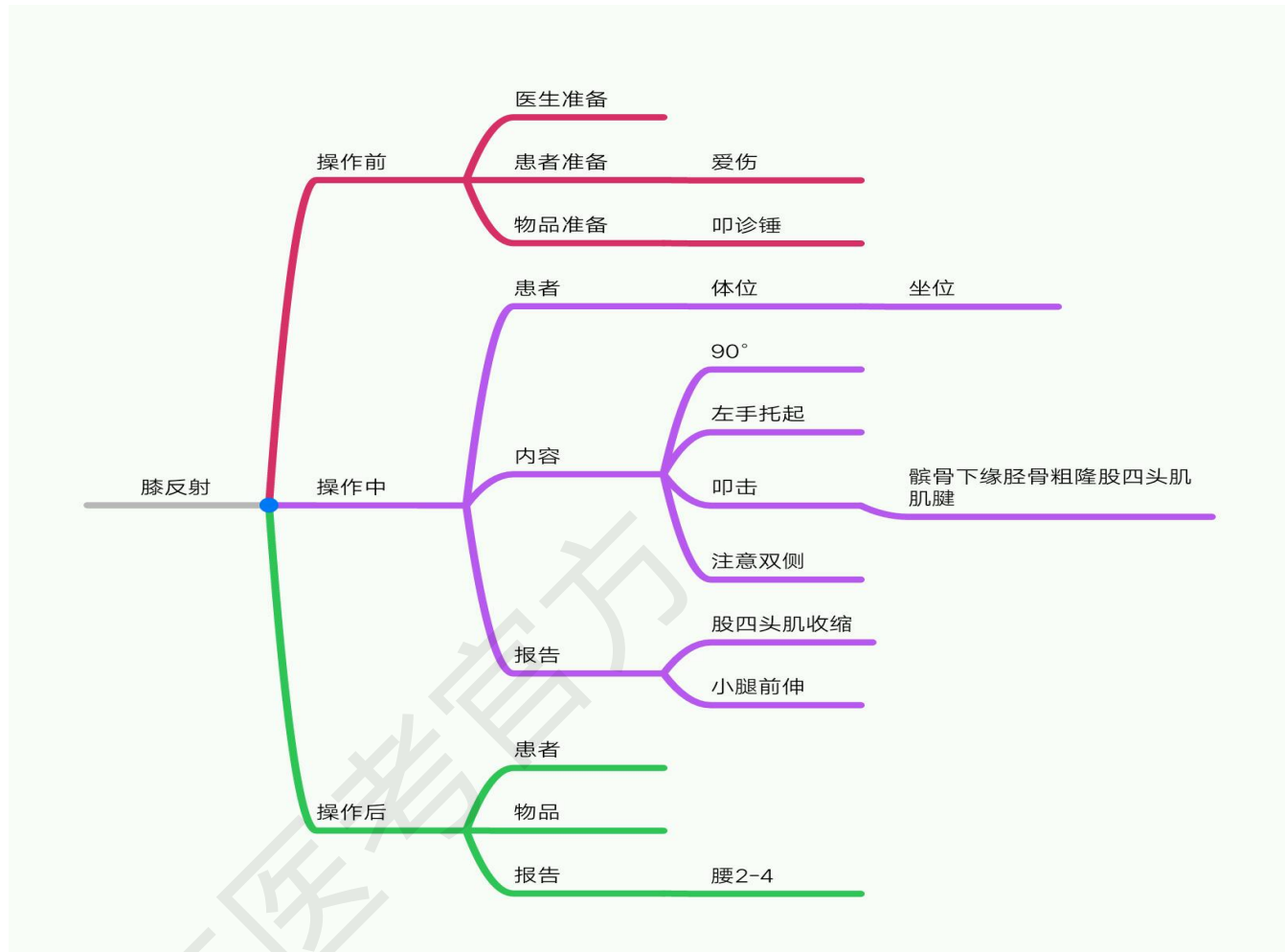


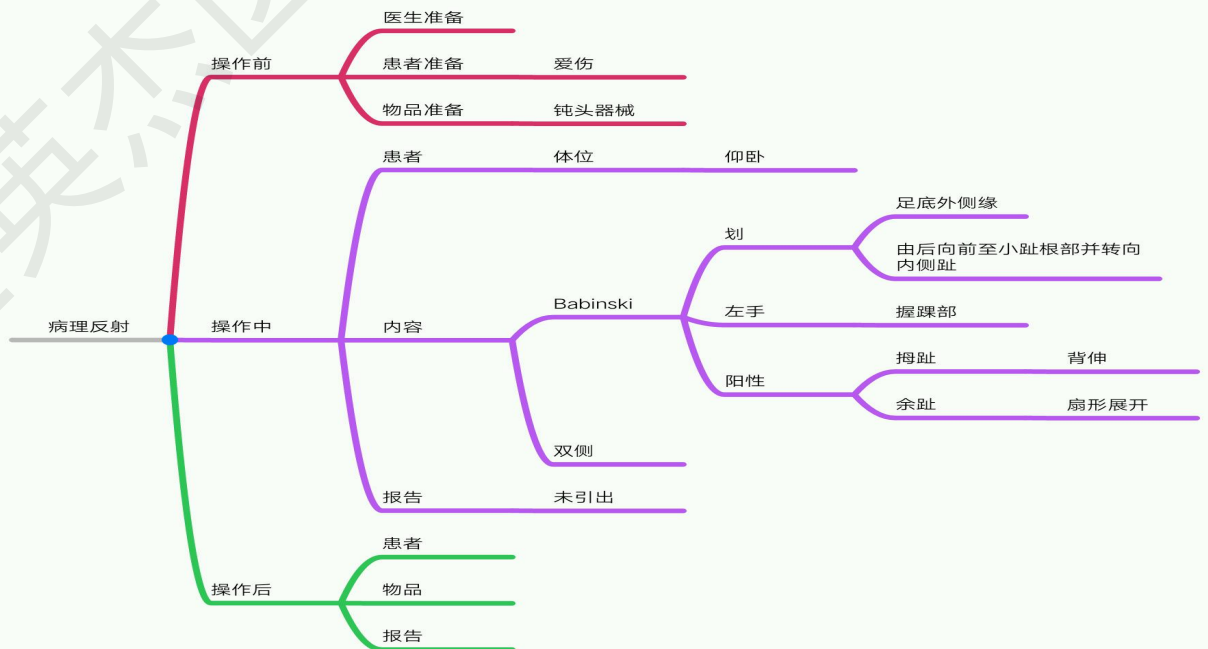
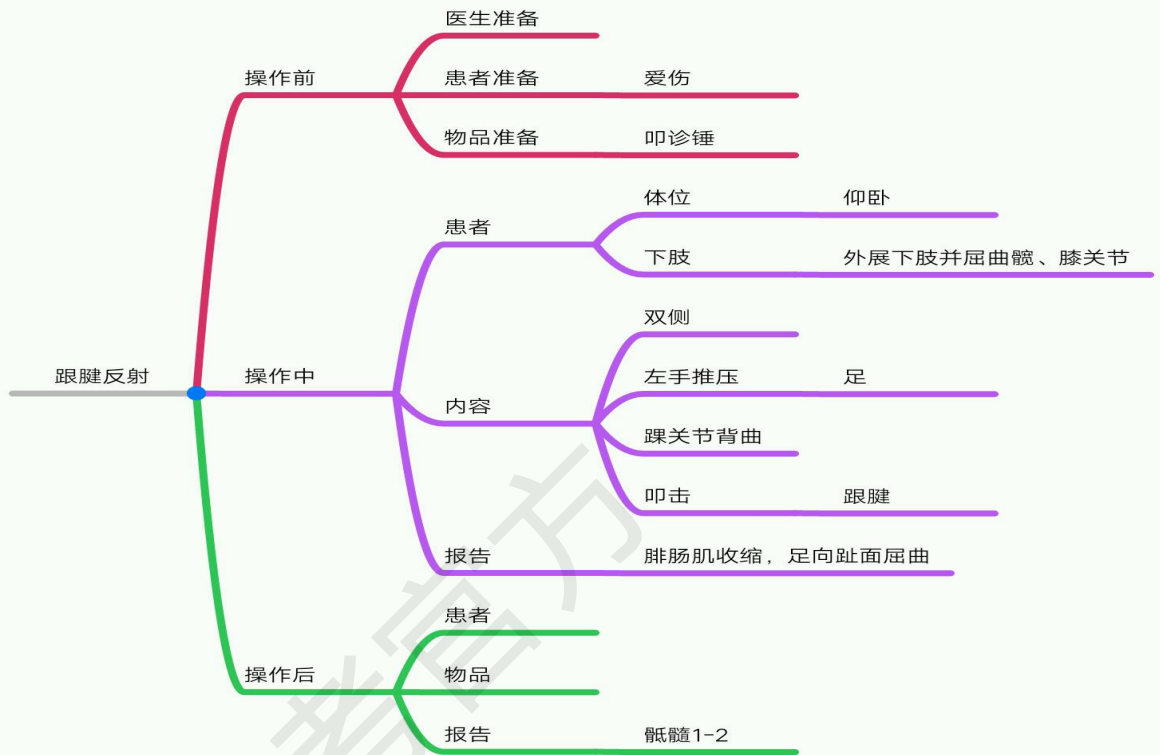
金英杰医考官方











巴宾划足底。查多划足背，奥本海姆滑下来，戈登一下腓肠肌

