

口腔执业（助理）医师资格考试

口腔全攻略图谱



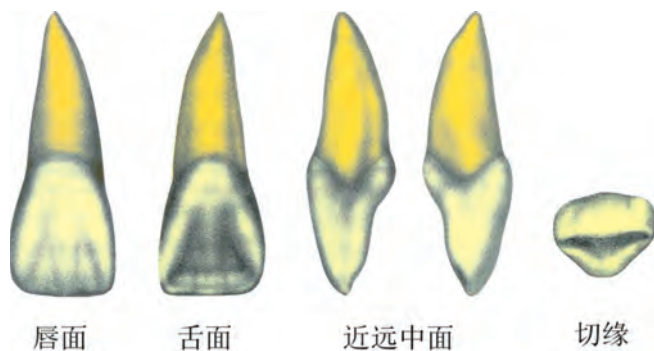
金英杰教育医考研究院

金英杰国家医学考试中心 编

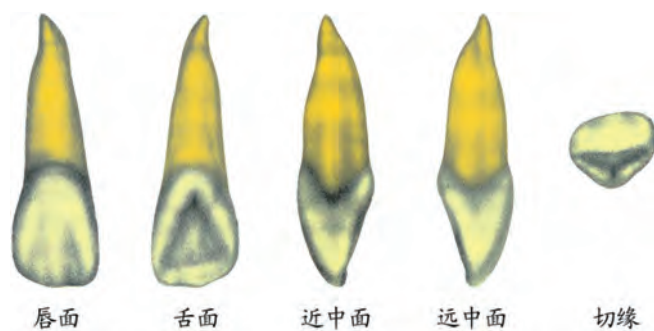
目 录

口腔解剖生理学.....	001
牙体牙髓病学、儿童口腔医学.....	026
牙周病学.....	034
口腔黏膜病学.....	041
口腔颌面外科学.....	048
口腔修复学.....	062
口腔颌面影像诊断学.....	076

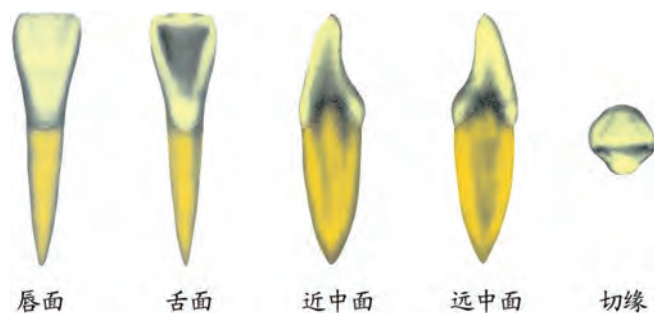
口腔解剖生理学



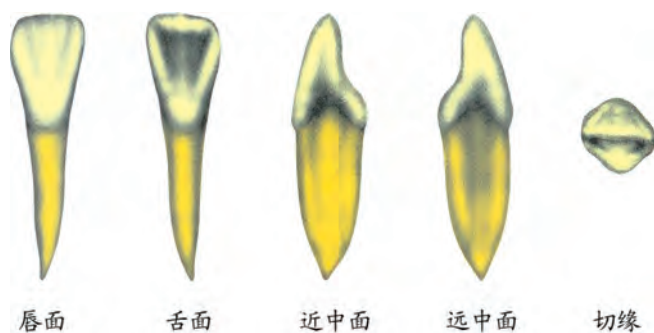
上颌中切牙



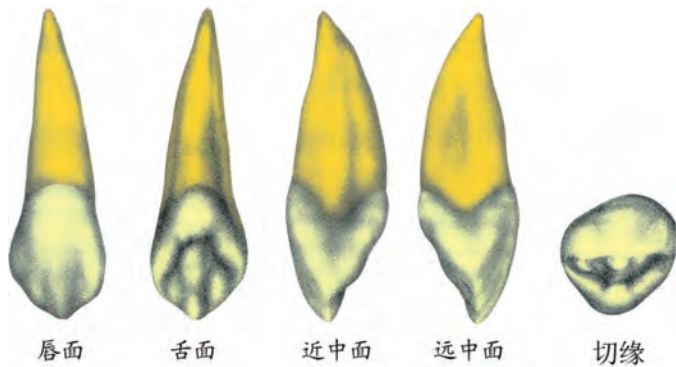
上颌侧切牙



下颌中切牙




下颌侧切牙



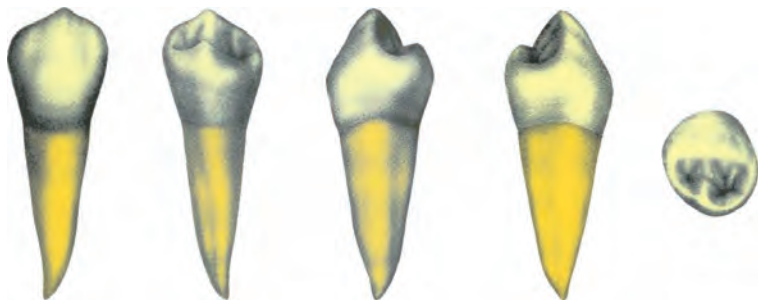
唇面 舌面 近中面 远中面 切缘

上颌尖牙



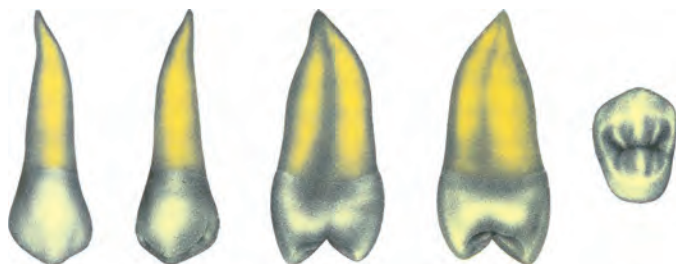
唇面 舌面 近中面 远中面 切缘

下颌尖牙



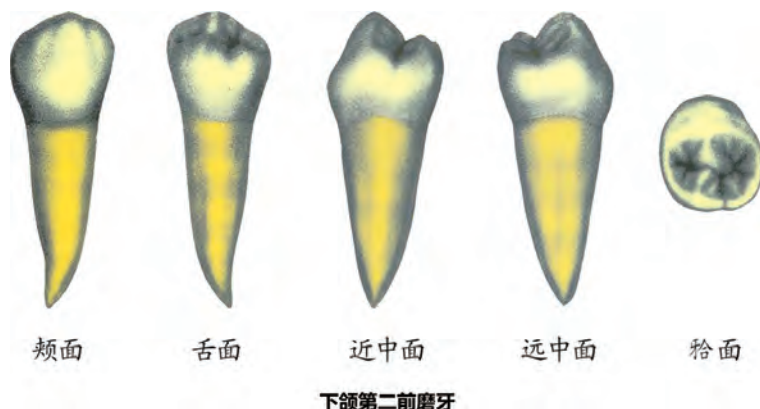
颊面 舌面 近中面 远中面 舌面

下颌第一前磨牙

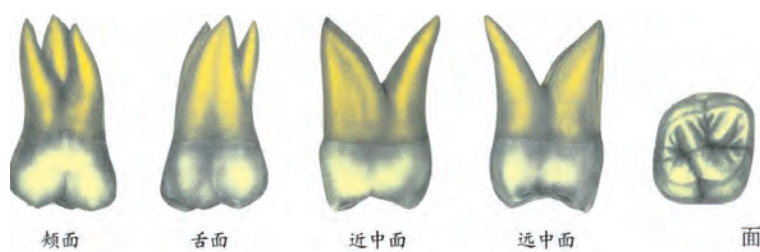


颊面 舌面 近中面 远中面 舌面

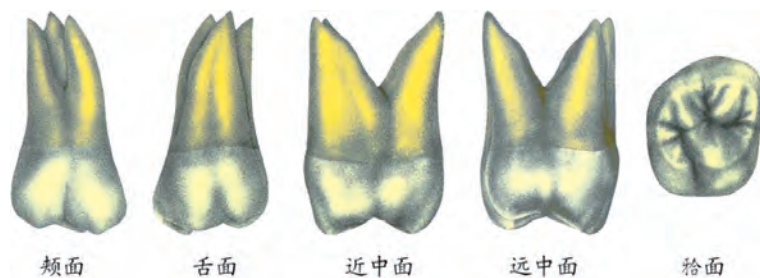
上颌第二前磨牙



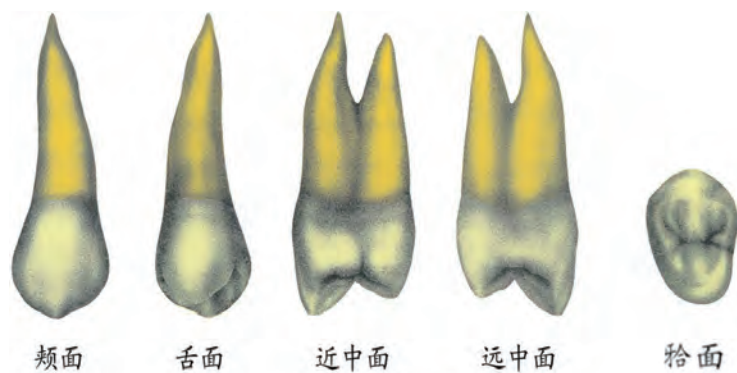
下颌第二前磨牙



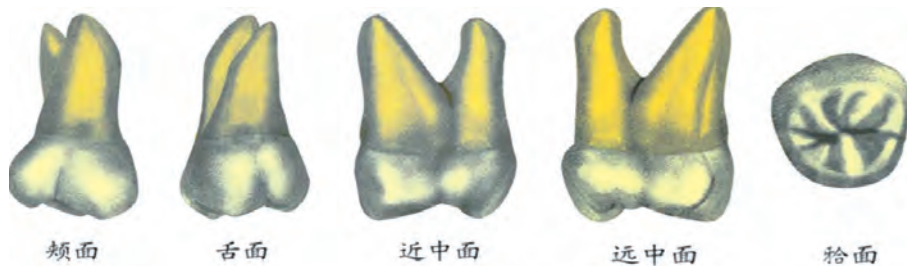
上颌第一磨牙



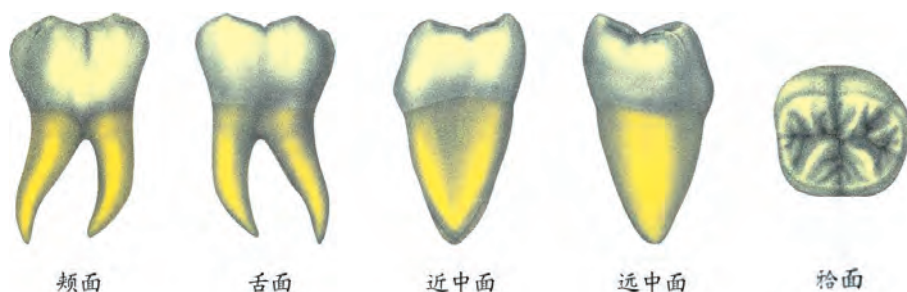
上颌第二磨牙



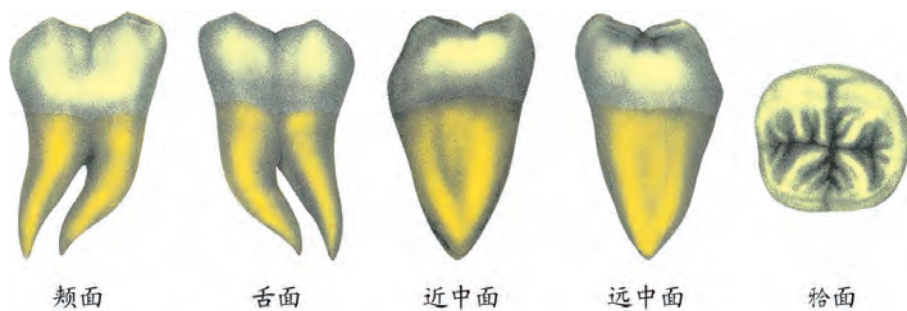上颌第一前磨牙



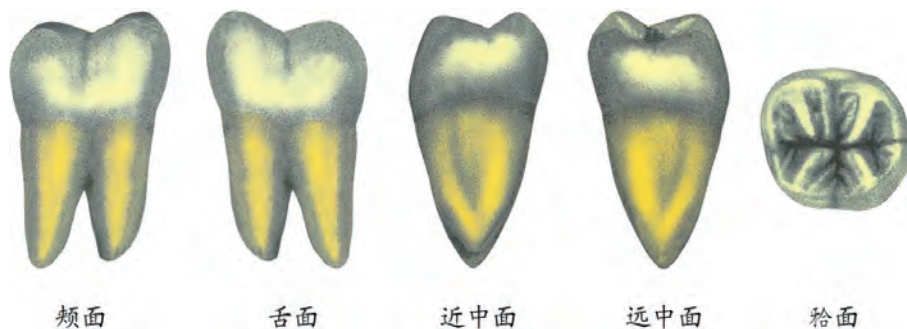
上颌第三磨牙



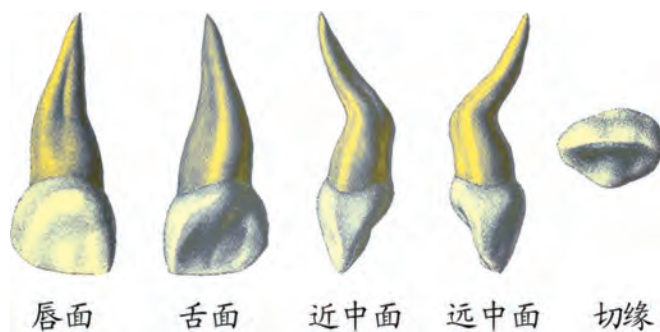
下颌第一磨牙



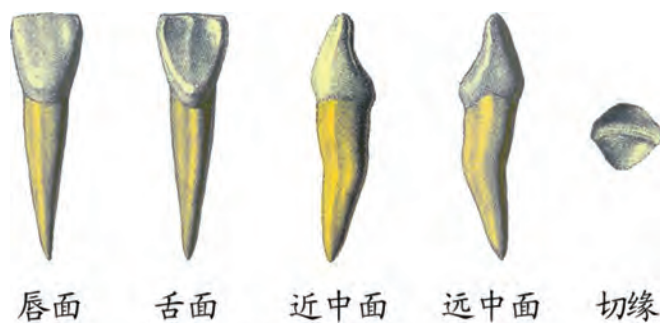
下颌第二磨牙



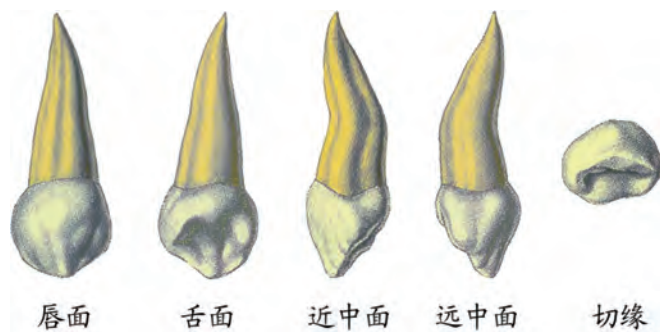
下颌第三磨牙



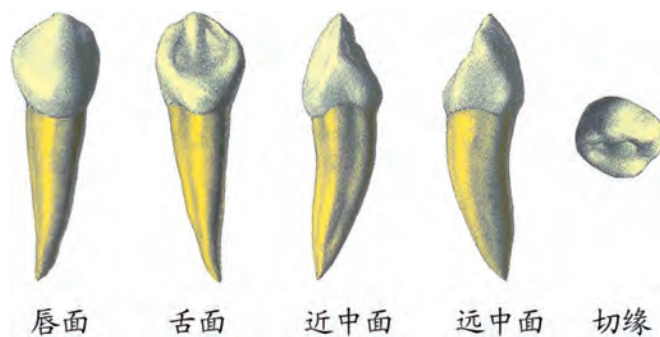上颌乳中切牙



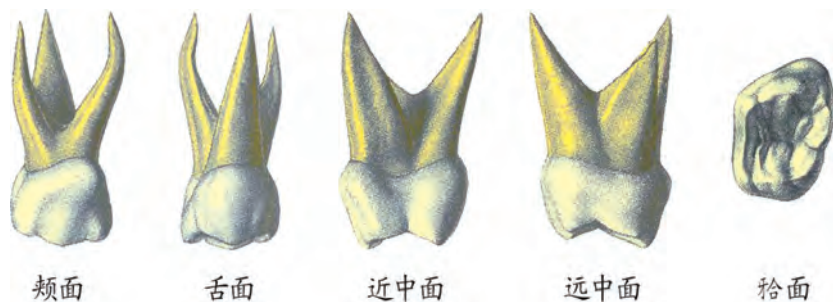
下颌乳中切牙



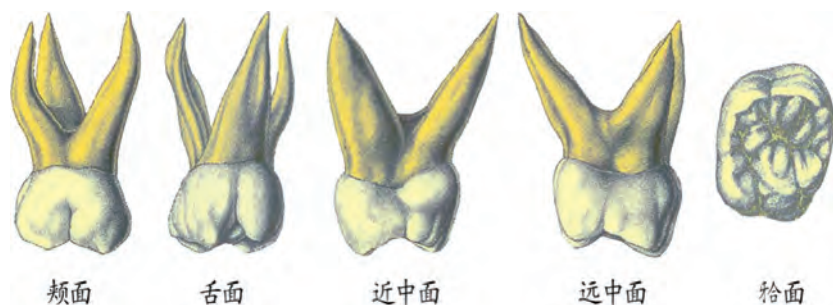
上颌乳尖牙



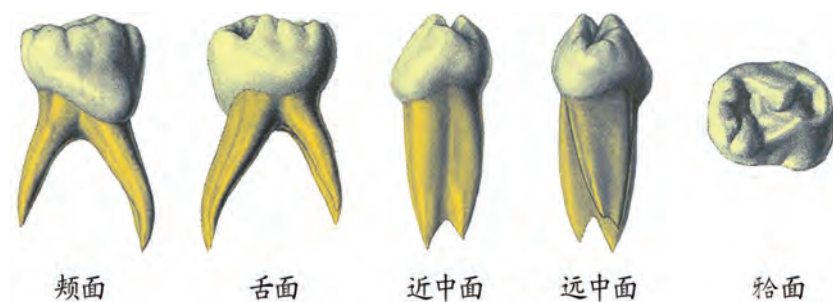下颌乳尖牙



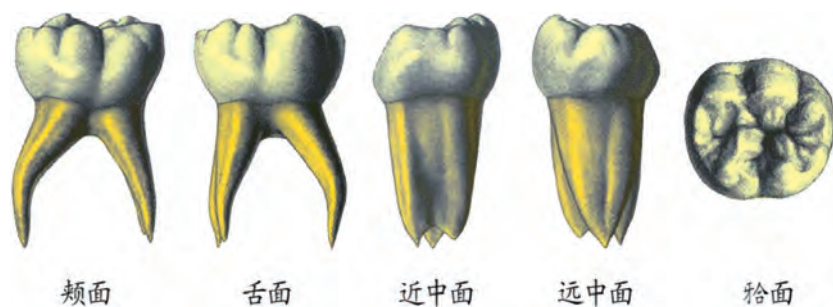上颌第一乳磨牙



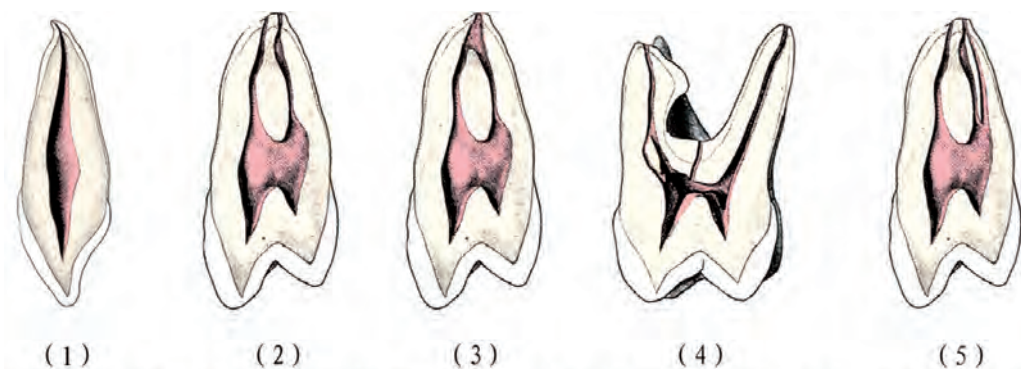
上颌第二乳磨牙



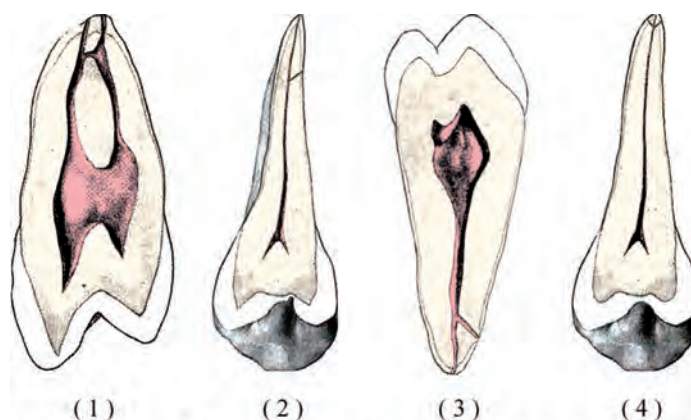
下颌第一乳磨牙



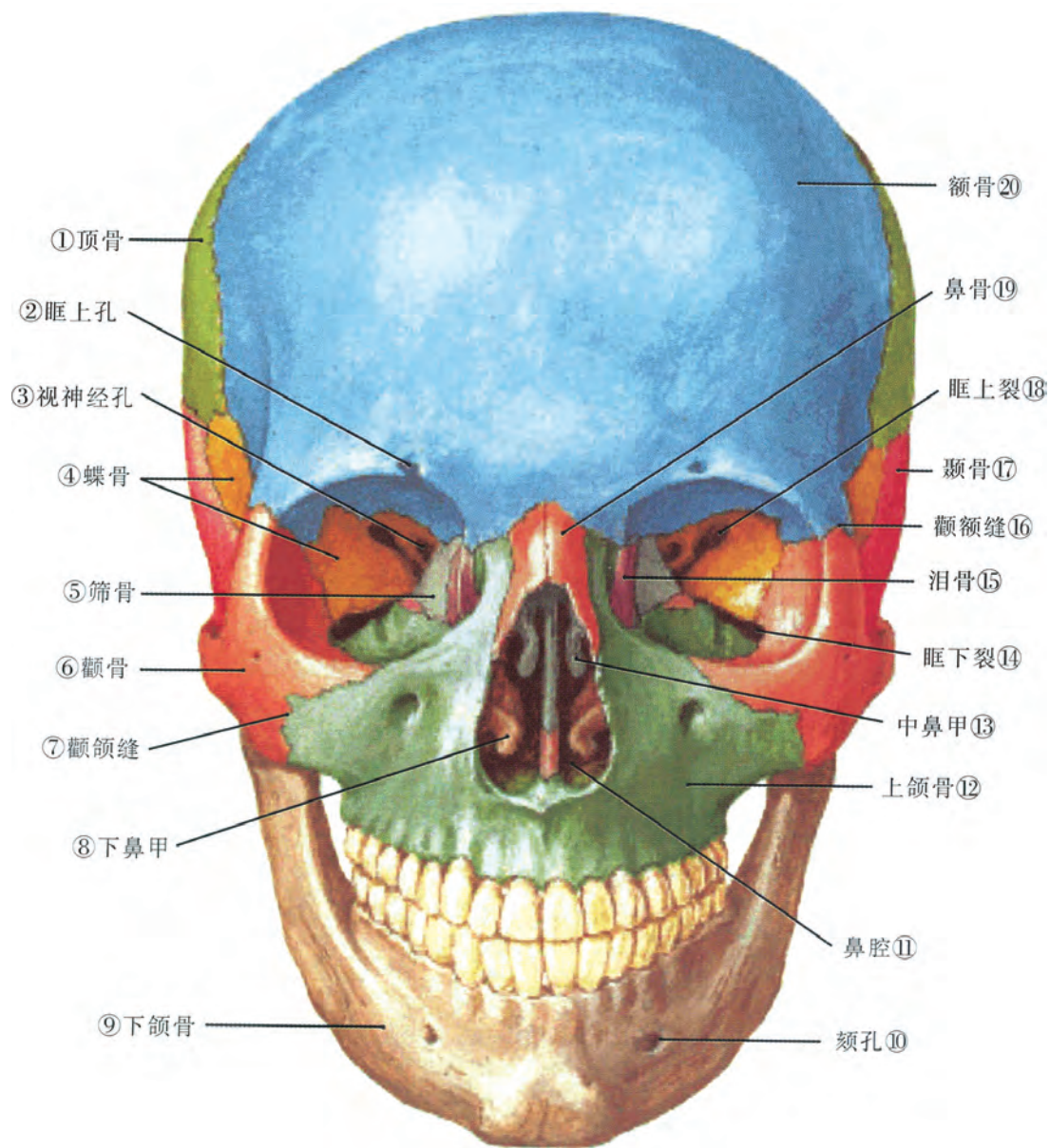
下颌第二乳磨牙



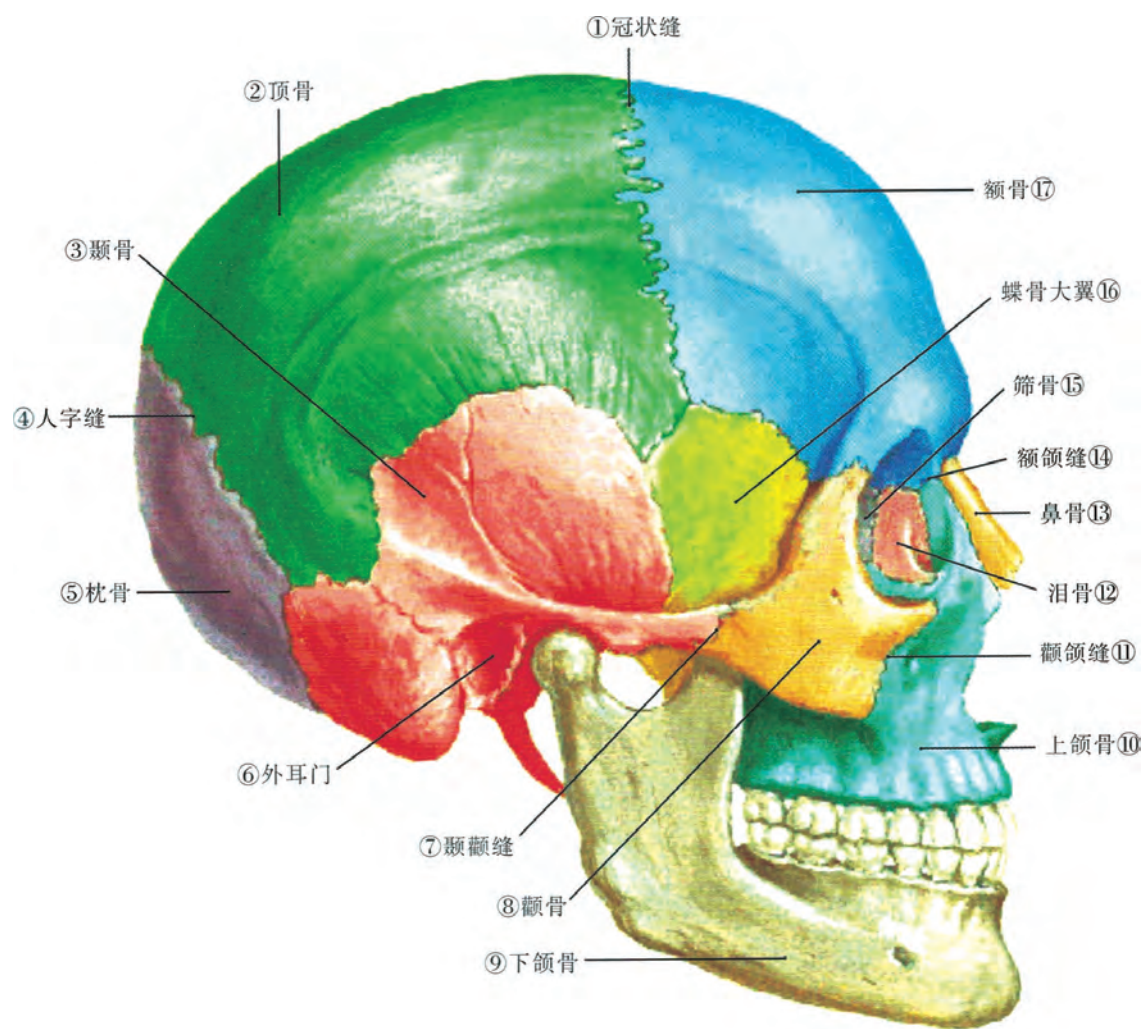
(1)单管型 (2)(3) 双管型 (4) 副根管及单双混合型 (5) 三管型



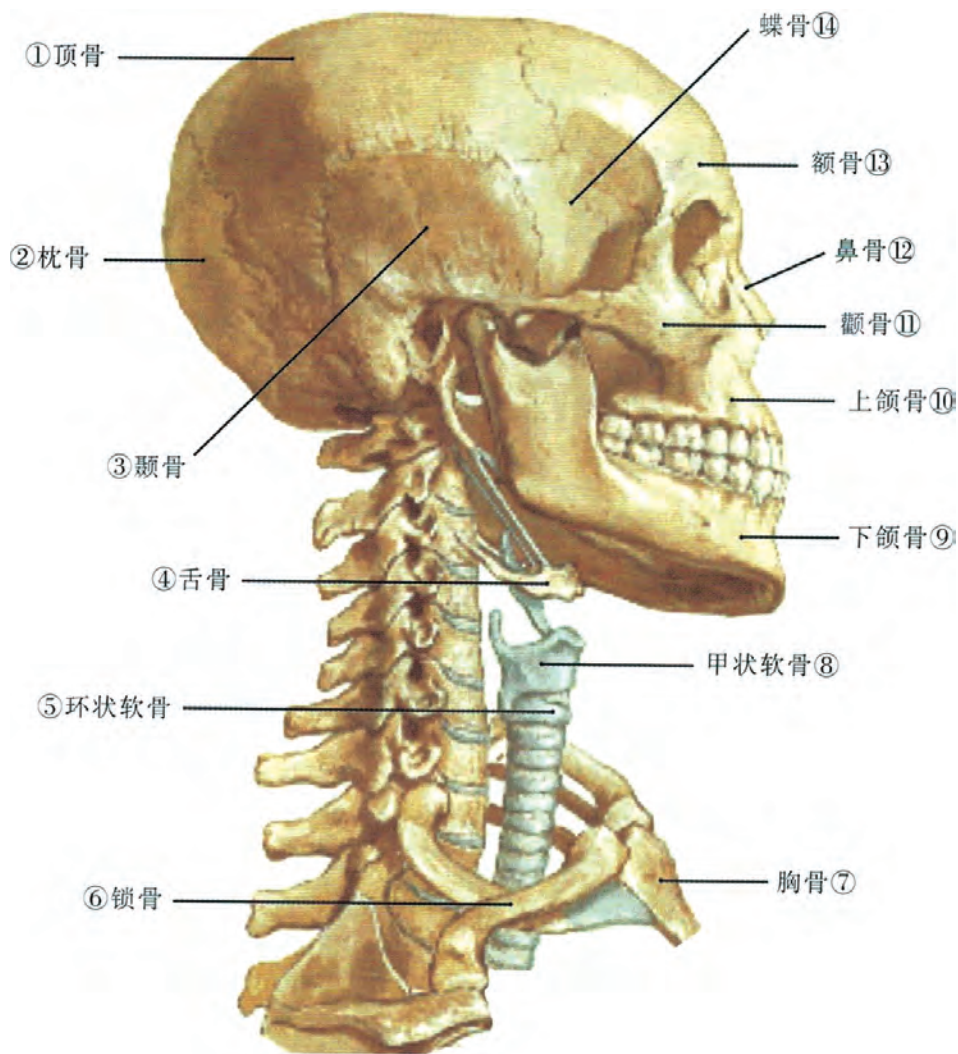
(1) 管间侧支 (2)(3) 根管侧支 (4) 根尖分歧



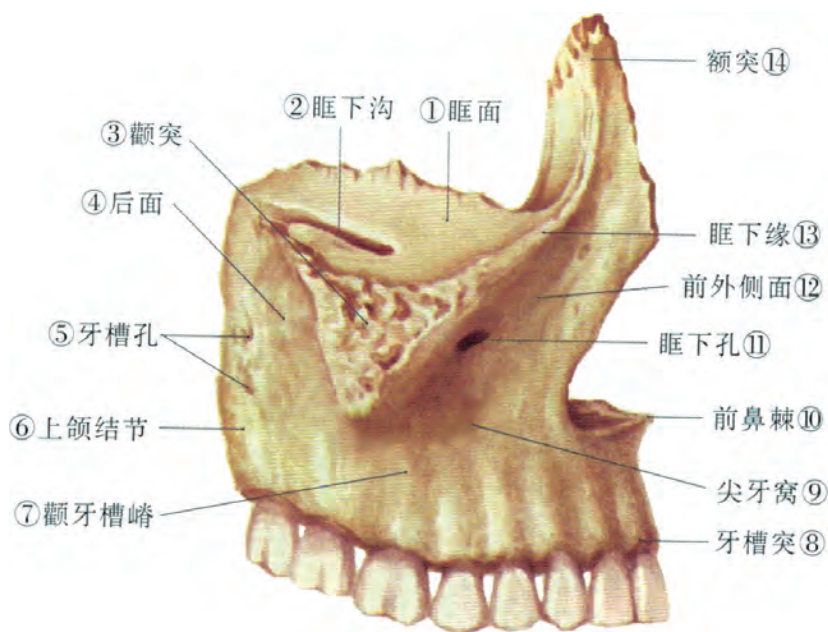
颅面骨骼前面观



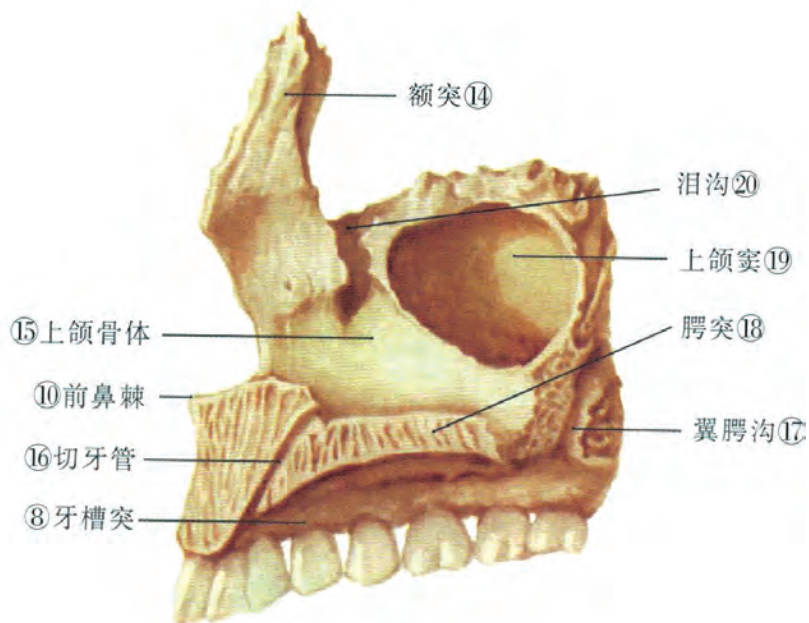
颅面骨骼外侧面观



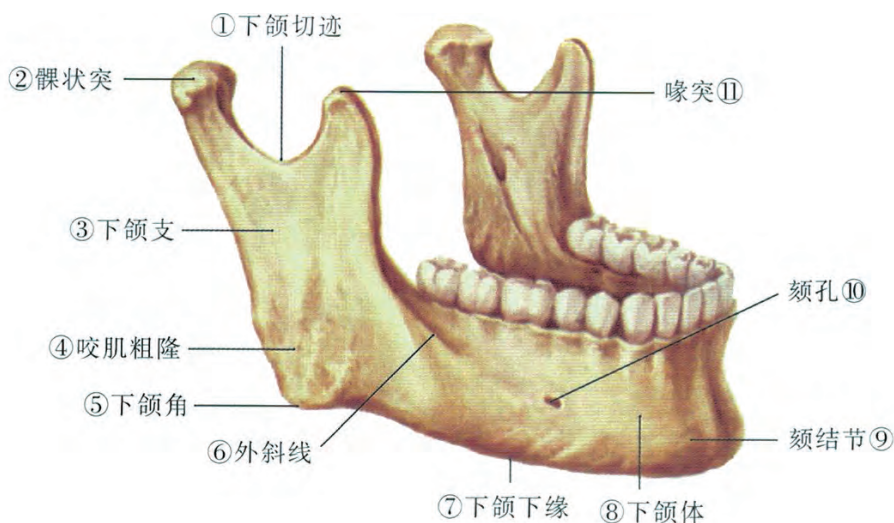
头颈部骨骼外侧面观



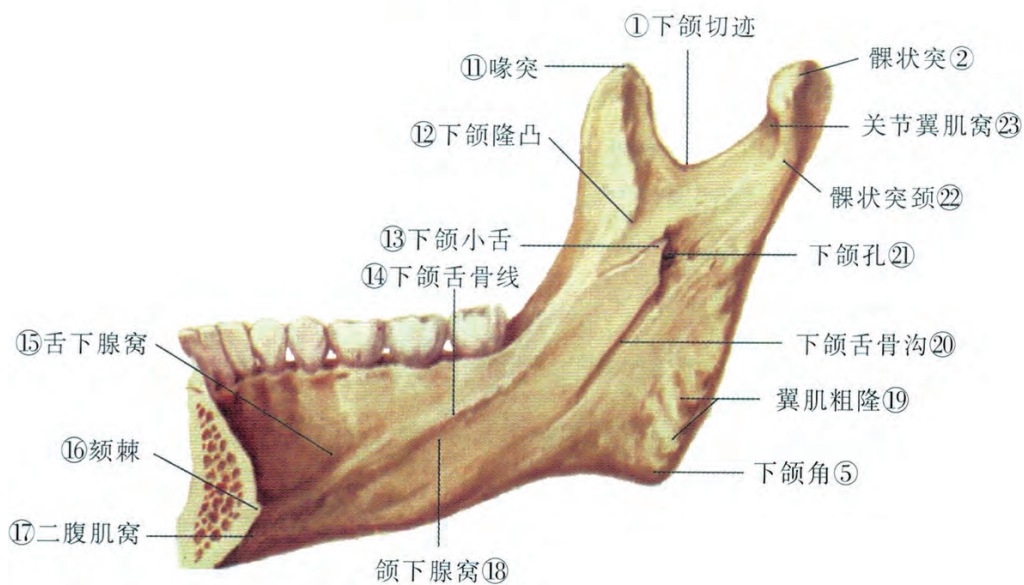
上颌骨外侧面观



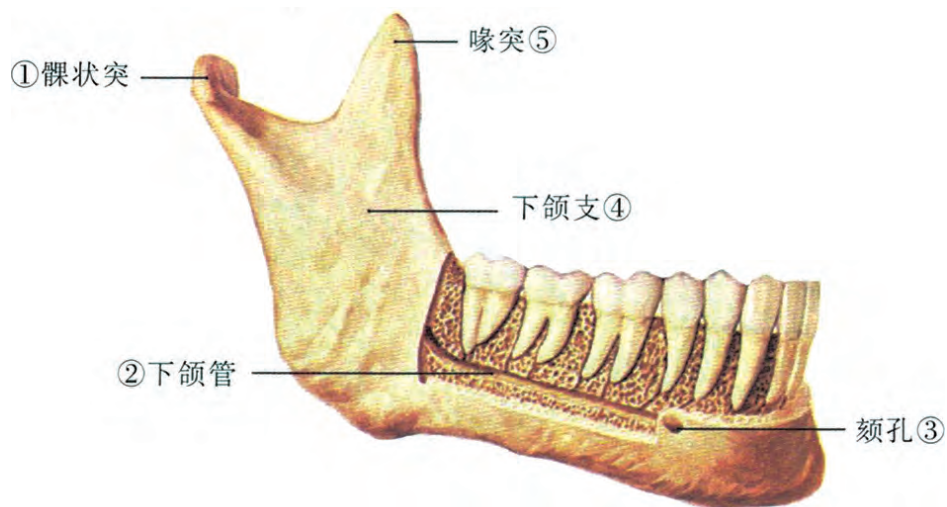
上颌骨内侧面观



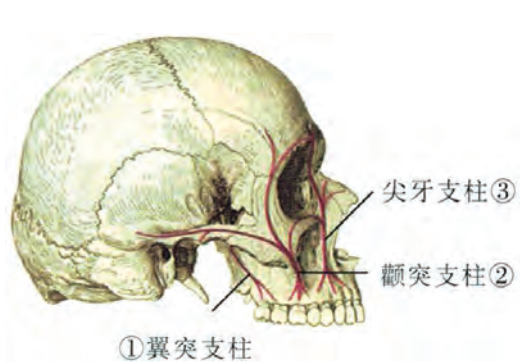
下颌骨外侧面观



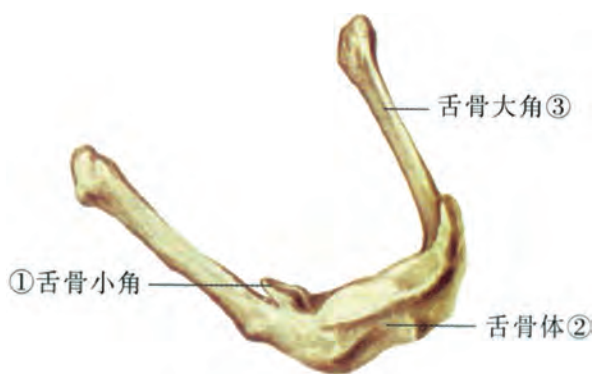
下颌骨内侧面观



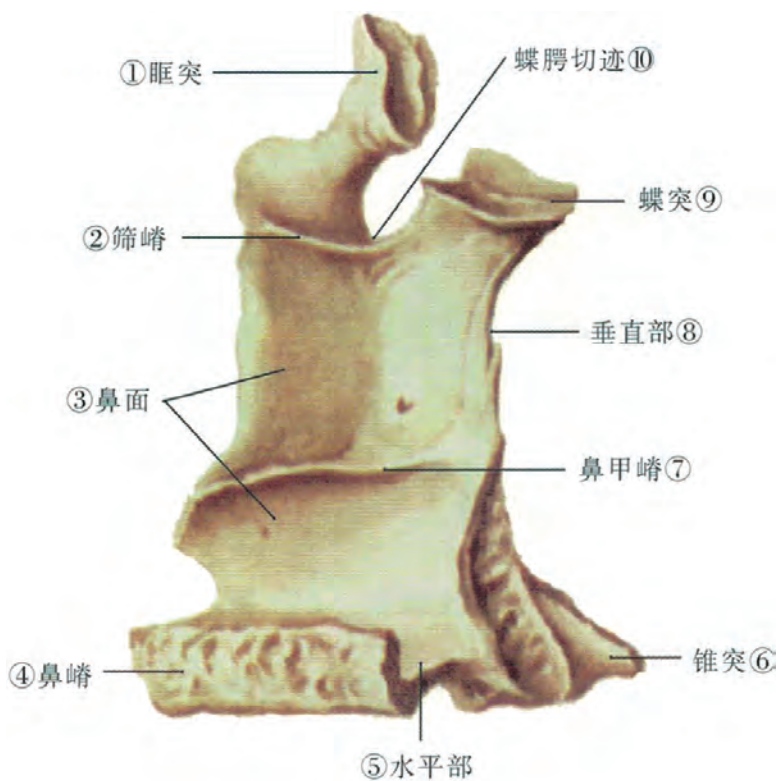
下颌管与下颌牙根的关系外侧面观



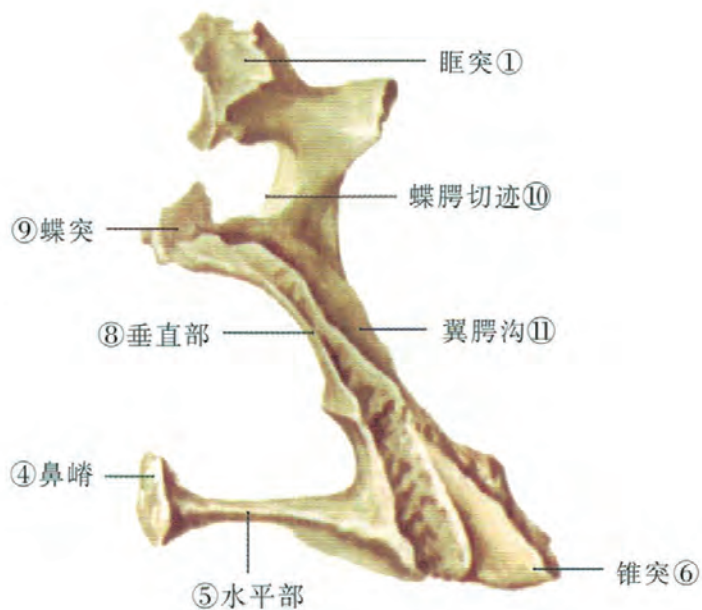
颌面骨的支柱结构外侧面观



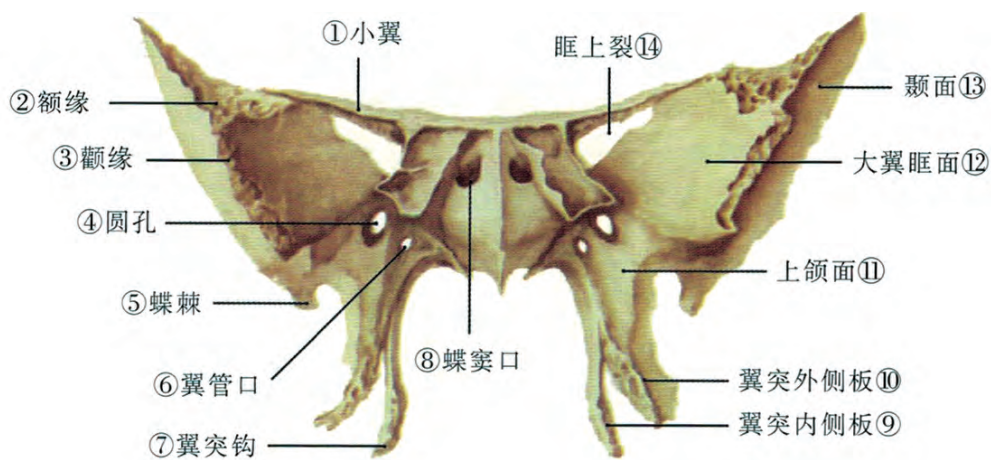
舌骨前外侧面观



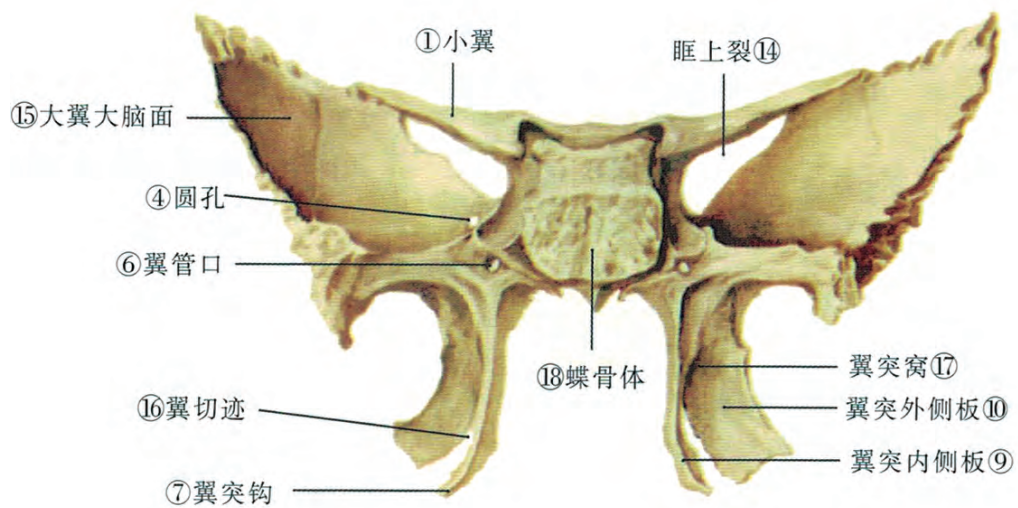
腭骨内侧面观



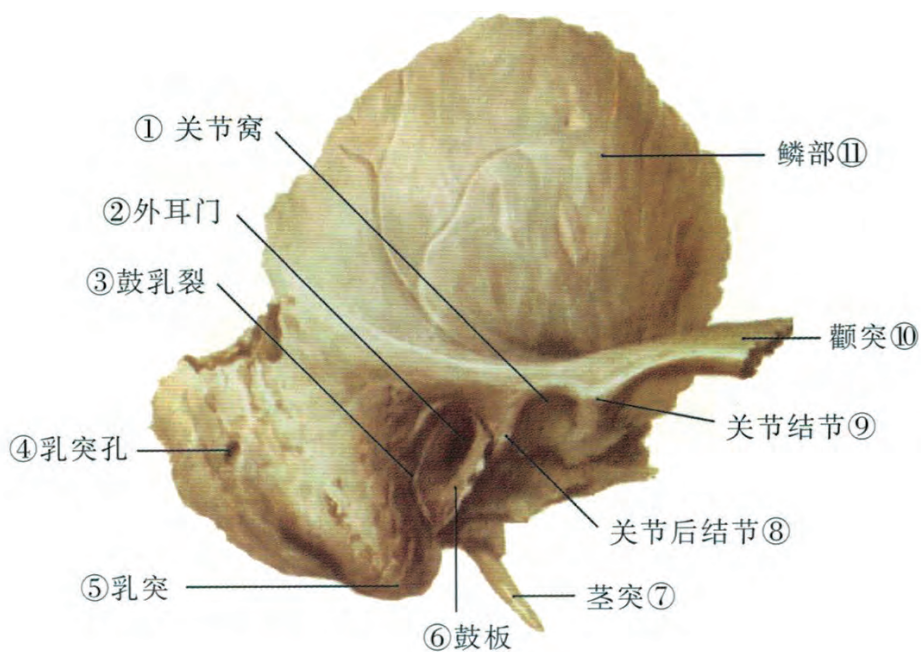
腭骨后面观



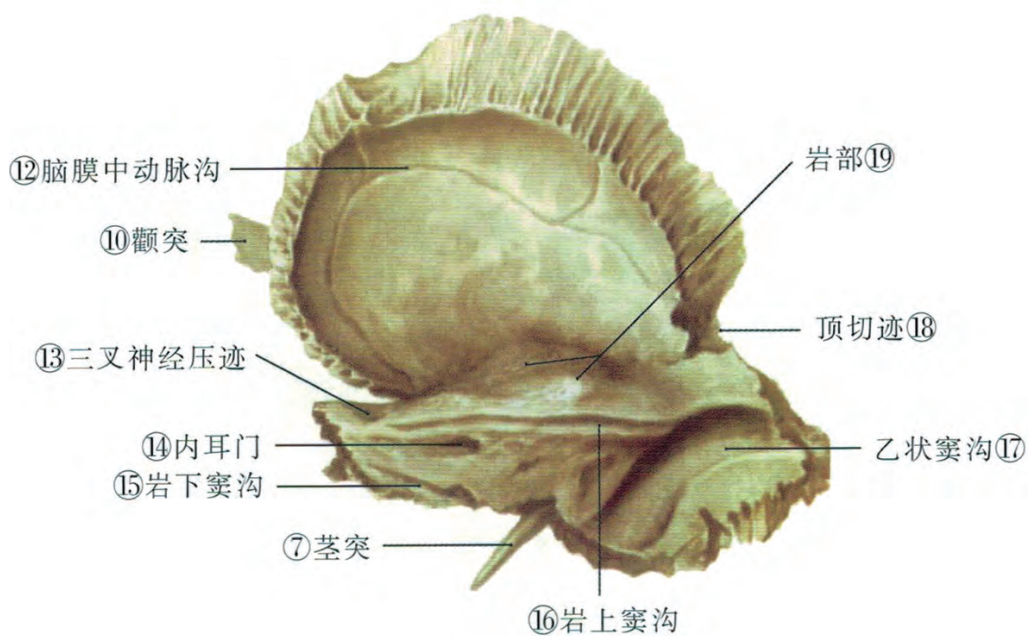
蝶骨前面观



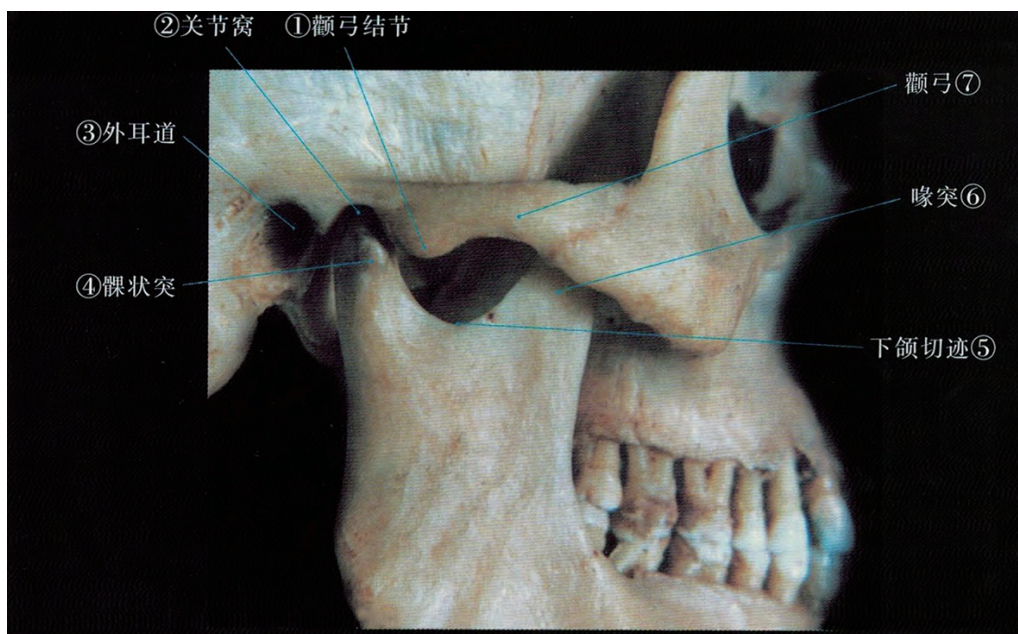
蝶骨后面观



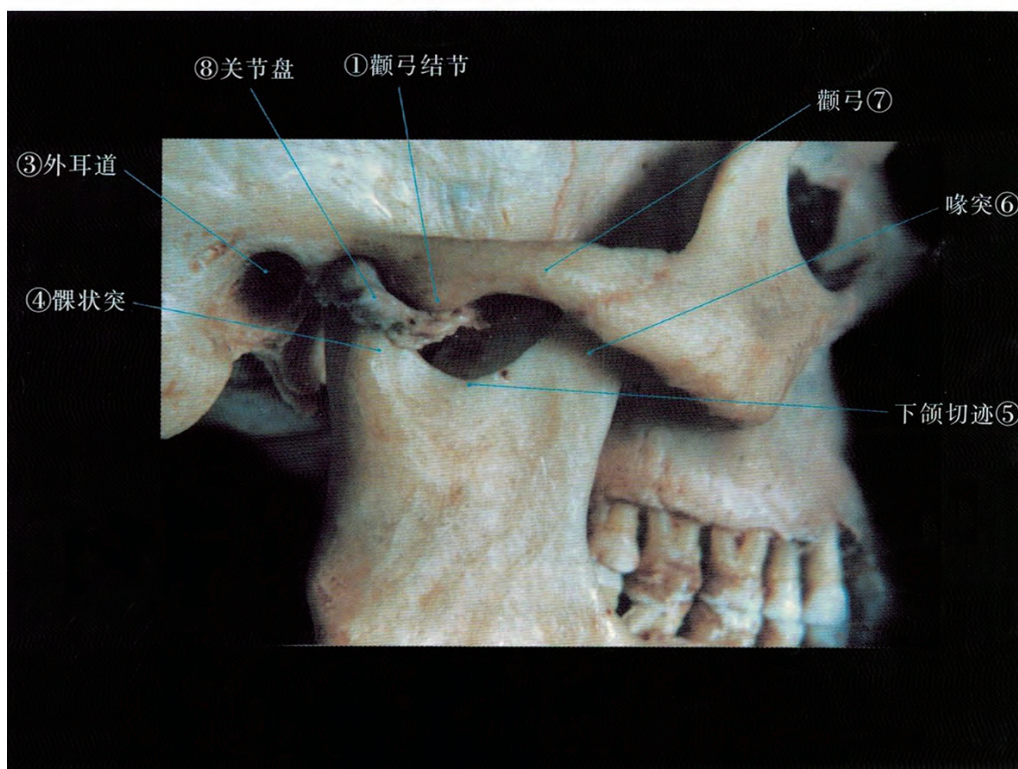颞骨外侧面观



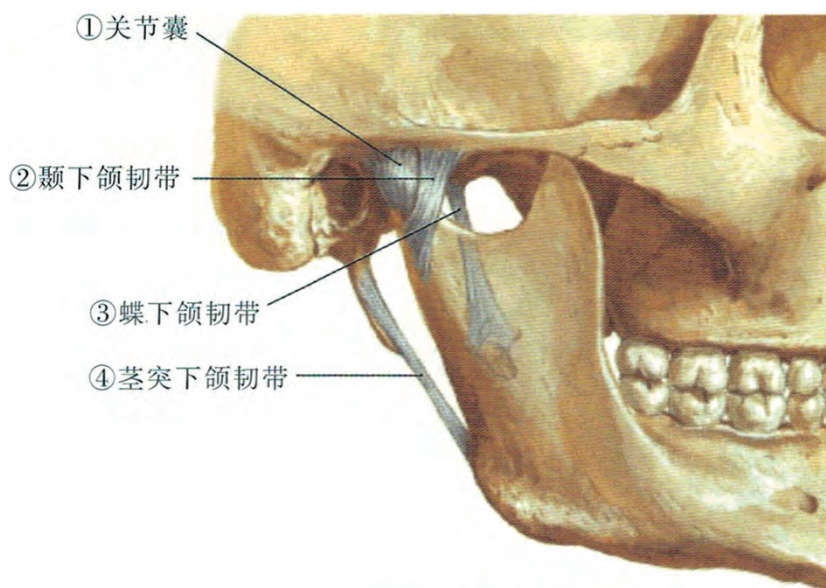
颞骨内侧面观



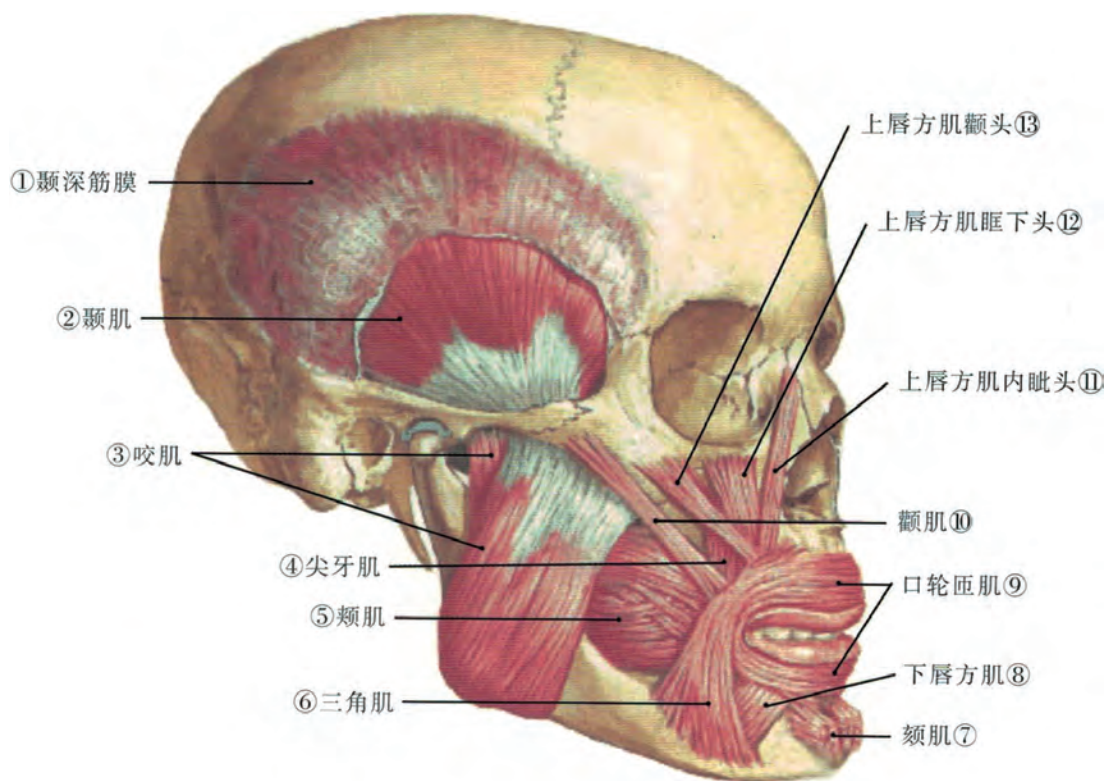
颞下颌关节骨性结构



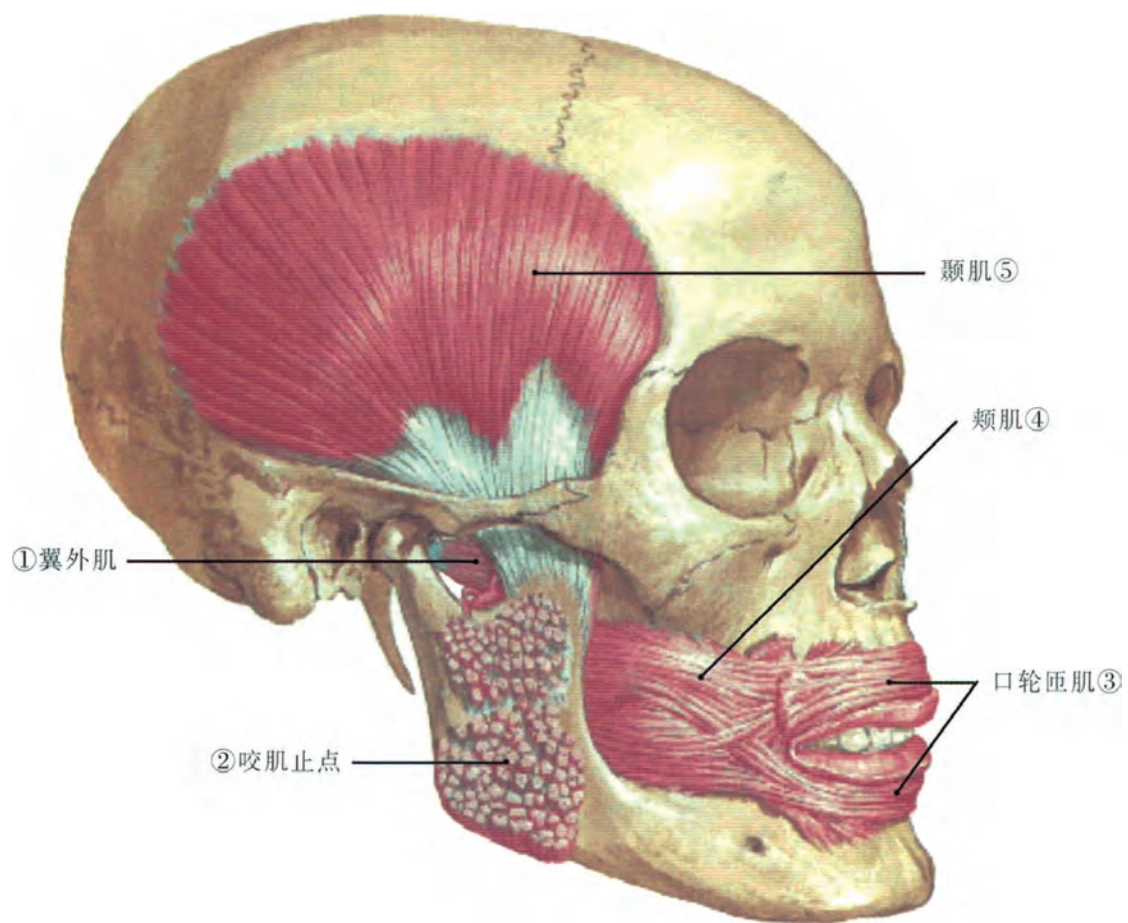
颞下颌关节结构关系



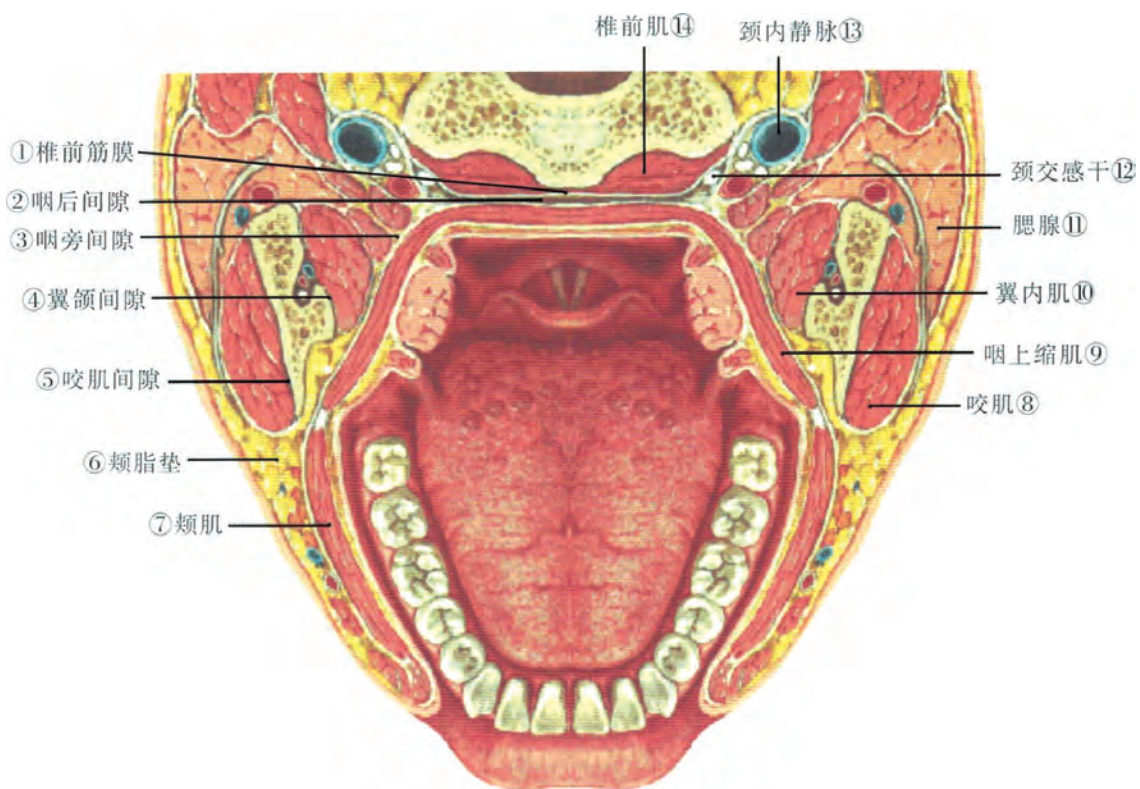
颞下颌关节外侧观



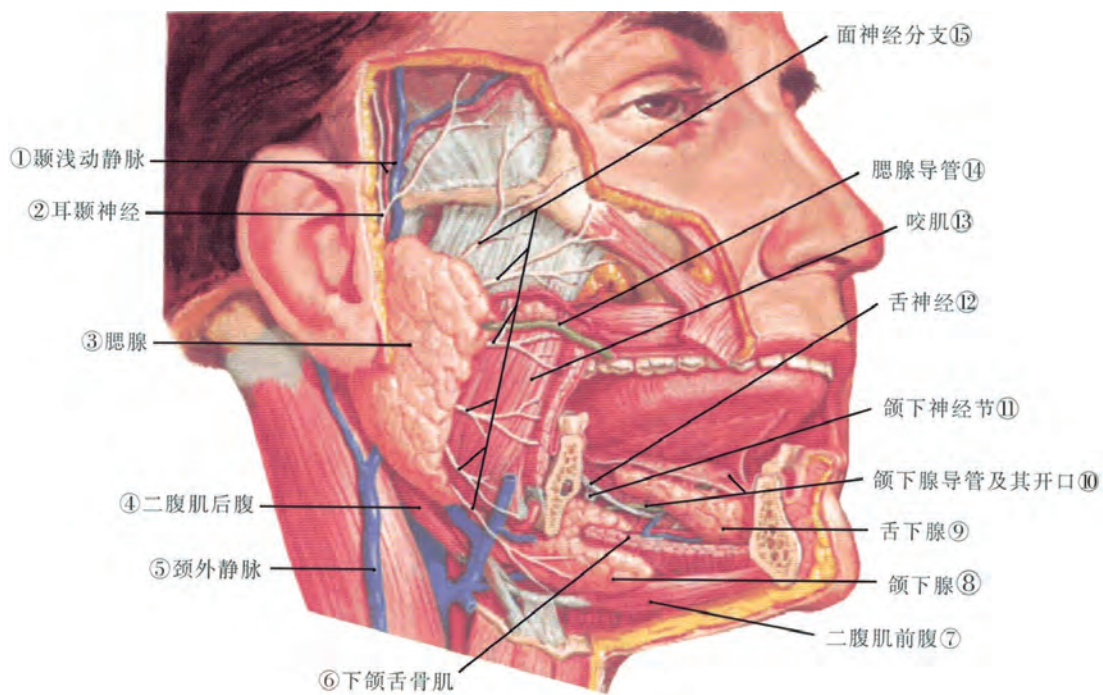
面部肌肉外侧观



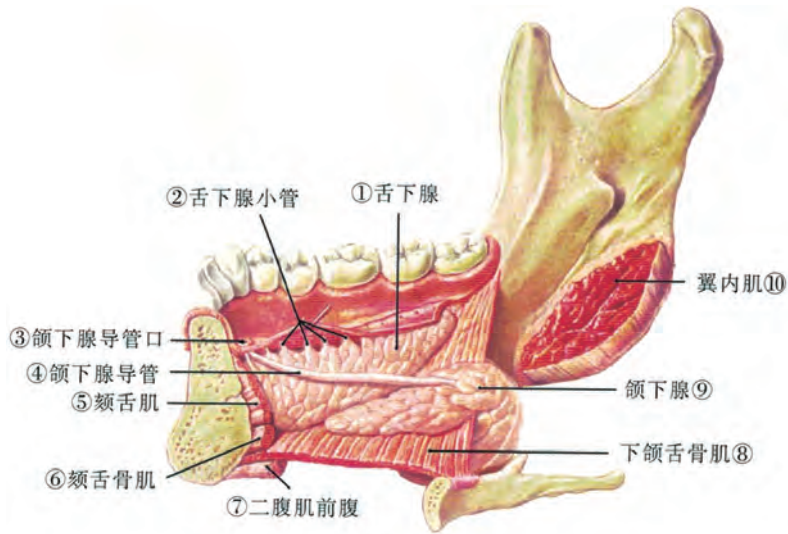
面部肌肉外侧面观



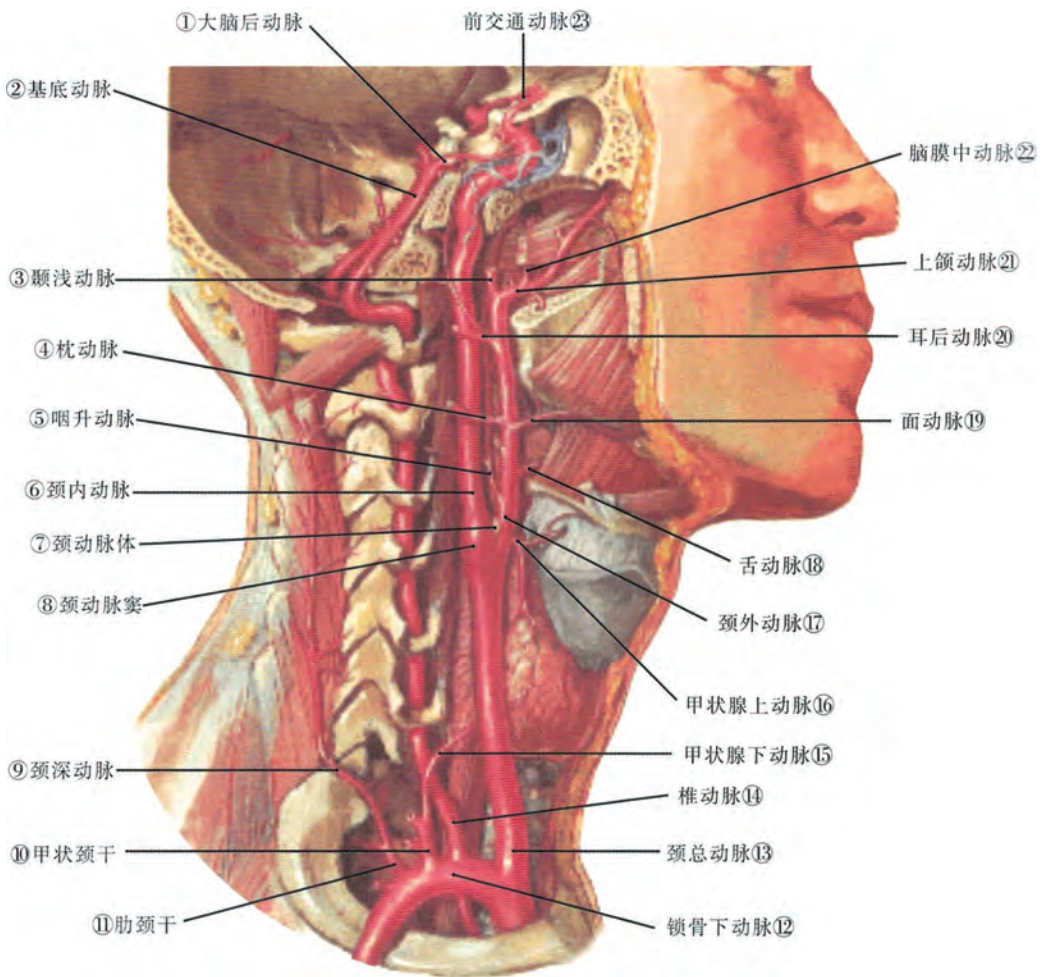
颌周蜂窝组织间隙水平切面观



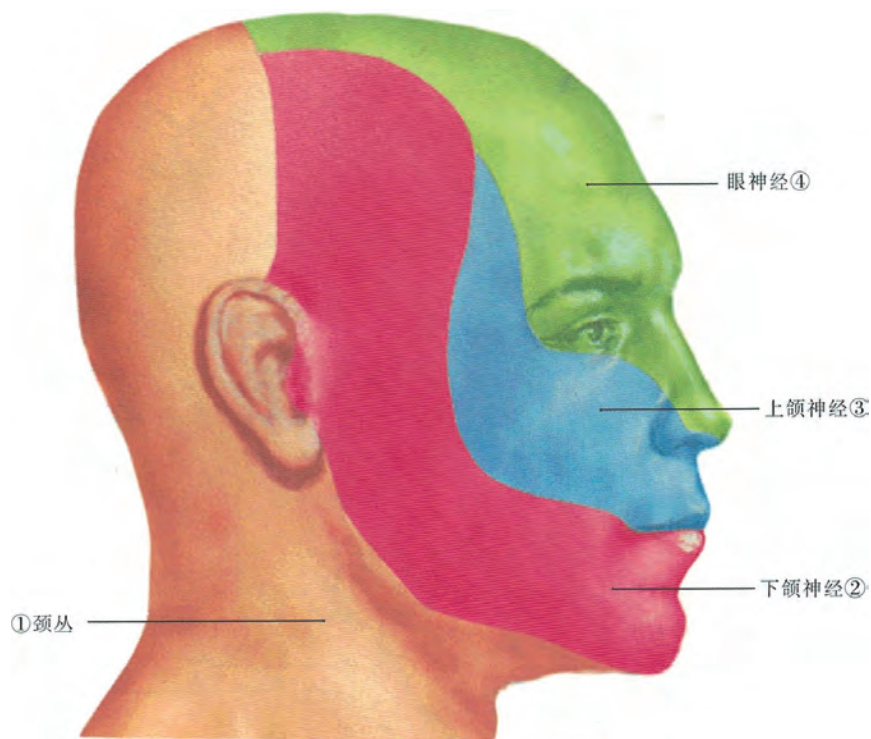
三大唾液腺外侧观



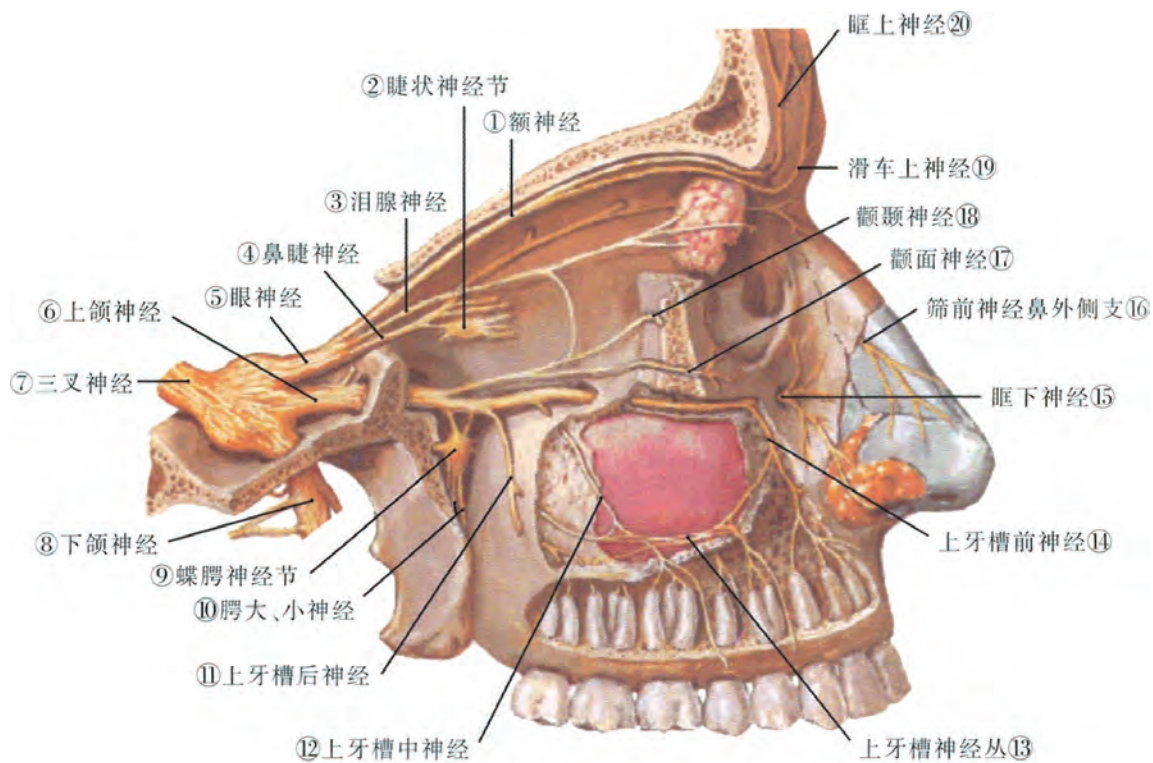
颌下腺及舌下腺内侧面观



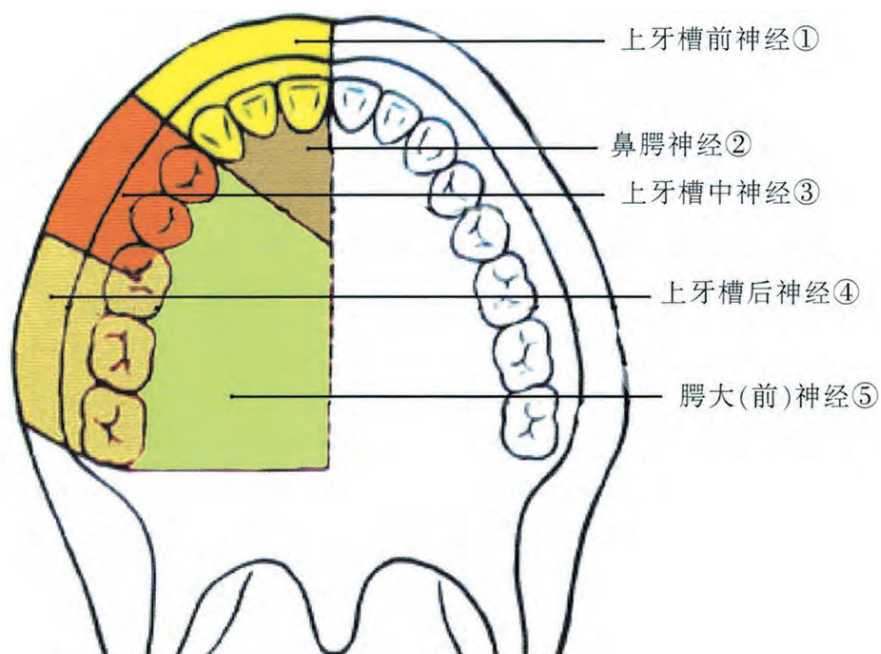
颈总动脉及锁骨下动脉的主要分支



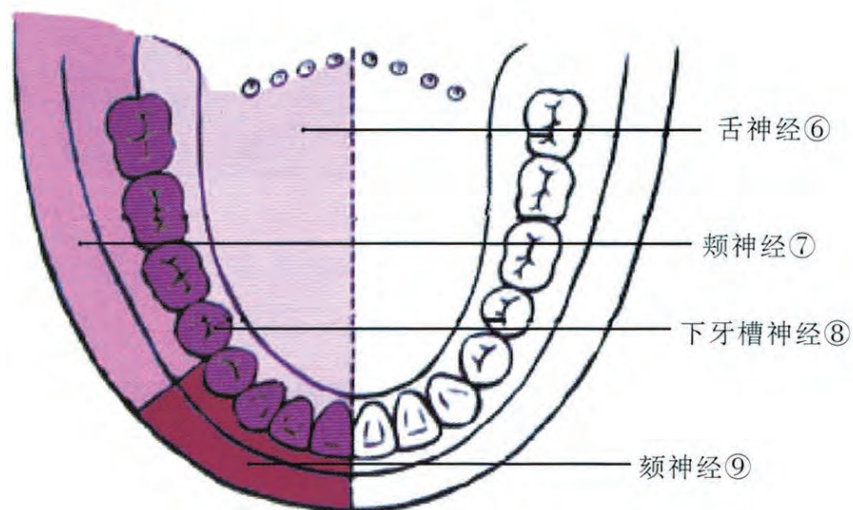
颌面颈部皮肤感觉神经分布示意图



眼神经及上颌神经外侧面观

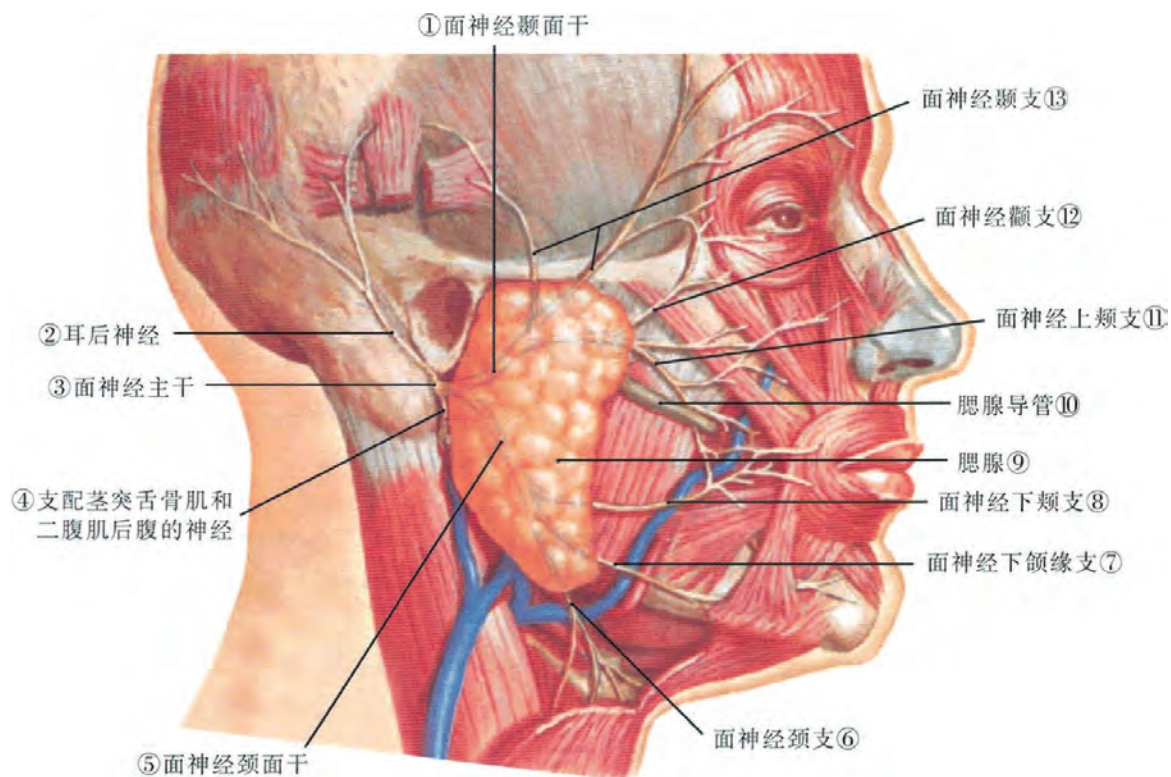


上 颌

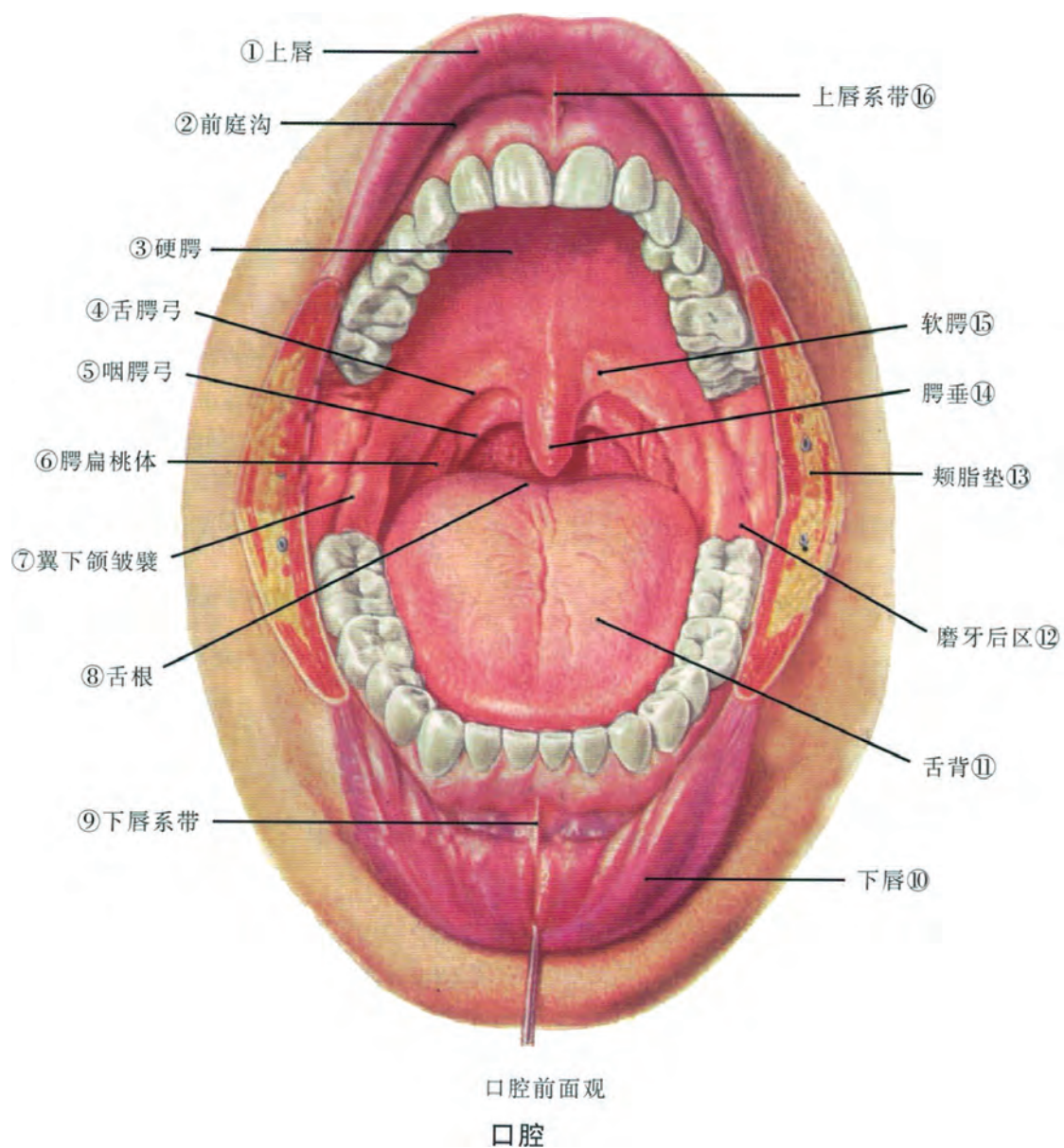


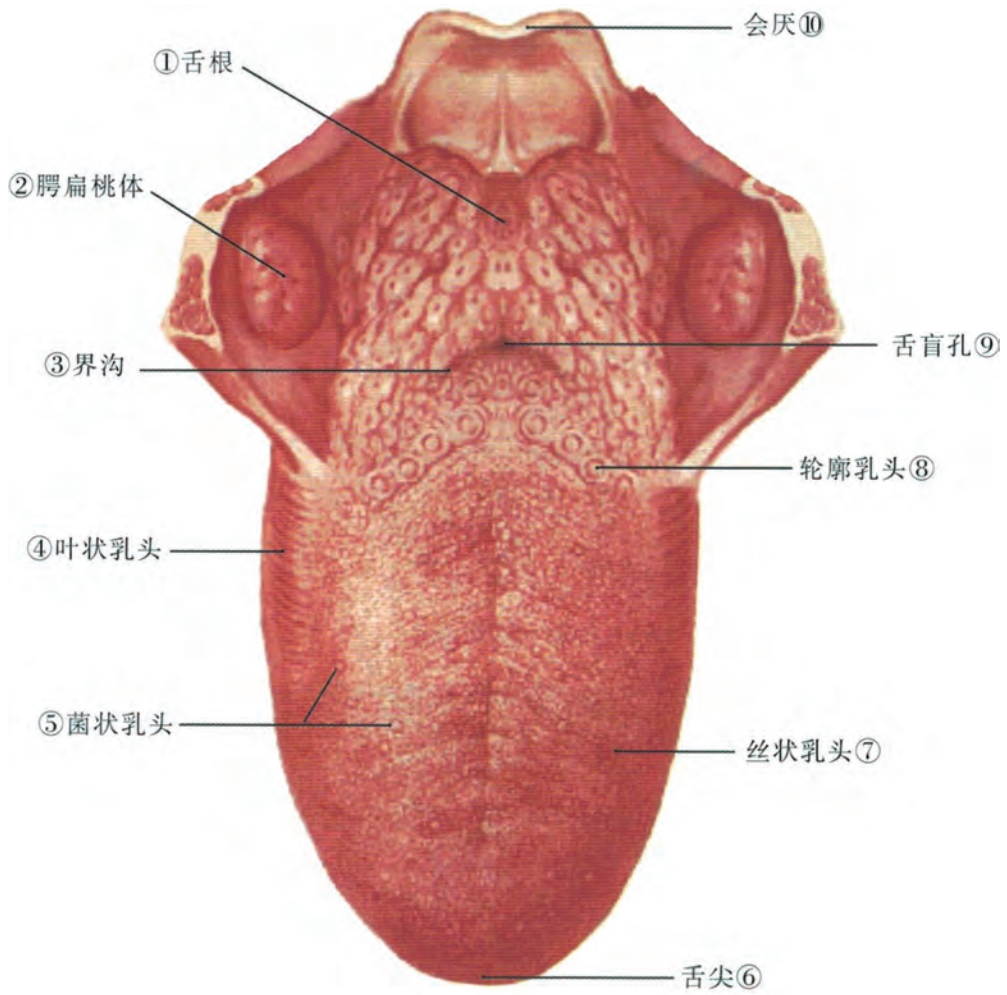
下 颌

上下颌神经在口腔的分布



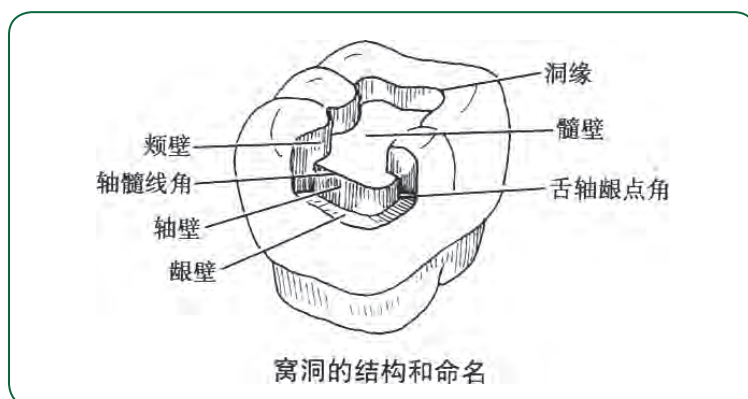
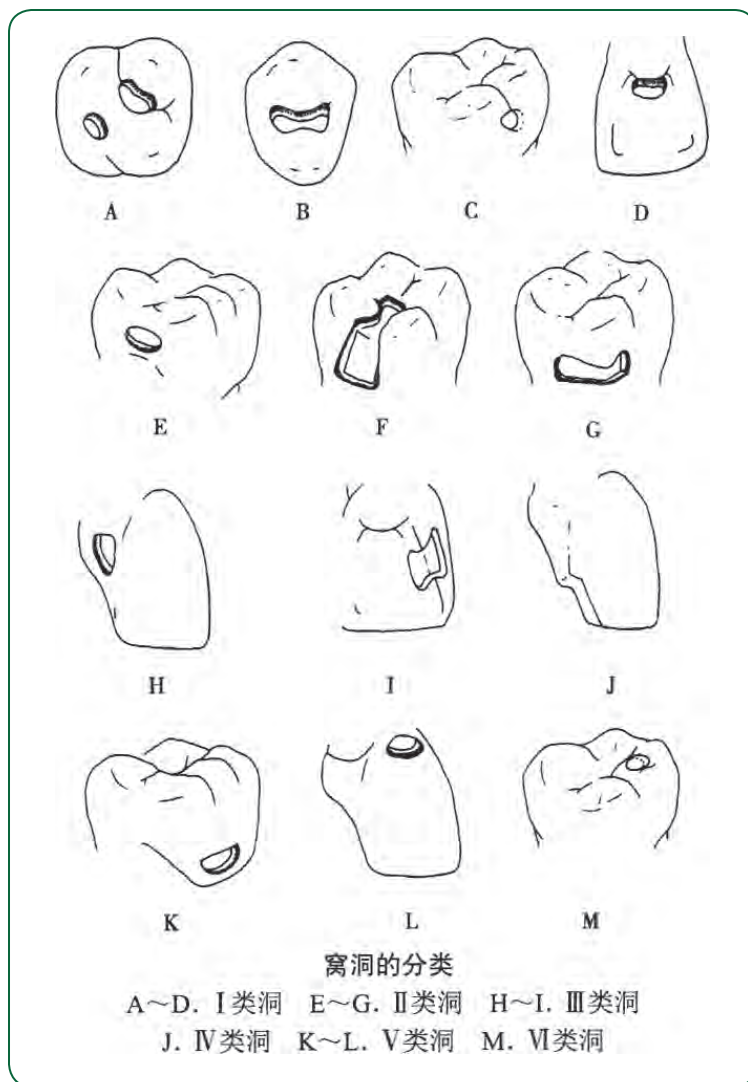
面神经分支及其与腮腺的关系

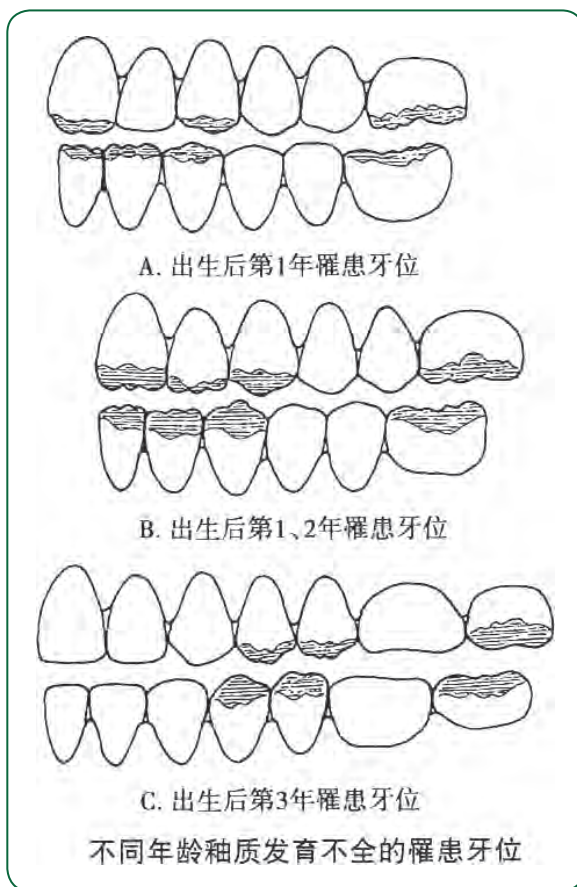
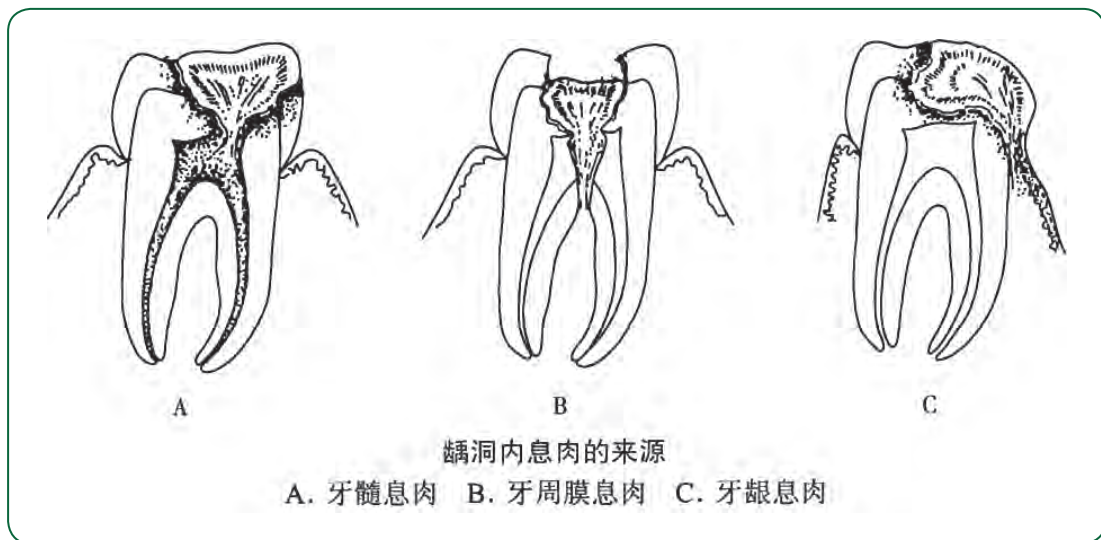


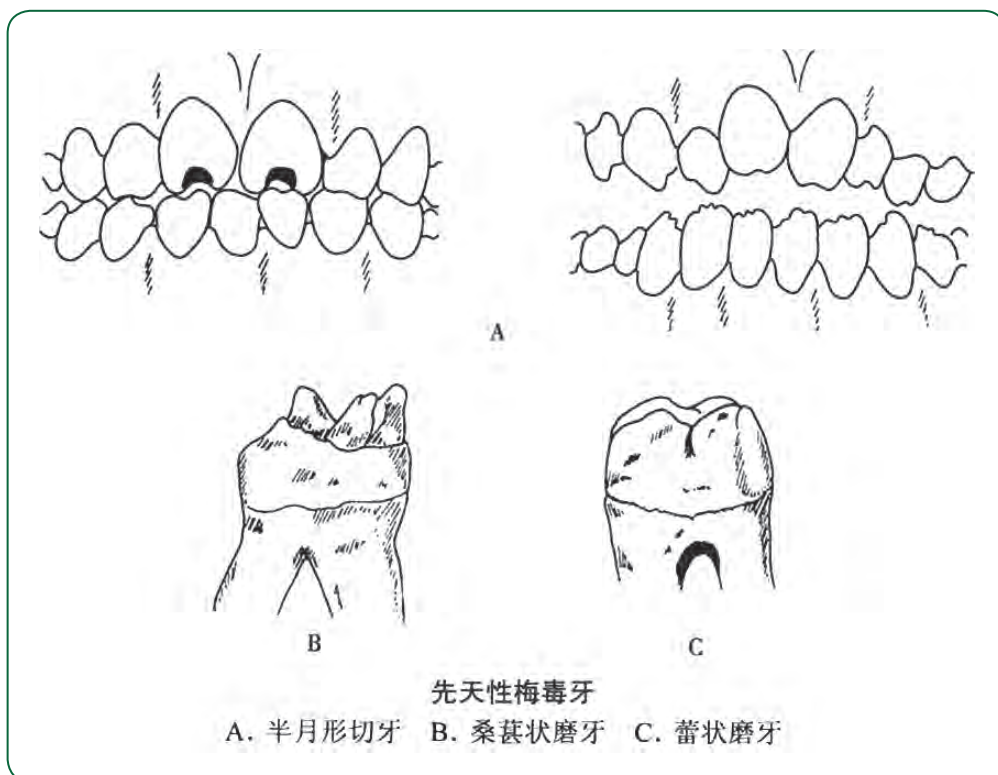
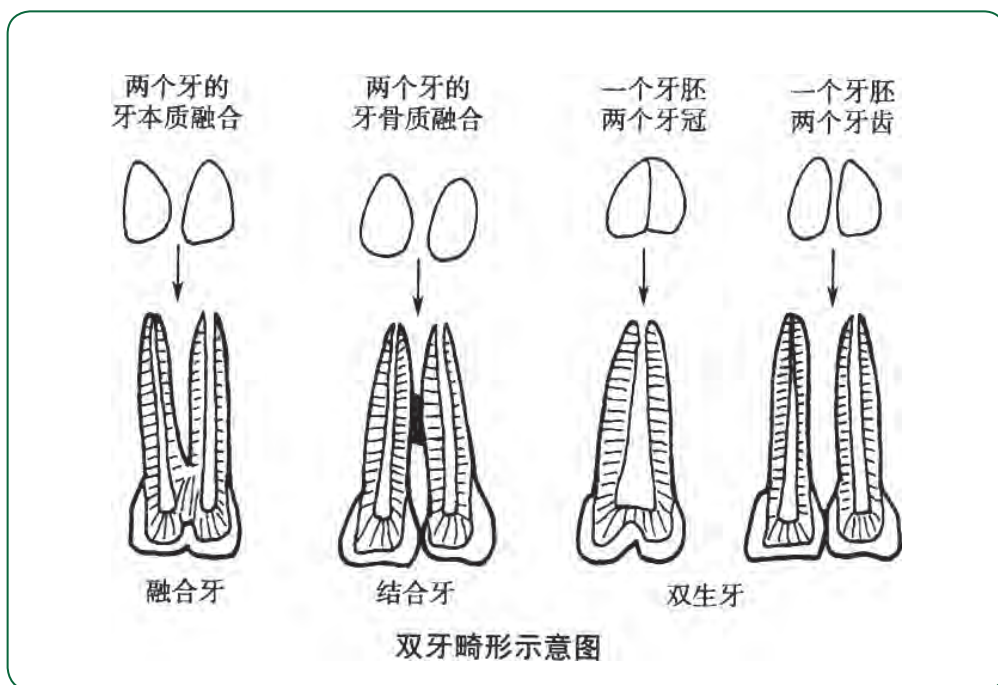


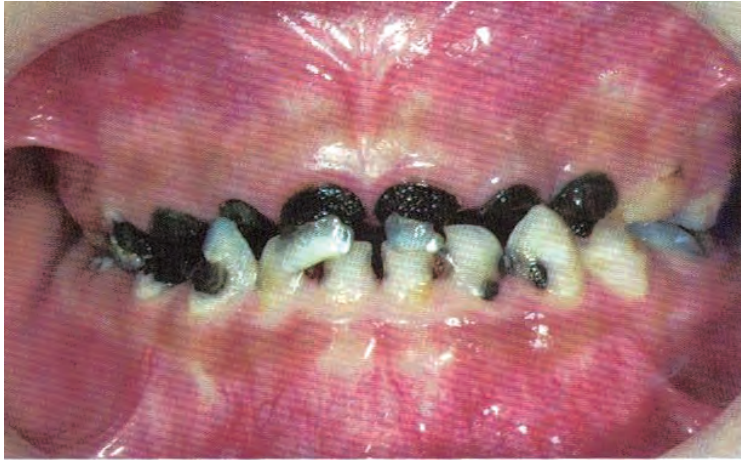舌背上面观

牙体牙髓病学、儿童口腔医学

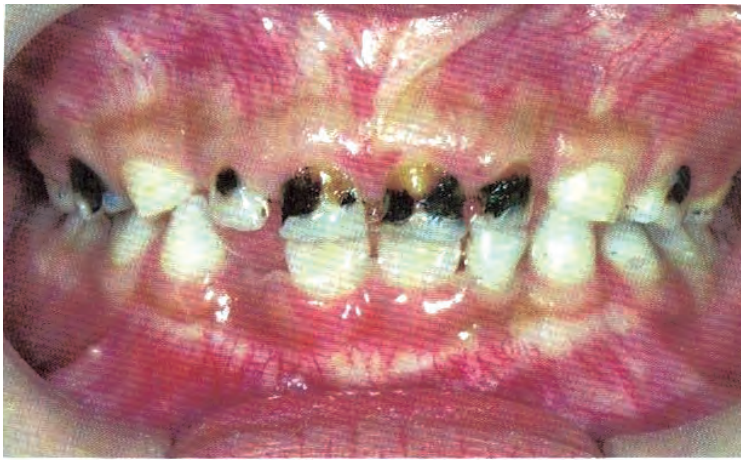




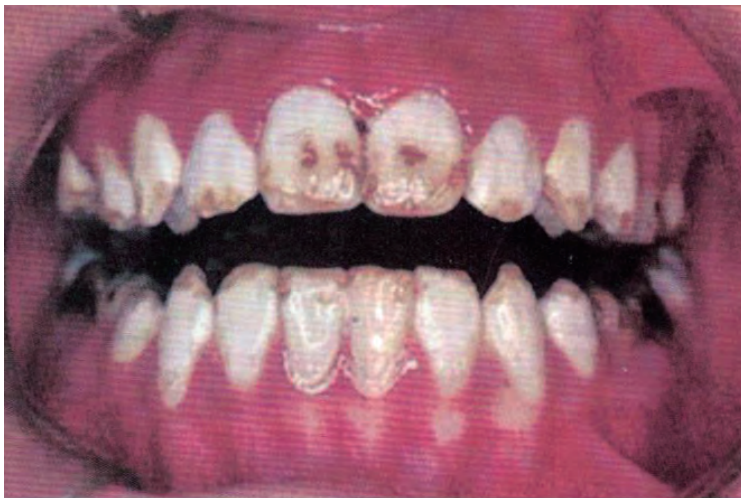


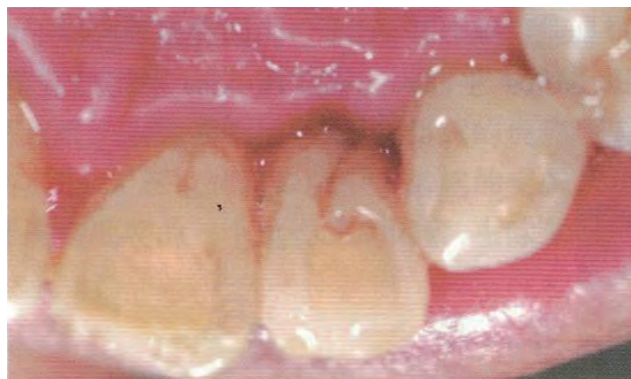猛性龋



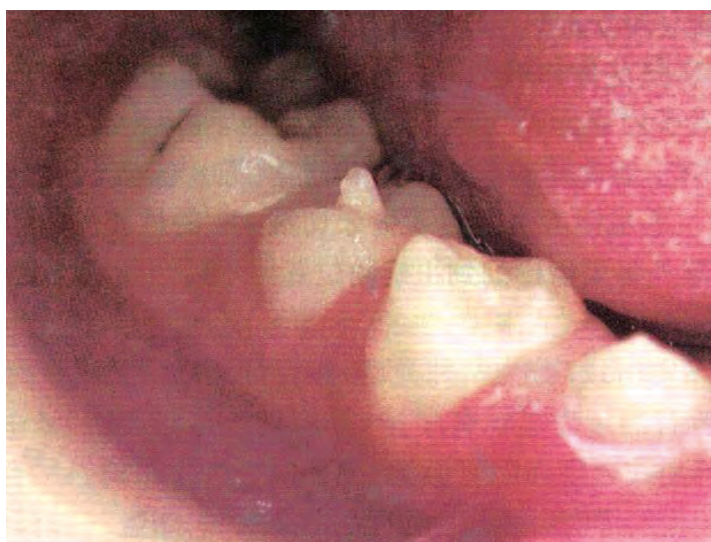环状龋



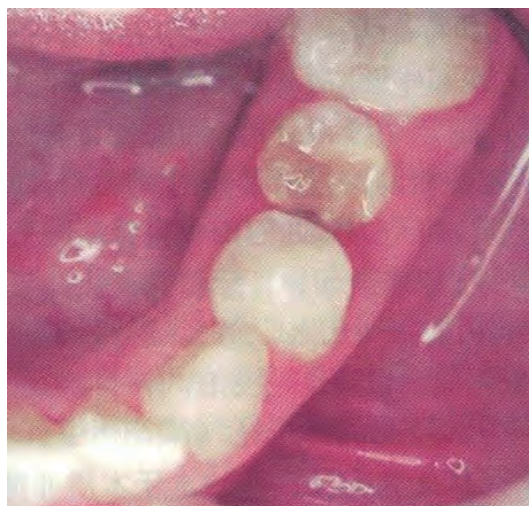氟牙症



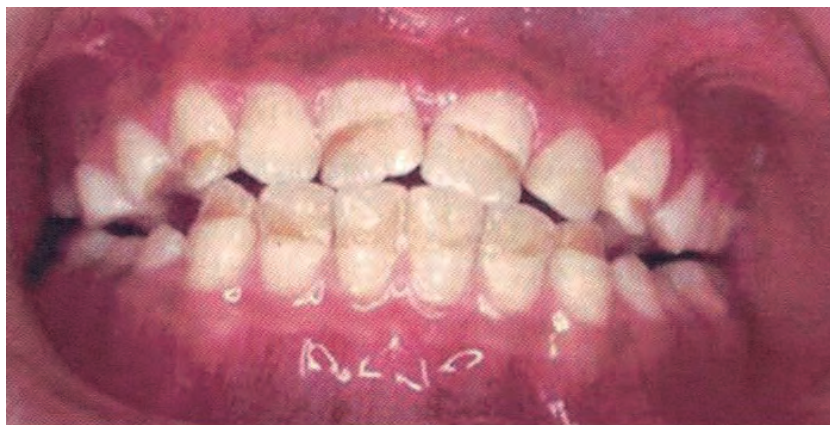
畸形舌侧沟



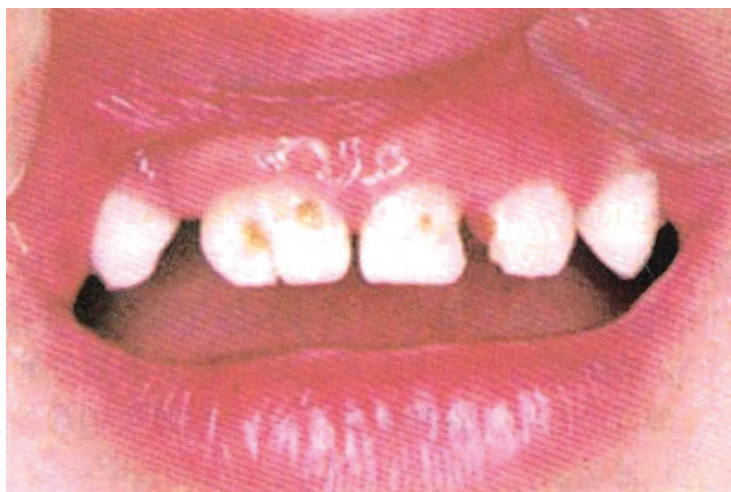
畸形中央尖(45)



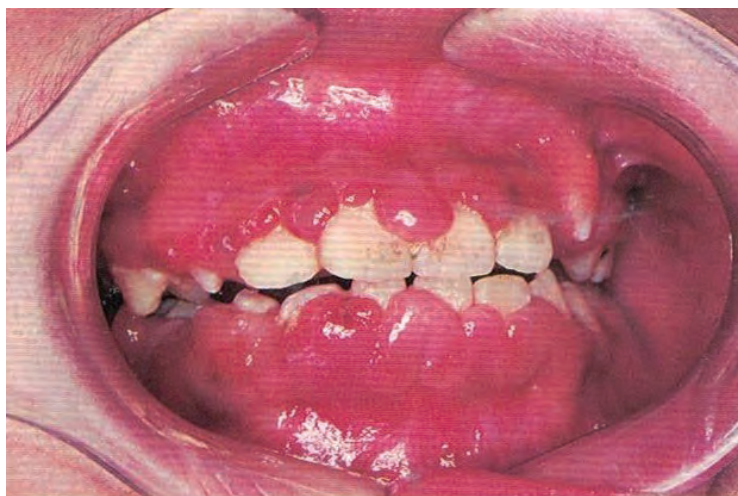特纳牙(35)



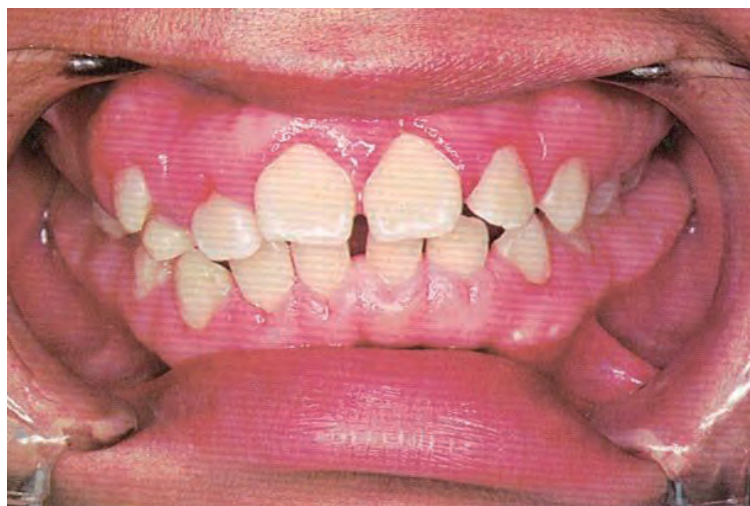釉质发育不全



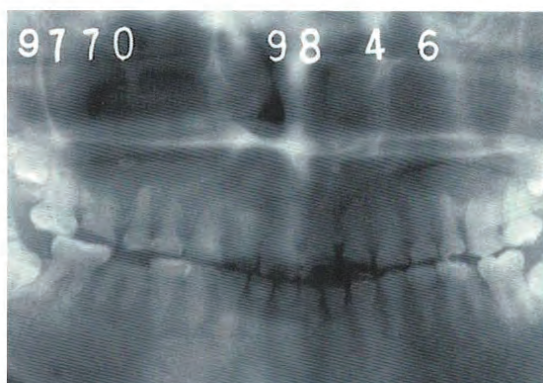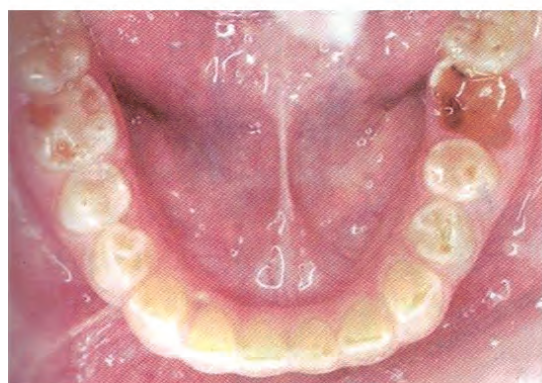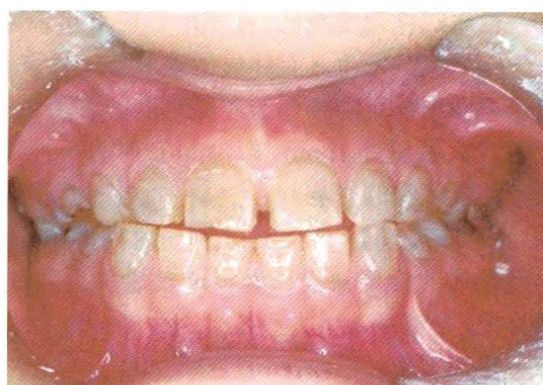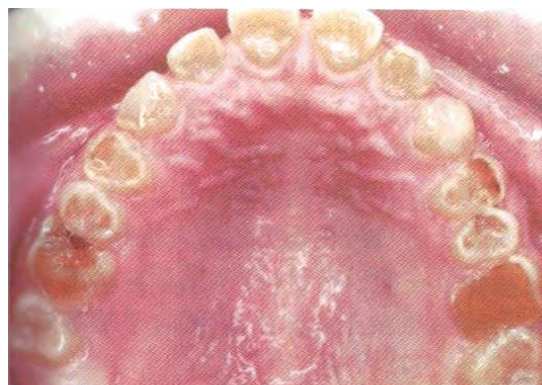融合牙(51, 52)



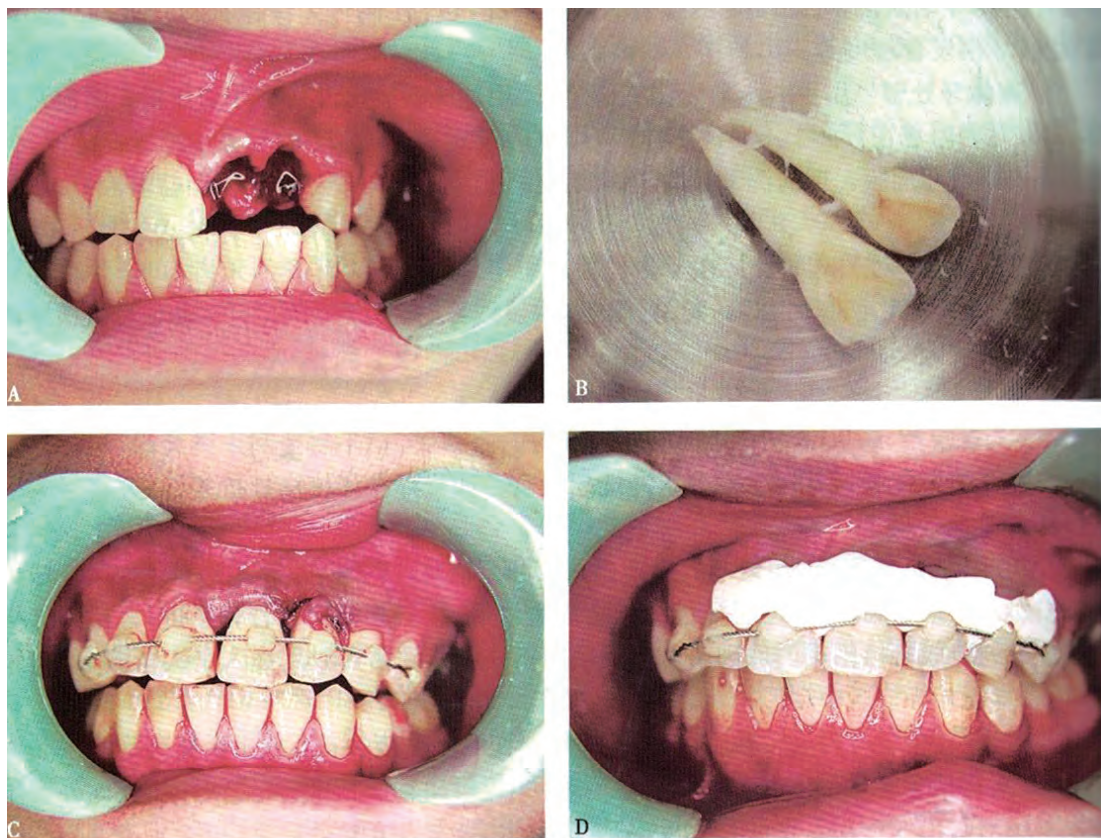
药物性牙龈增生(女, 10岁)



牙龈纤维瘤病(男, 13岁)



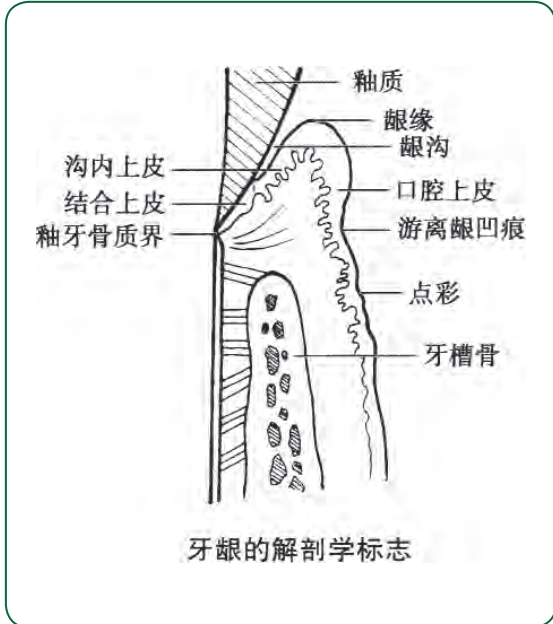
遗传性乳光牙本质



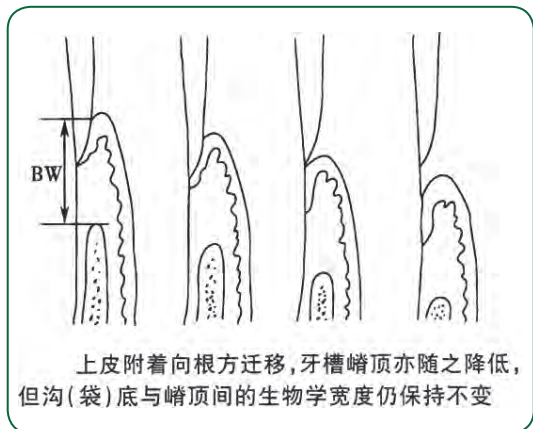
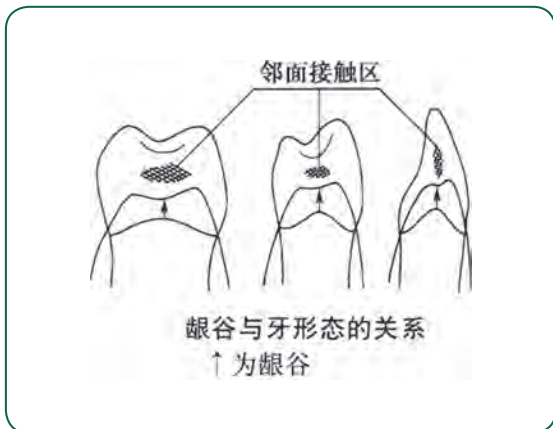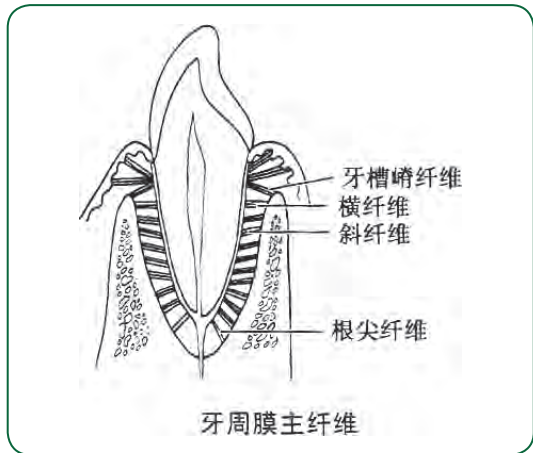
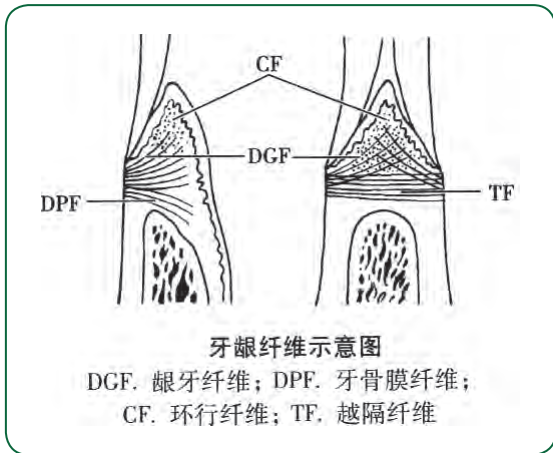
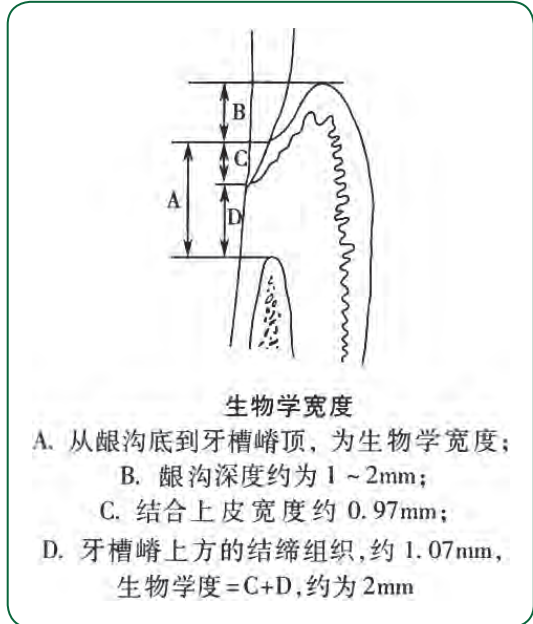
全脱出的复位固定(21, 22)

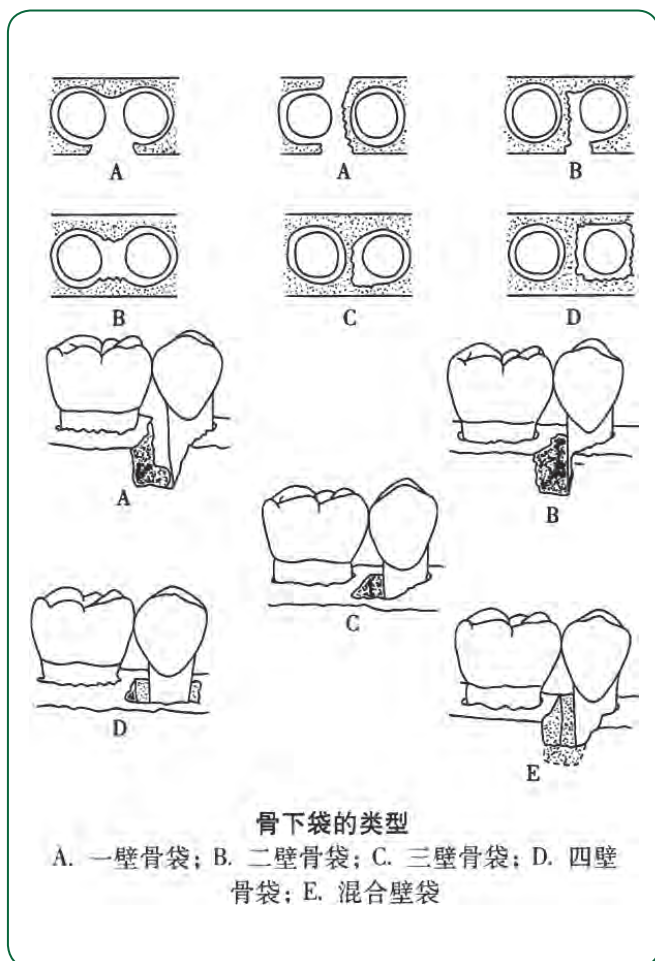
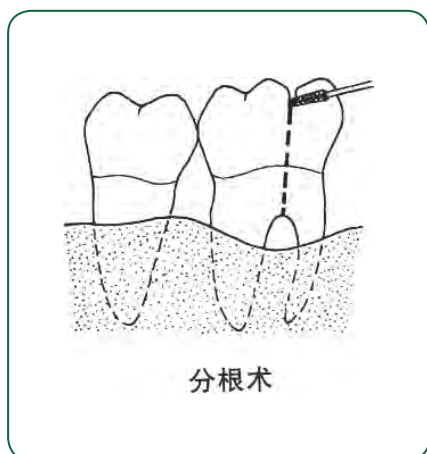
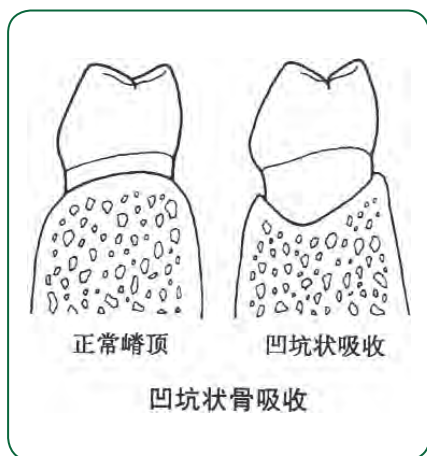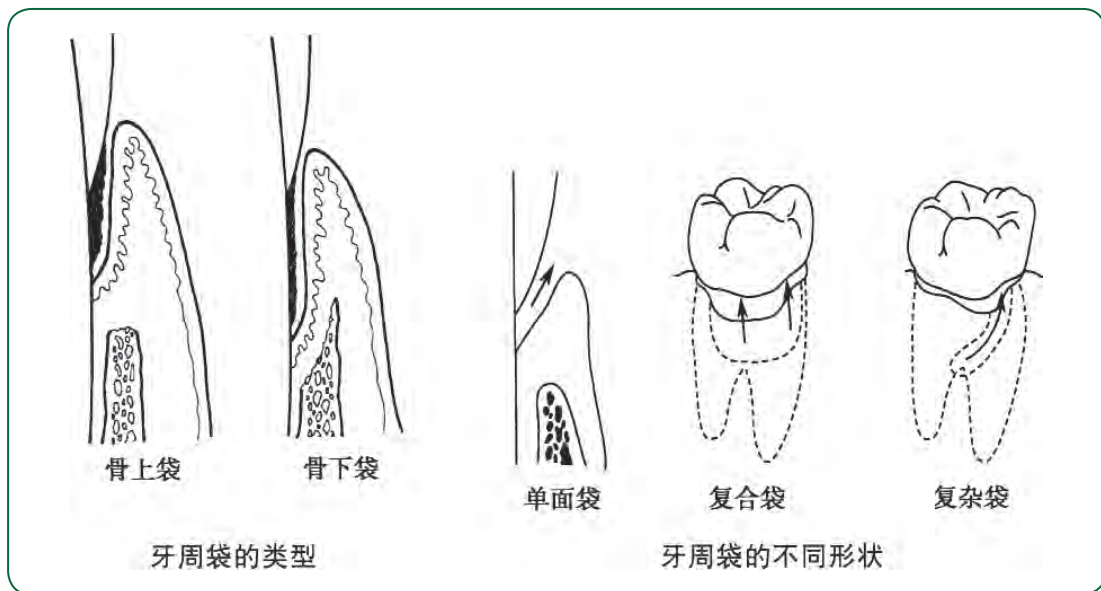
- A. 牙齿全脱出(21, 22) B. 浸泡在生理盐水内的全脱出牙
C. 全脱出的复位固定(21, 22) D. 全脱出的复位固定后牙周塞治剂保护牙龈

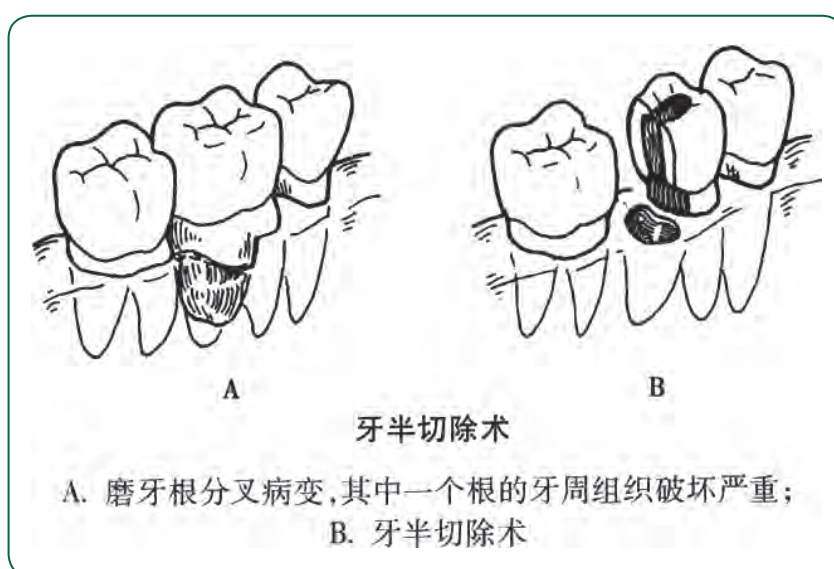
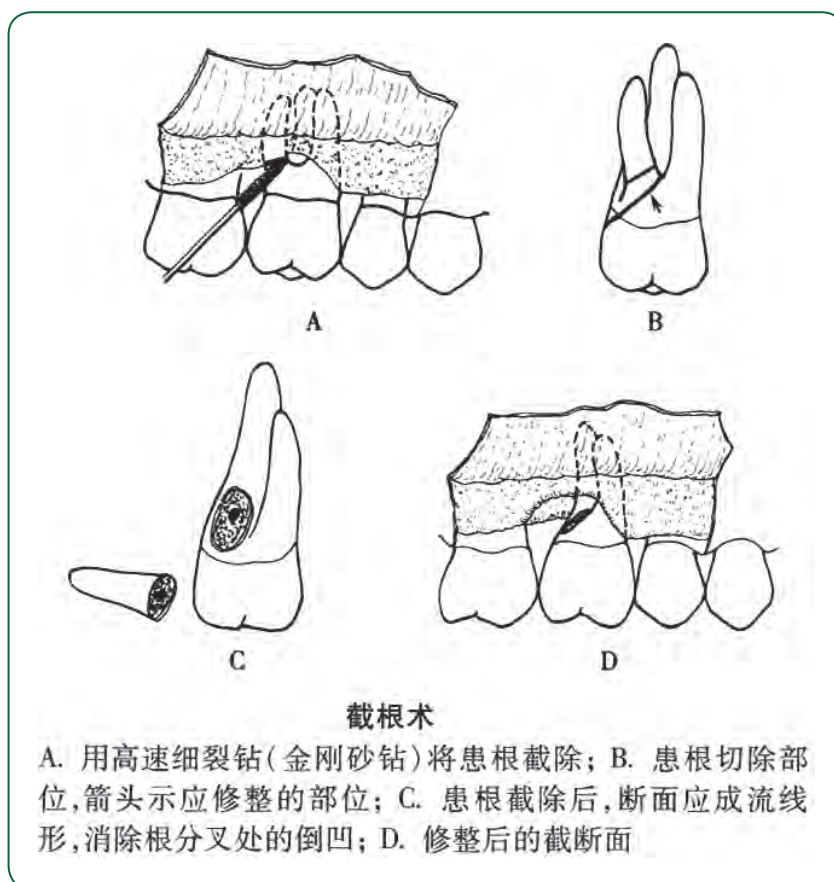
牙周病学

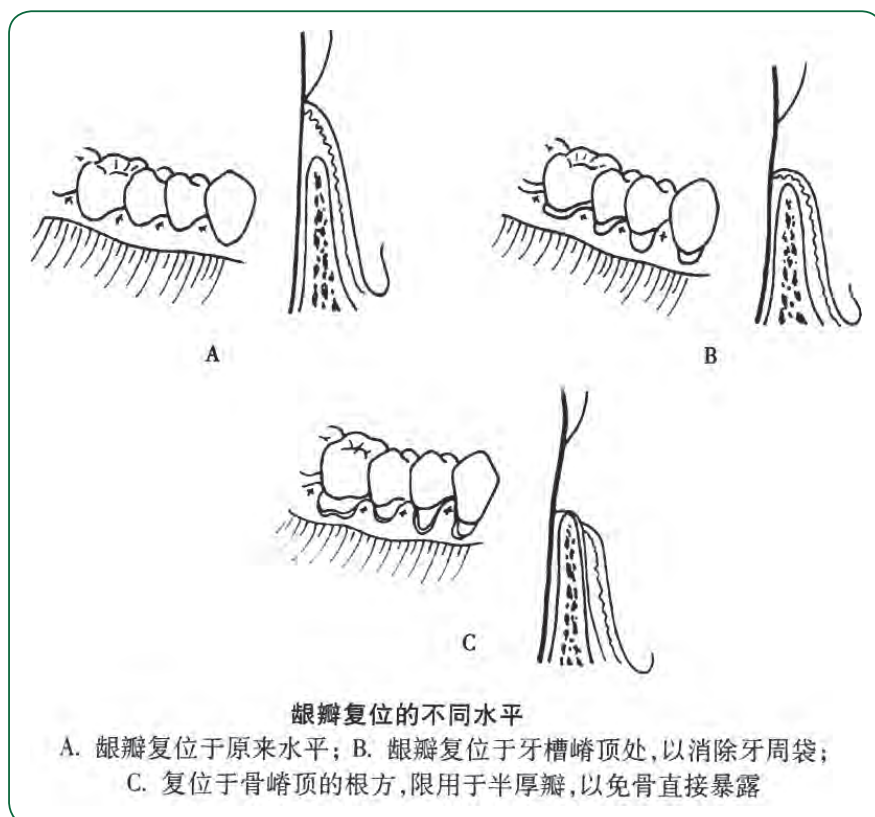
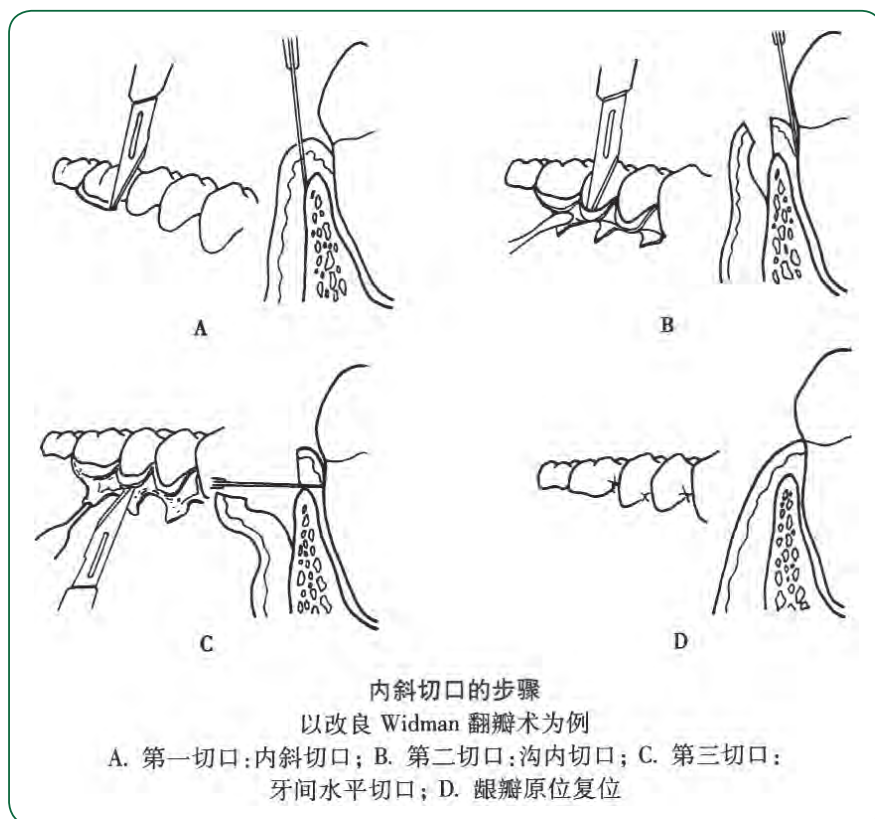


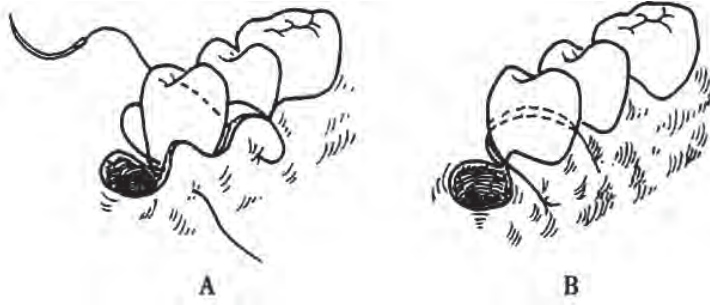
牙龈的解剖学标志





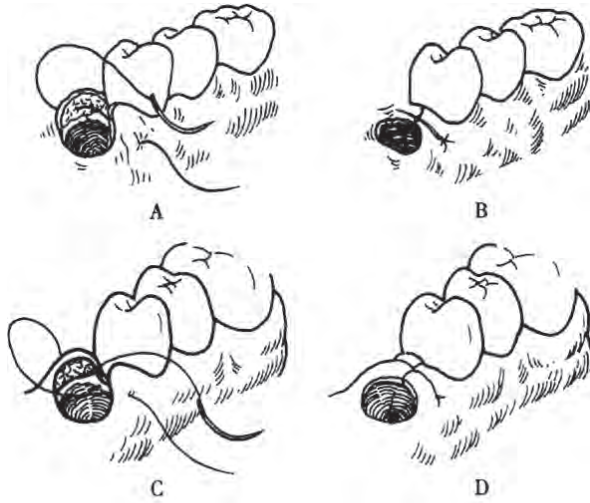






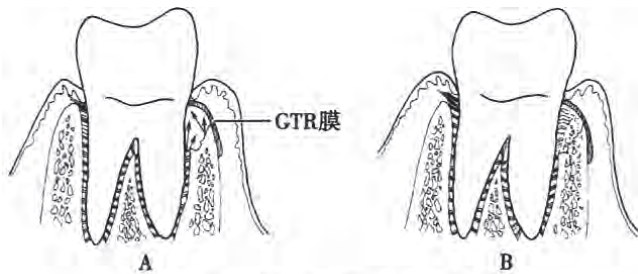
单侧翻瓣时的双乳头悬吊缝合

A. 从瓣的近中乳头外表面进针,缝线环绕牙齿,到达同侧龈瓣的远中,再从远中龈乳头的外表面进针; B. 返回近中乳头处,打结,将单侧瓣的二个乳头悬吊在牙上



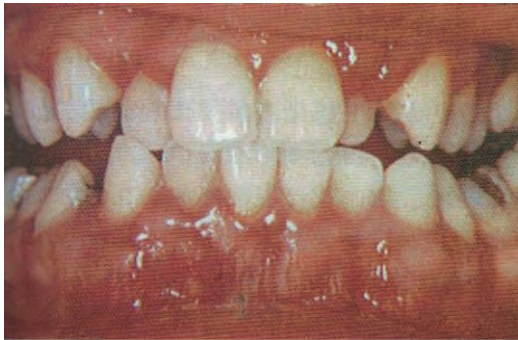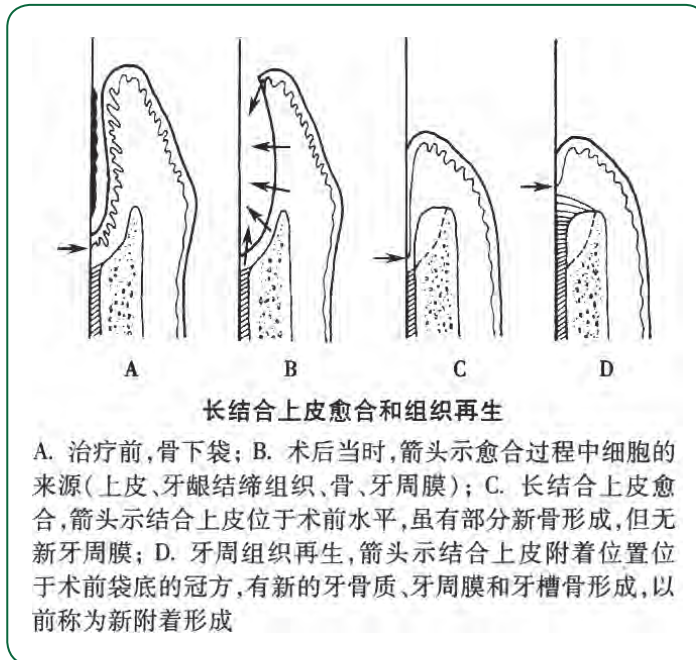
牙间间断缝合

A、B. 直接环形间断缝合; C、D. 8字形间断缝合

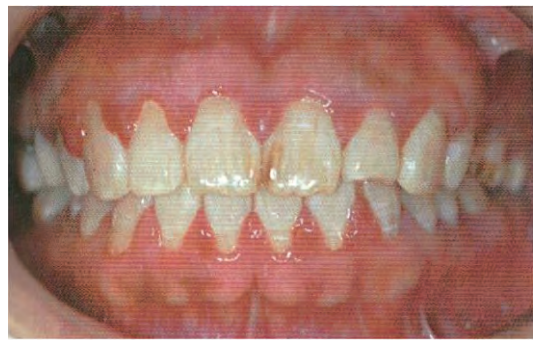

牙周引导性组织再生术(GTR)

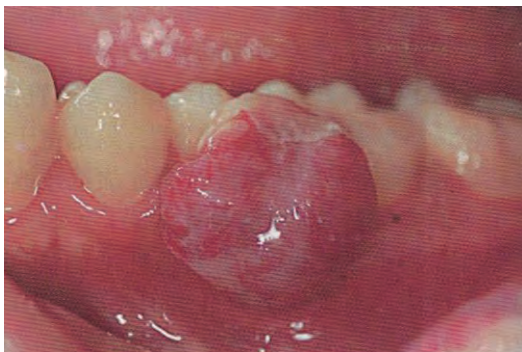
A. 在术区放置屏障膜,引导具有形成新附着能力的牙周膜细胞优先占领根面; B. 愈合后形成牙周组织的再生



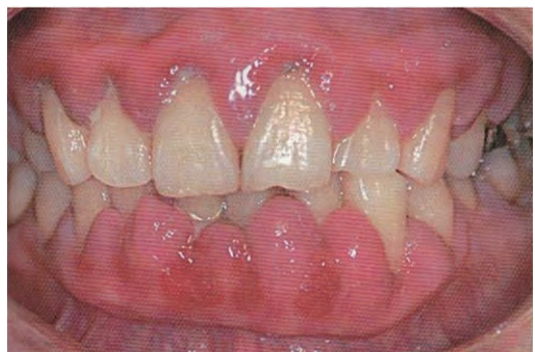慢性龈炎



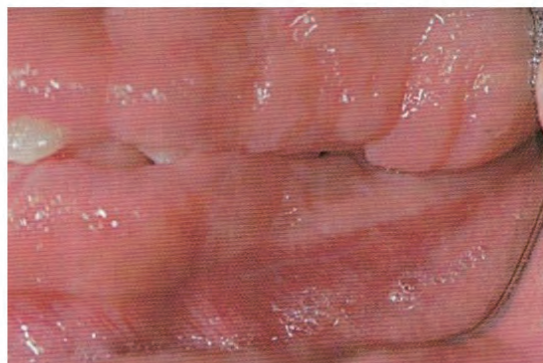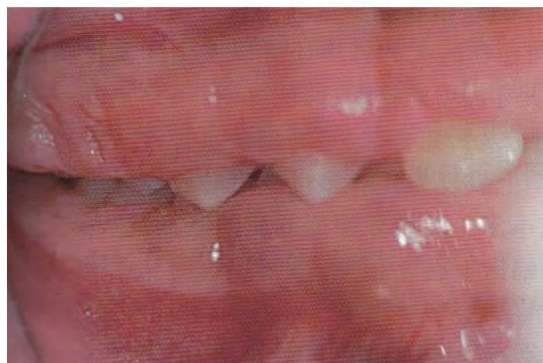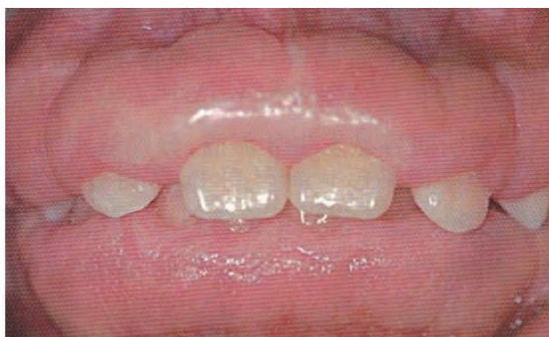妊娠期龈炎



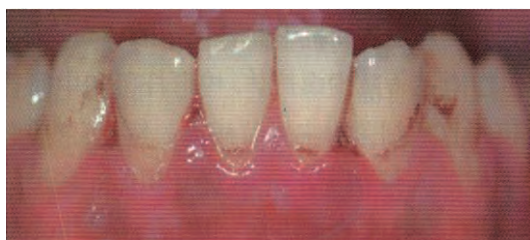妊娠期龈瘤



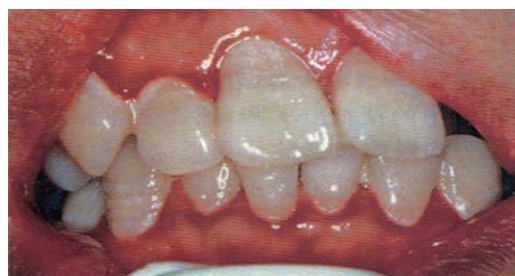苯妥英钠引起的牙龈增生



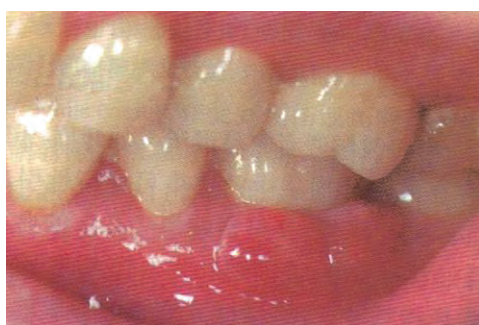牙龈纤维瘤病



急性坏死性溃疡性龈炎

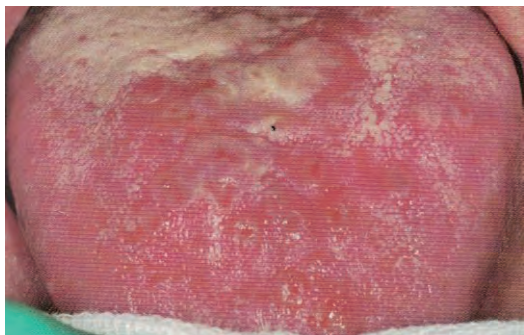


艾滋病患者的龈缘红线

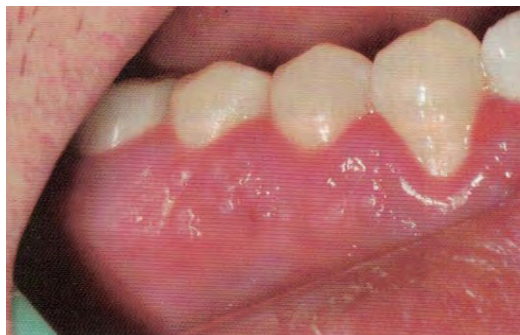

急性牙周脓肿

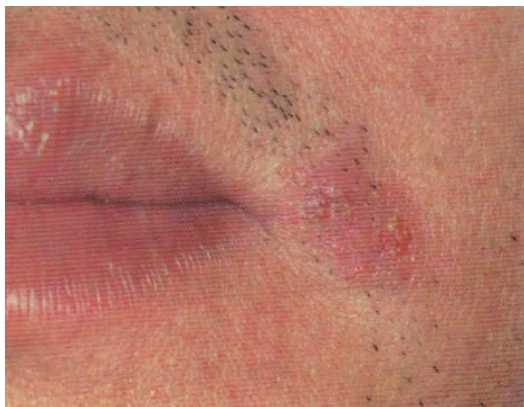
口腔黏膜病学



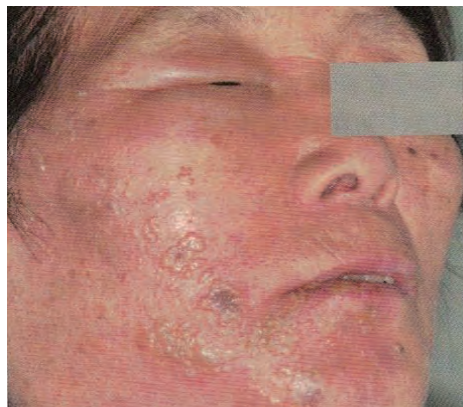原发性疱疹性口炎



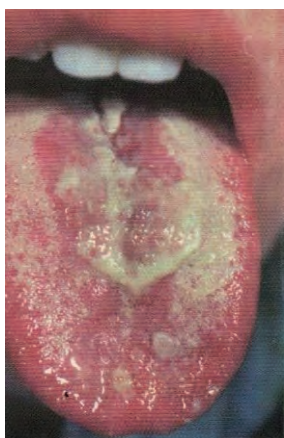原发性疱疹性口炎



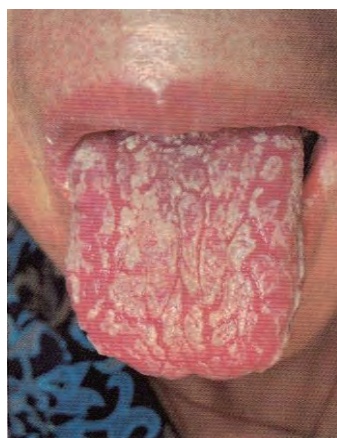
复发性疱疹性口炎



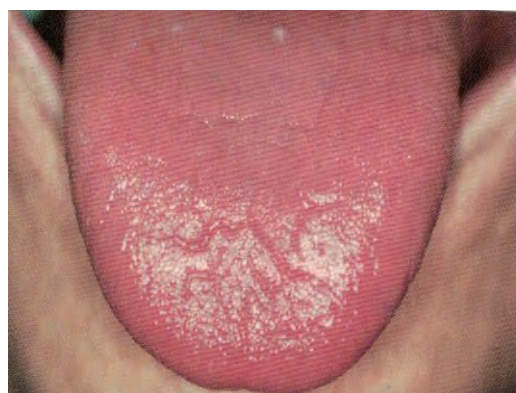带状疱疹



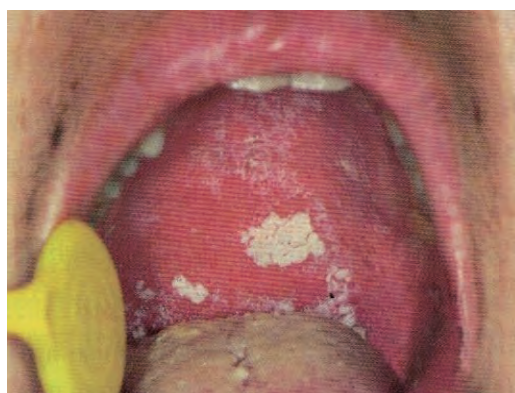
球菌性口炎



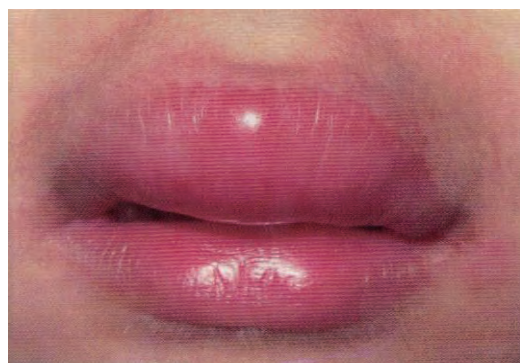增殖型念珠菌口炎



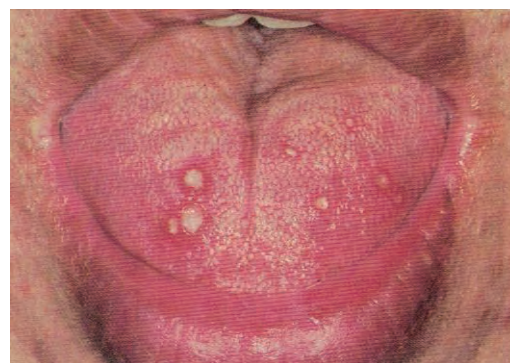
急性红斑型念珠菌性口炎



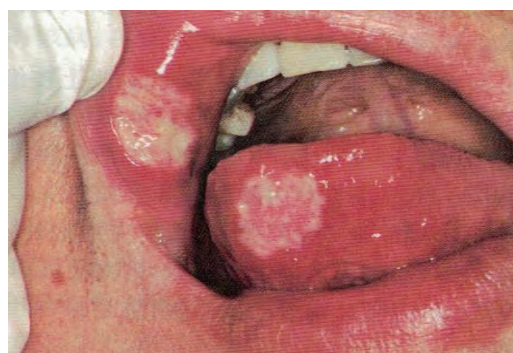急性假膜型念珠菌性口炎



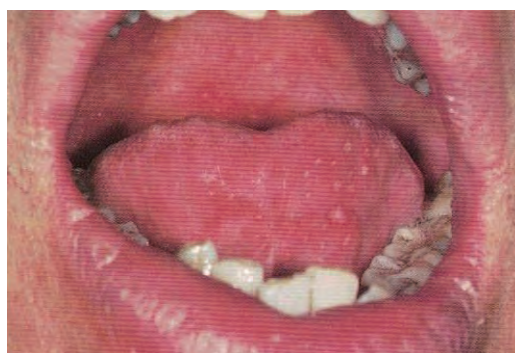
血管神经性水肿



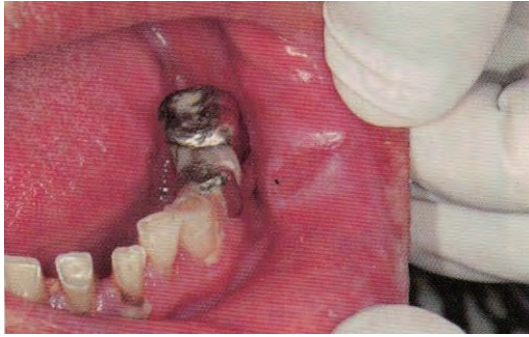轻型复发性阿弗他溃疡



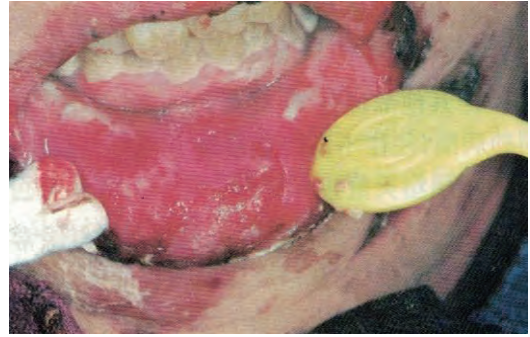重型复发性阿弗他溃疡



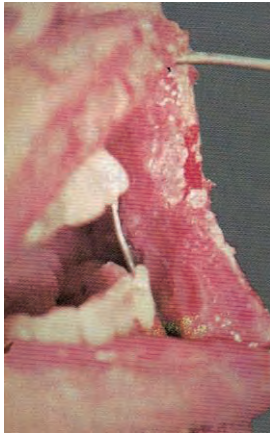疱疹型复发性阿弗他溃疡



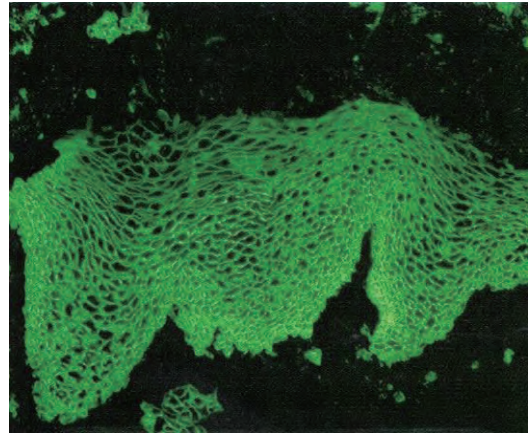
创伤性溃疡



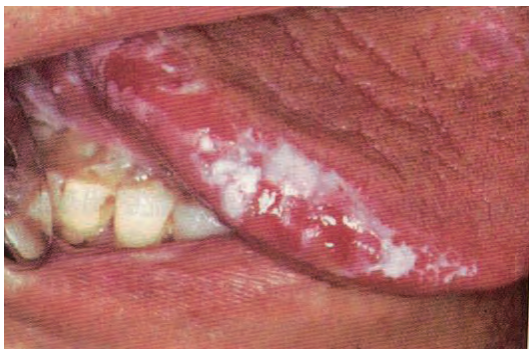寻常型天疱疮



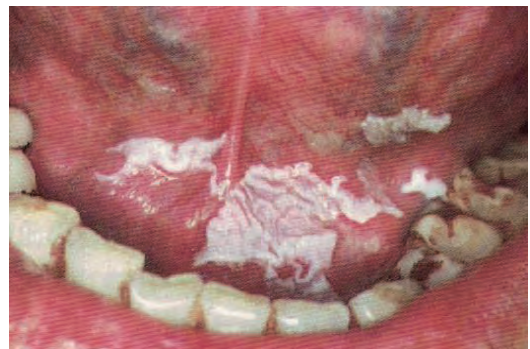寻常型天疱疮



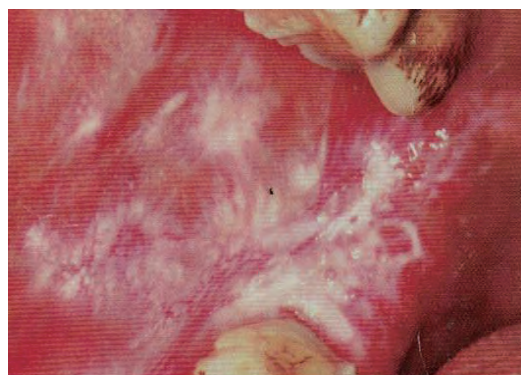
天疱疮免疫荧光图



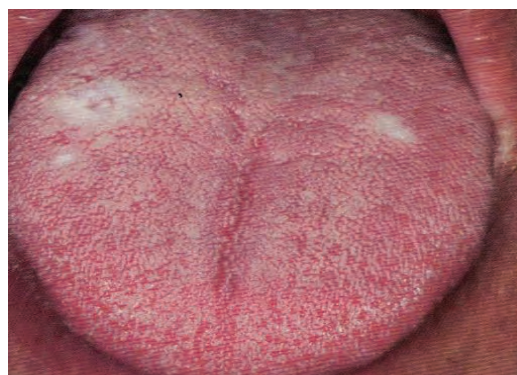白斑 (溃疡型)



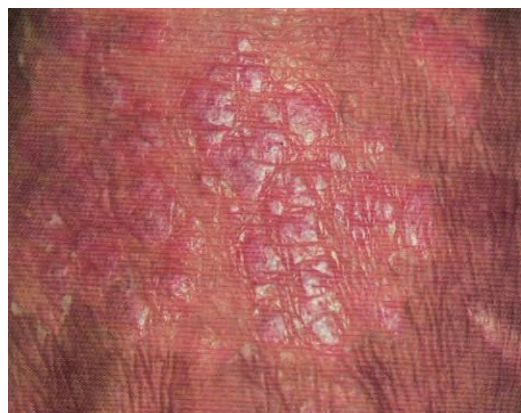
白斑 (皱纸状)



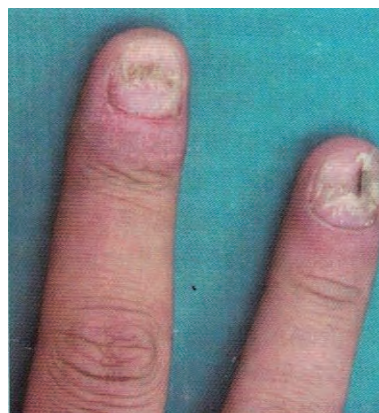扁平苔藓



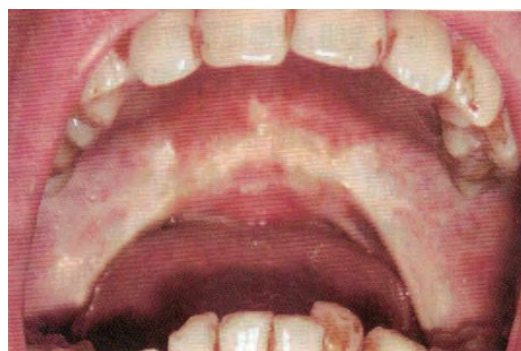扁平苔藓



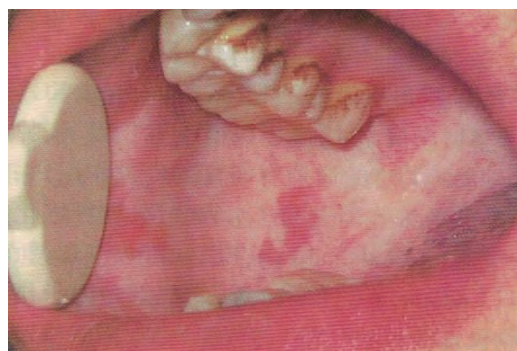扁平苔藓 (皮肤损害)



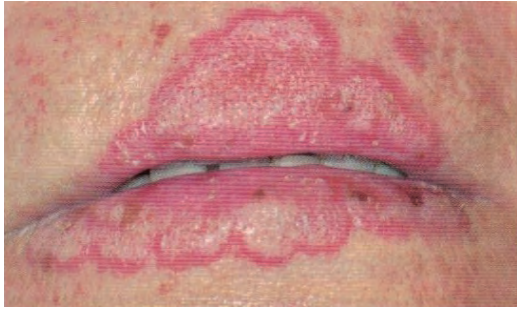扁平苔藓 (指甲损害)



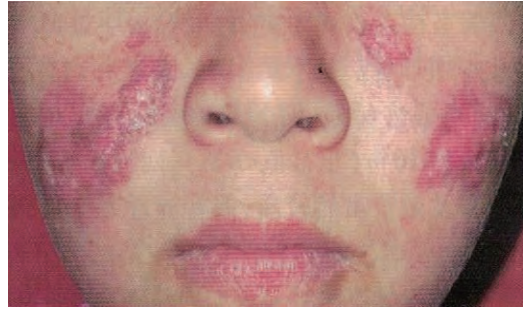口腔黏膜下纤维化 (腭部)



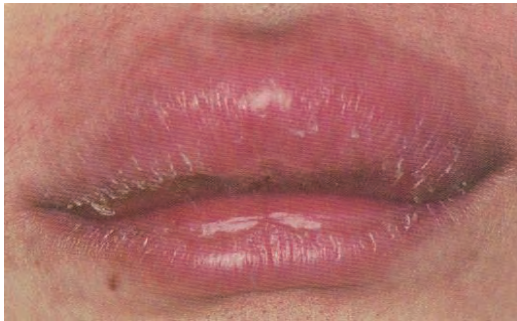口腔黏膜下纤维化 (颊部)



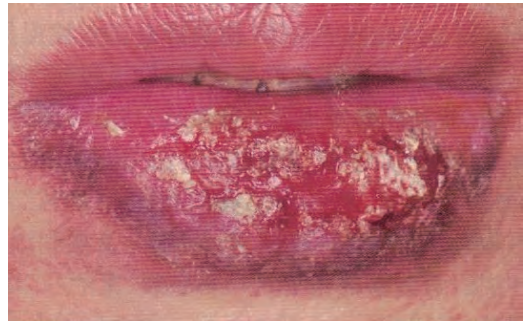盘状红斑狼疮



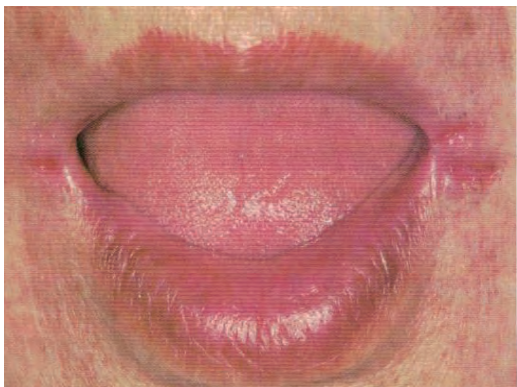盘状红斑狼疮



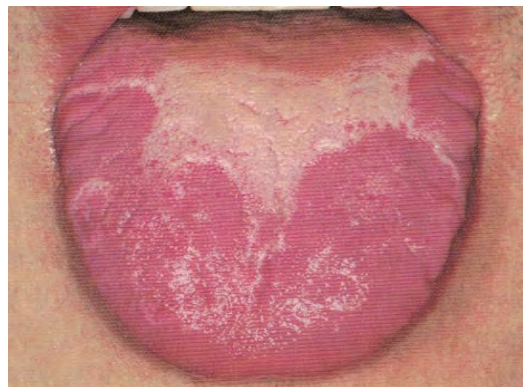
肉芽肿性唇炎



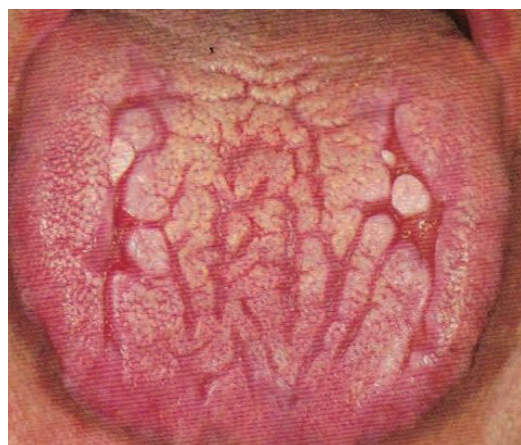
慢性糜烂性唇炎



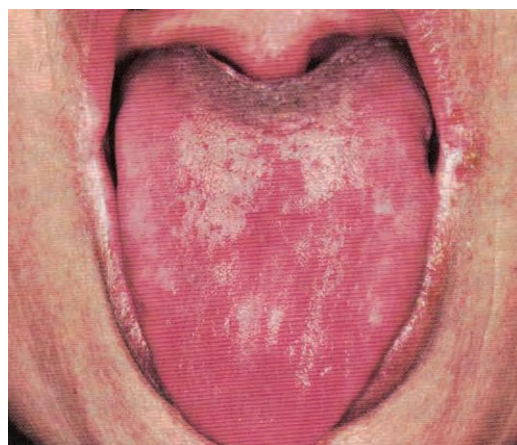
营养不良性口角炎



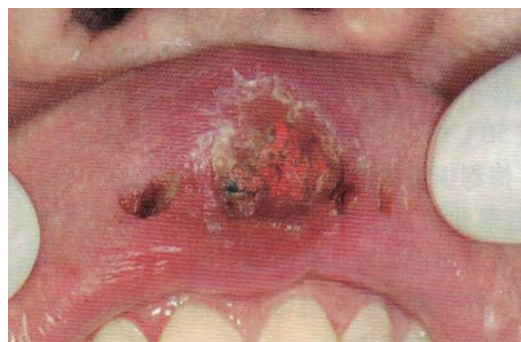地图舌



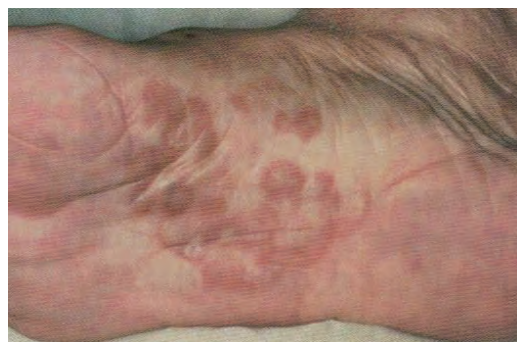沟纹舌



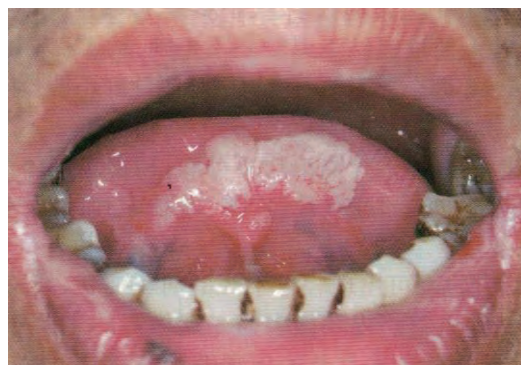萎缩性舌炎



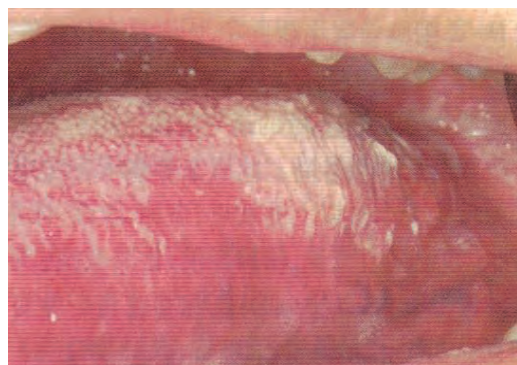
唇硬下疳



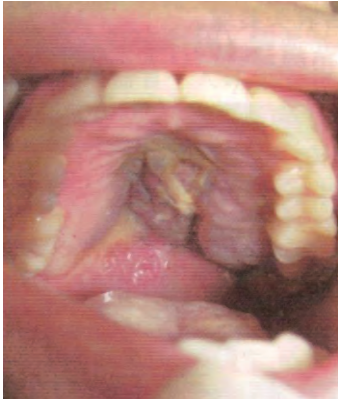梅毒疹



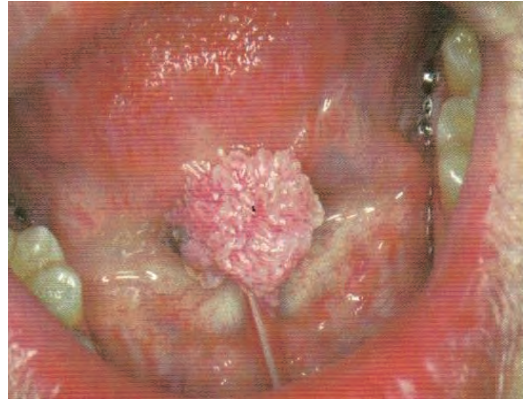
黏膜斑



毛状白斑

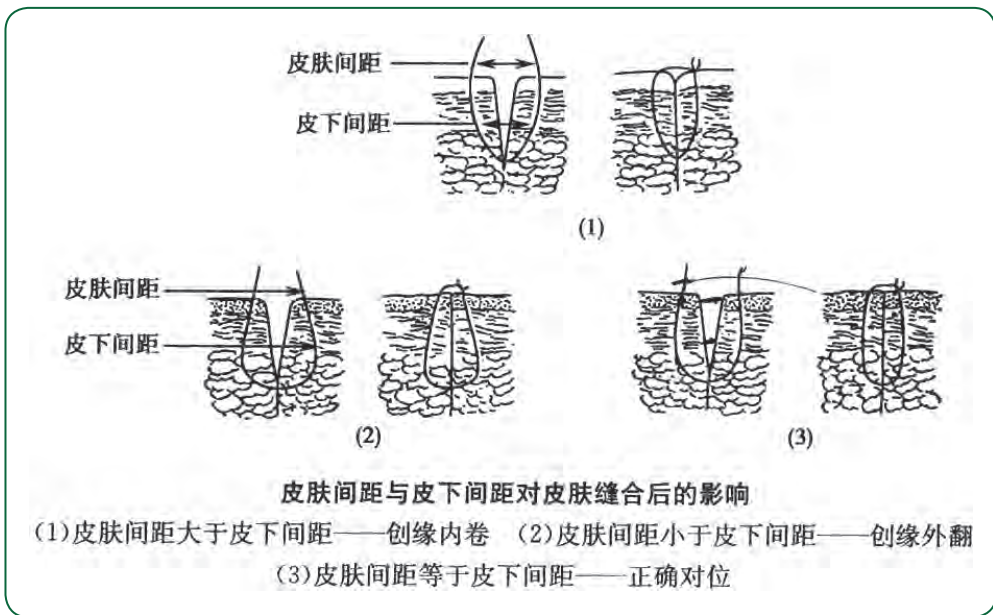
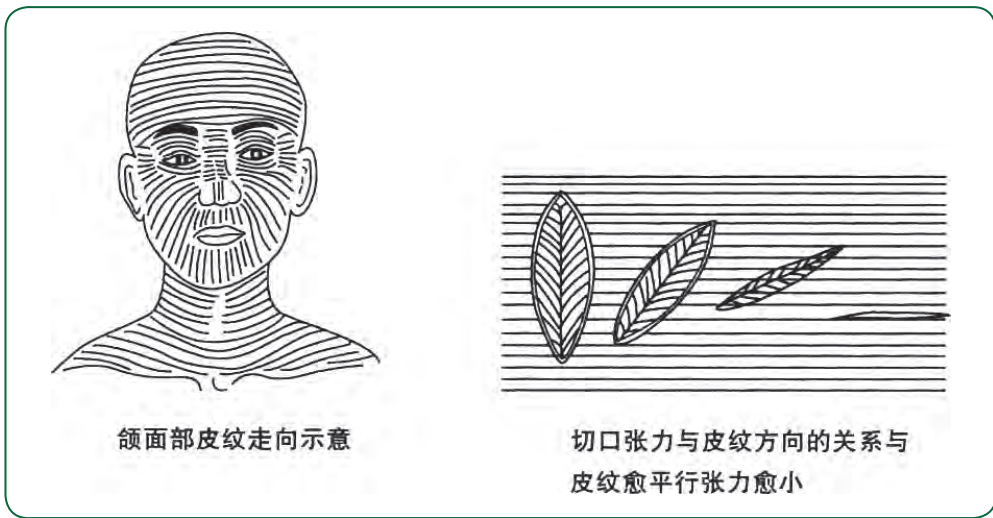
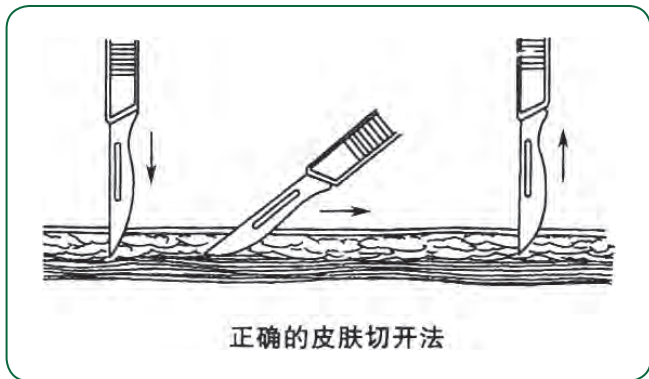
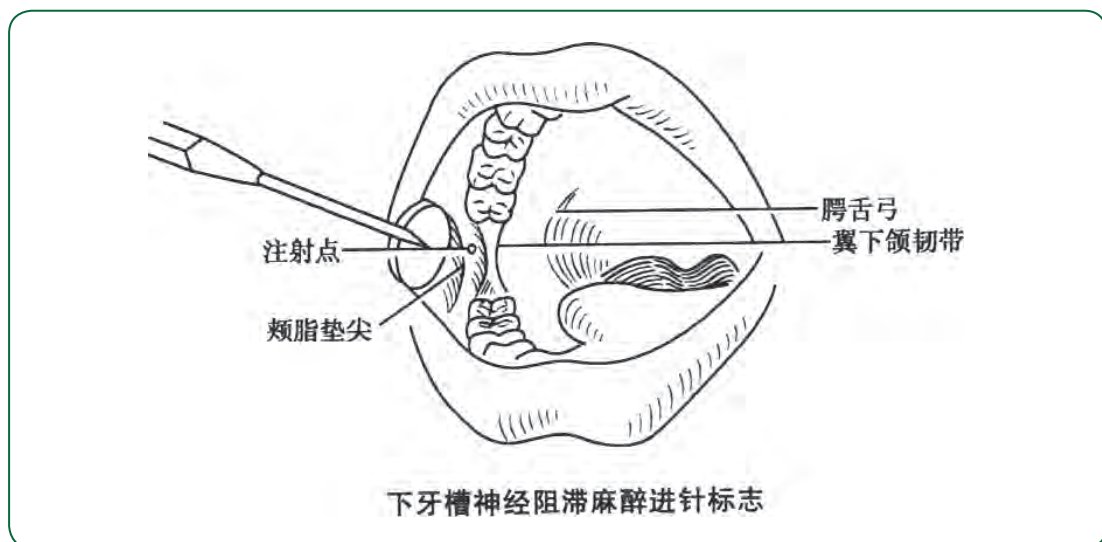
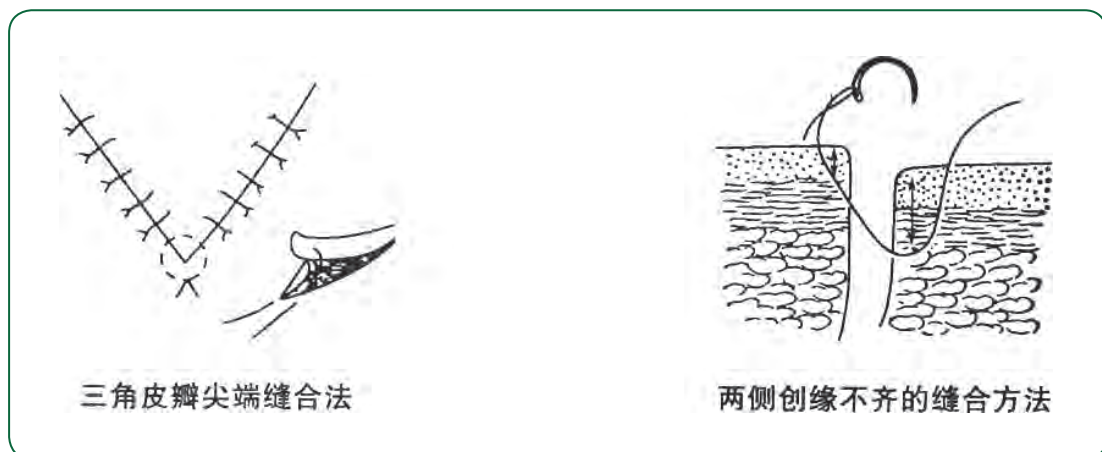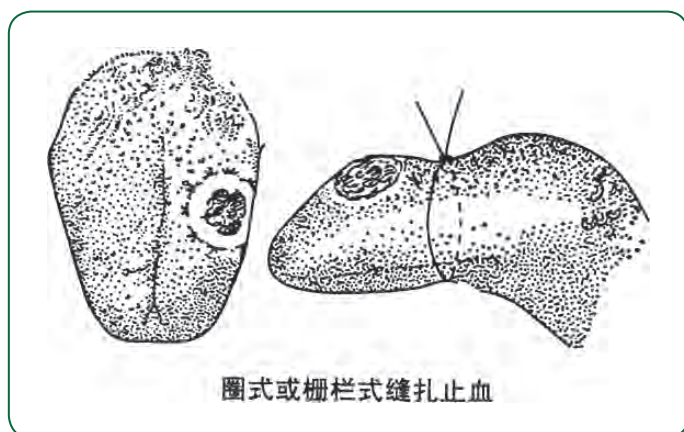
卡波西肉瘤

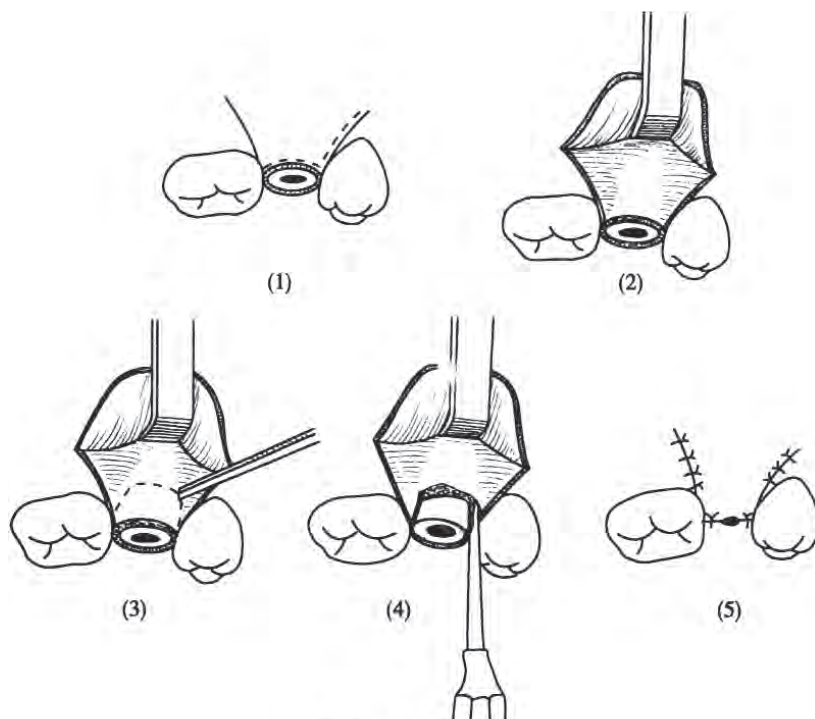


尖锐湿疣

口腔颌面外科学

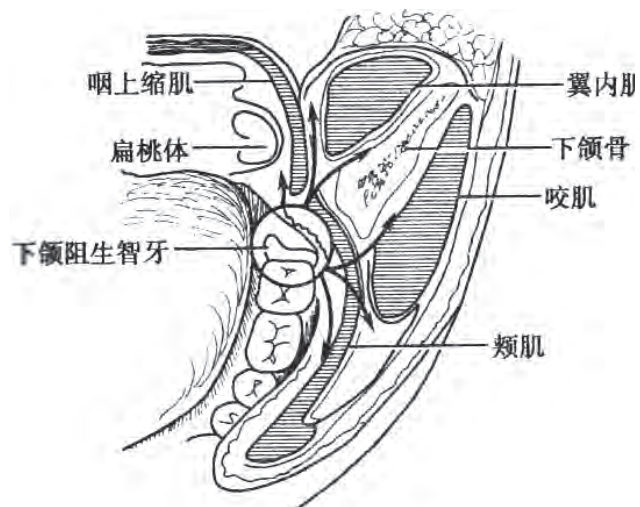




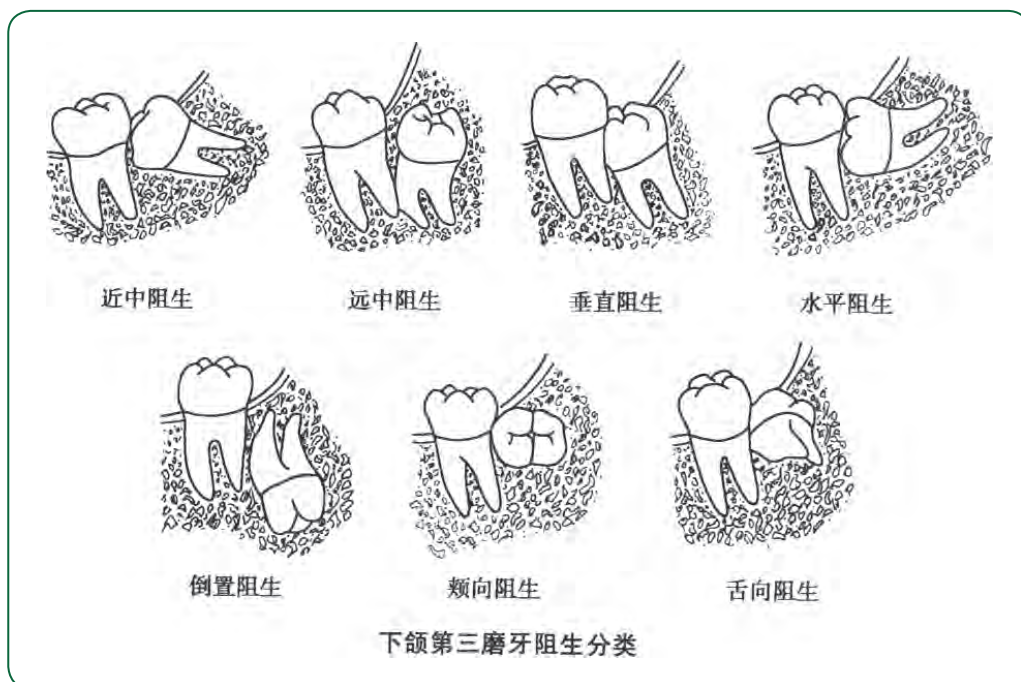
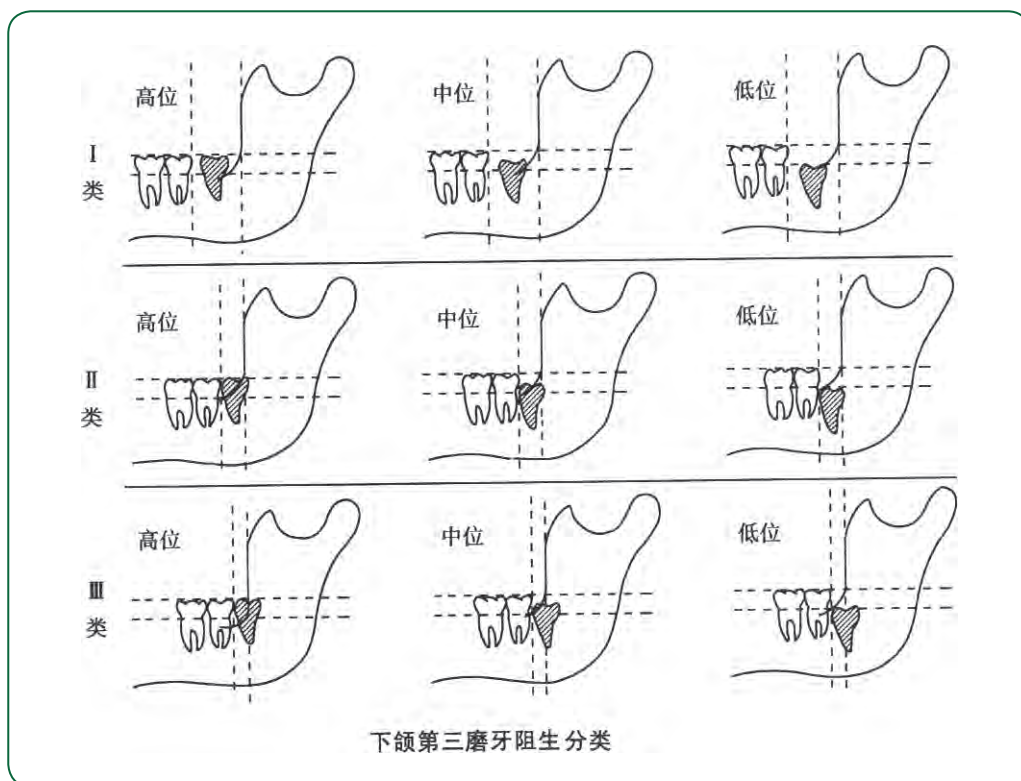


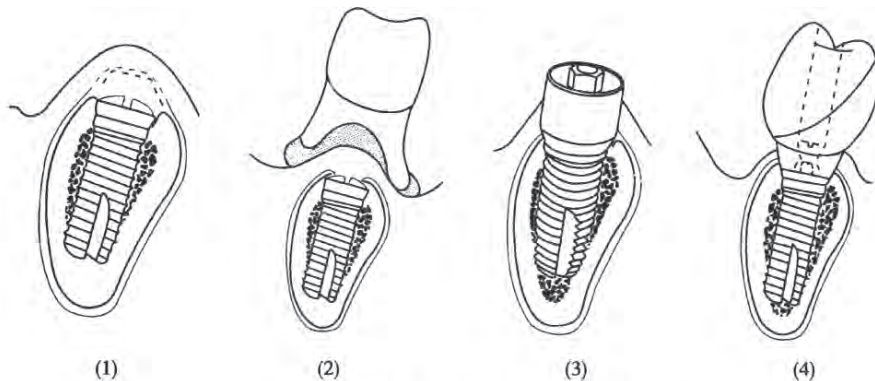
翻瓣去骨牙根拔除术

(1)切口(虚线为角形切口) (2)翻瓣 (3)凿骨 (4)挺出牙根 (5)缝合



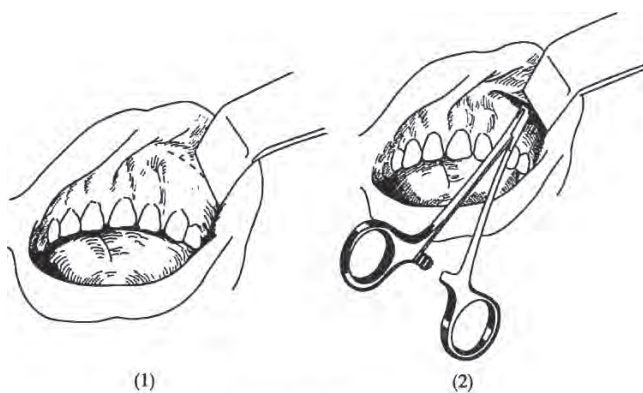
智牙冠周炎感染扩散途径



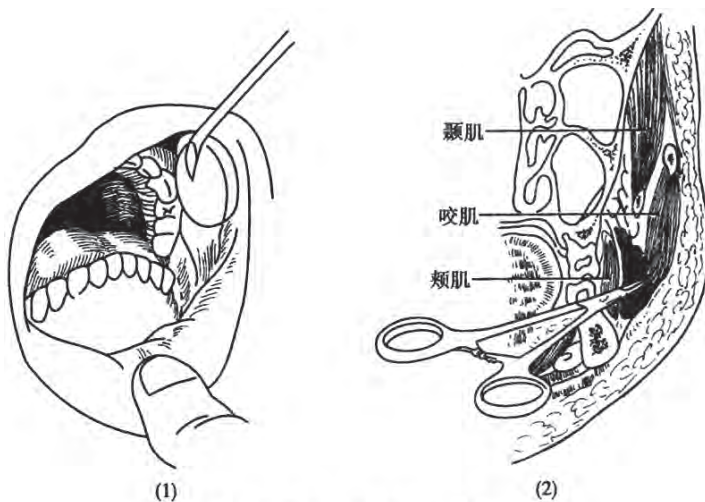


两段式种植义齿修复的治疗程序

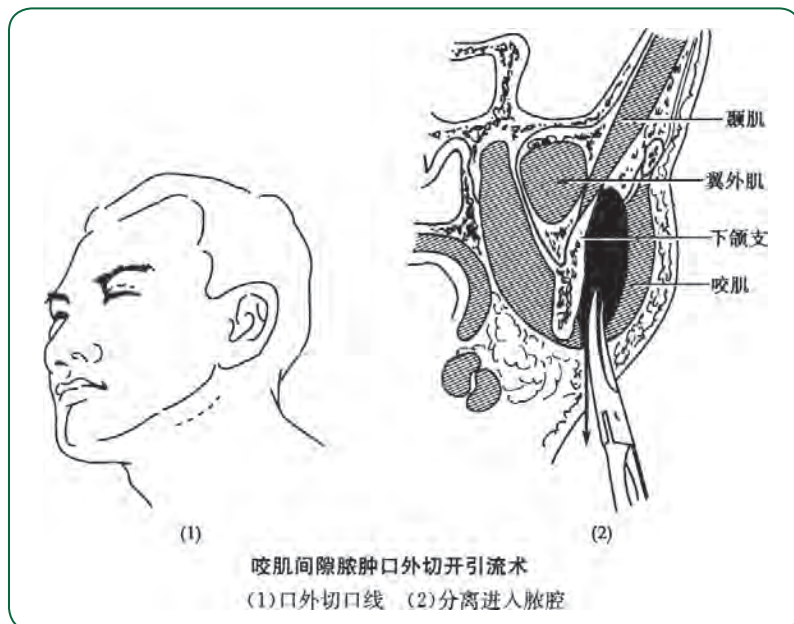
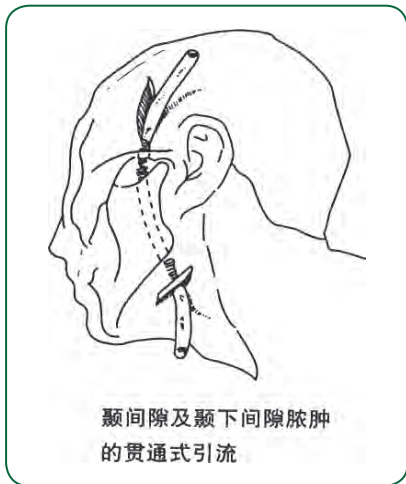
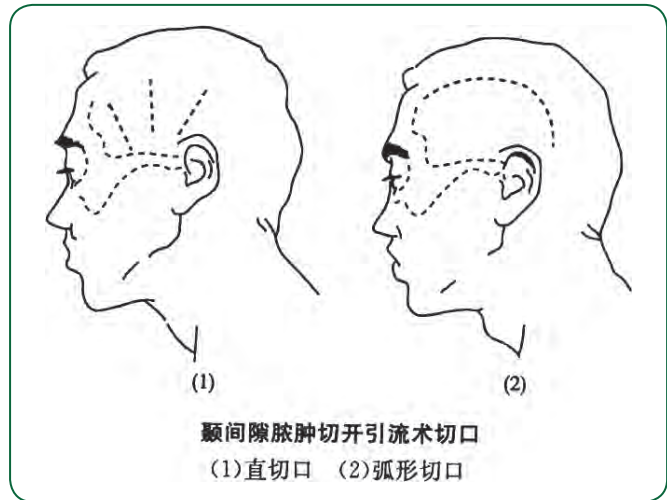
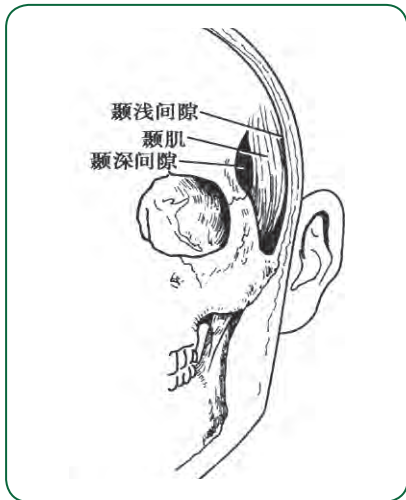
(1)第一期种植体植入术后 (2)第一期术后的骨愈合期 (3)第二期基台连接术后 (4)完成种植义齿修复

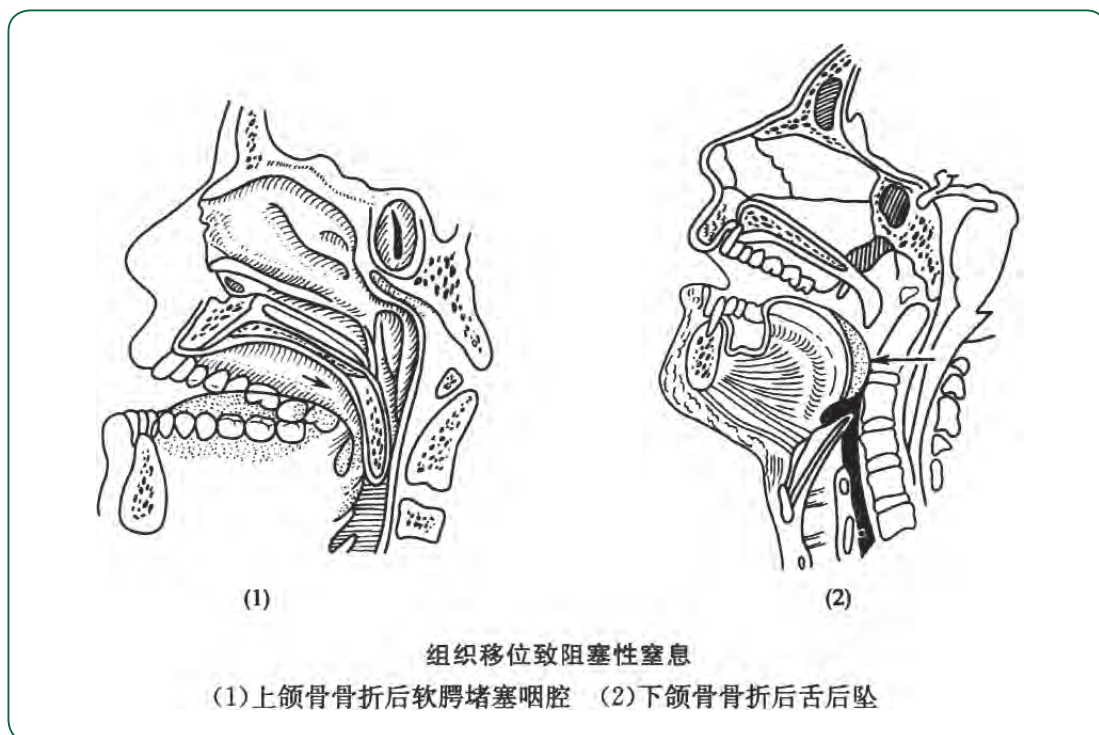
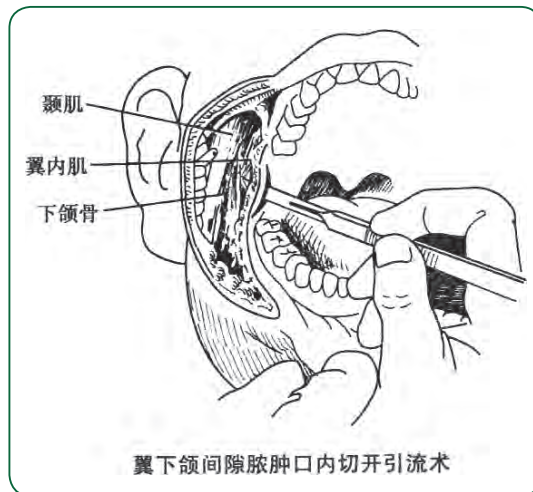
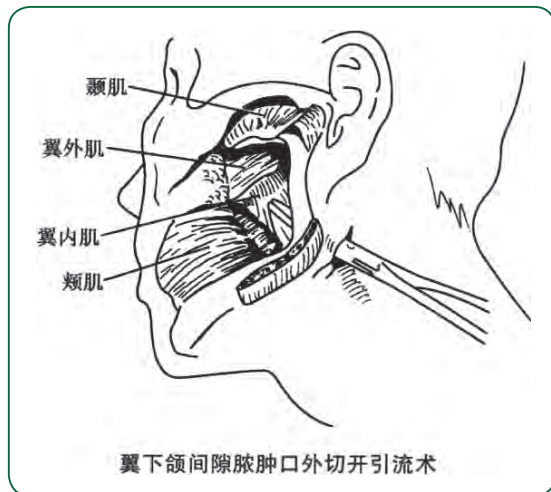


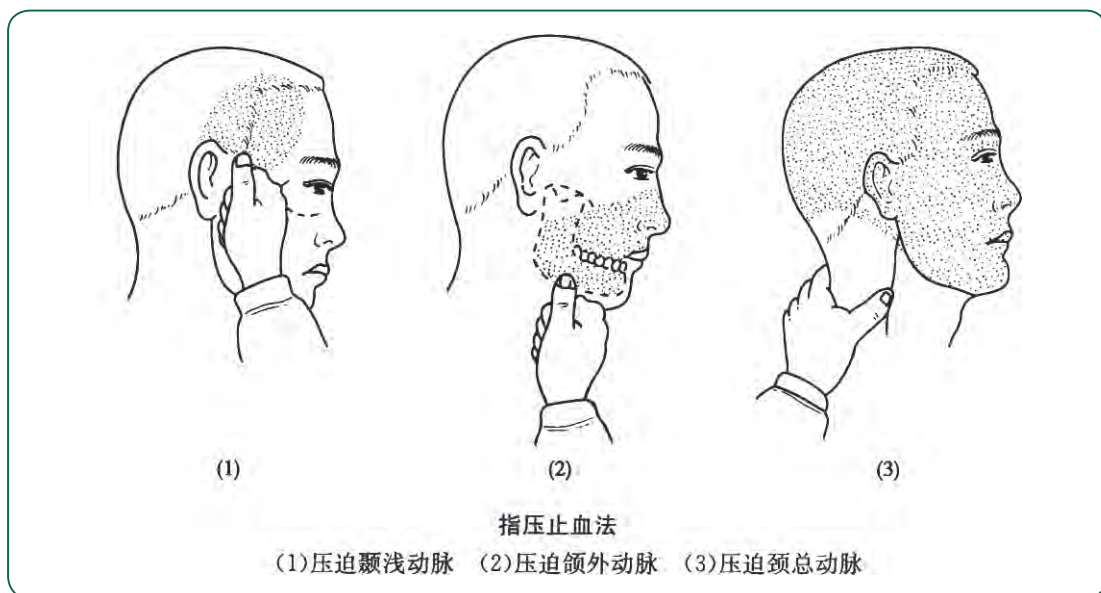
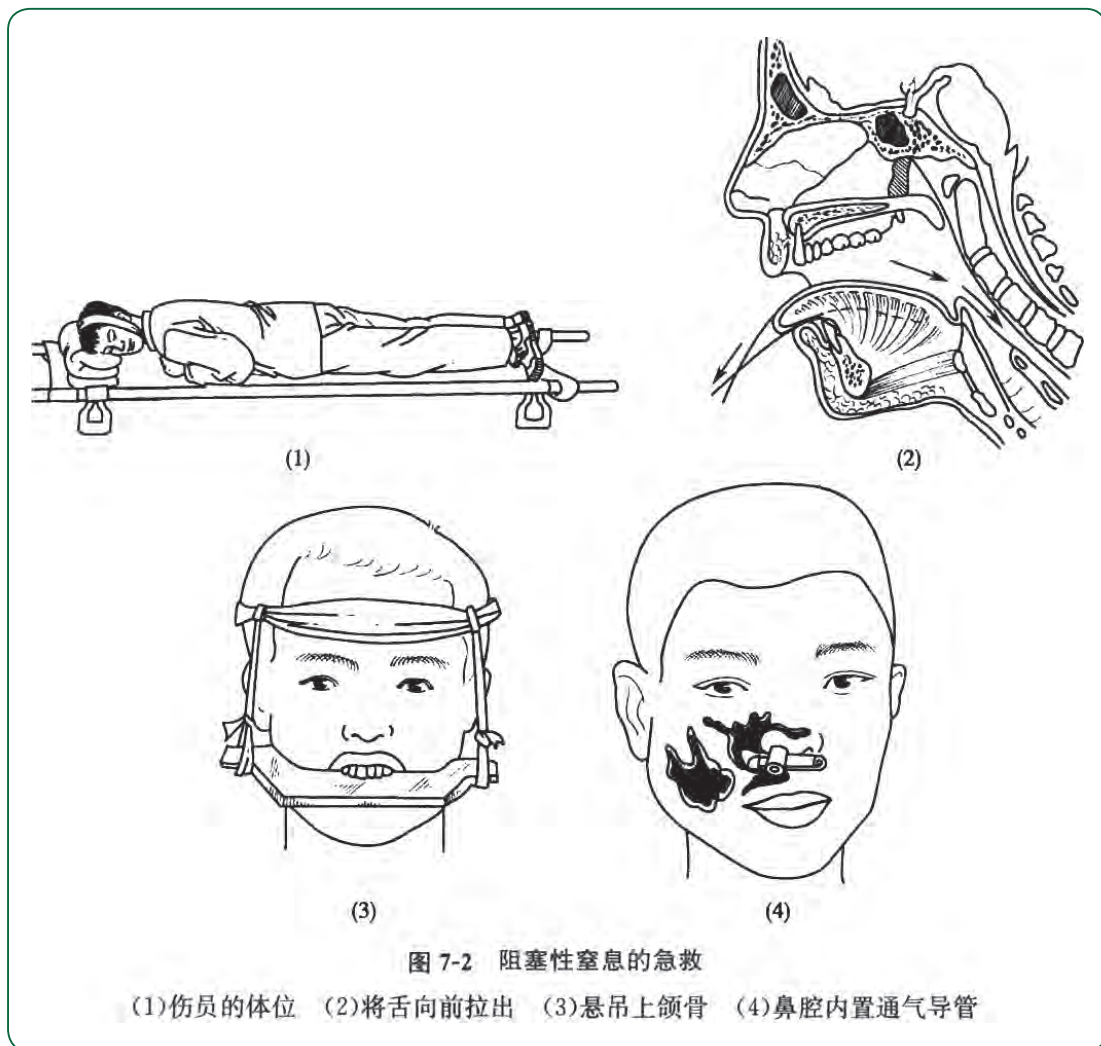
眶下间隙脓肿切开引流术
(1)口内切口线 (2)分离脓腔

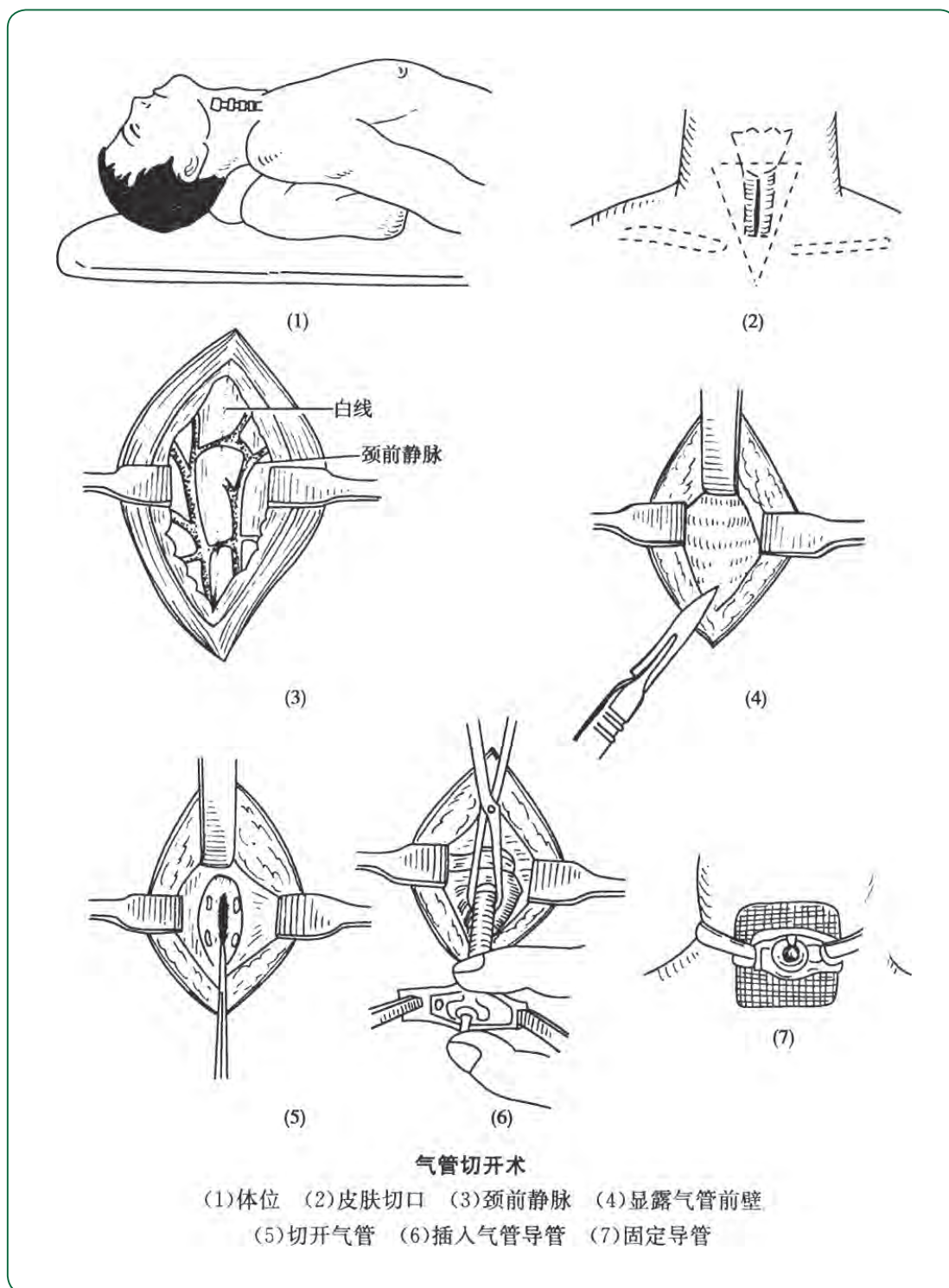


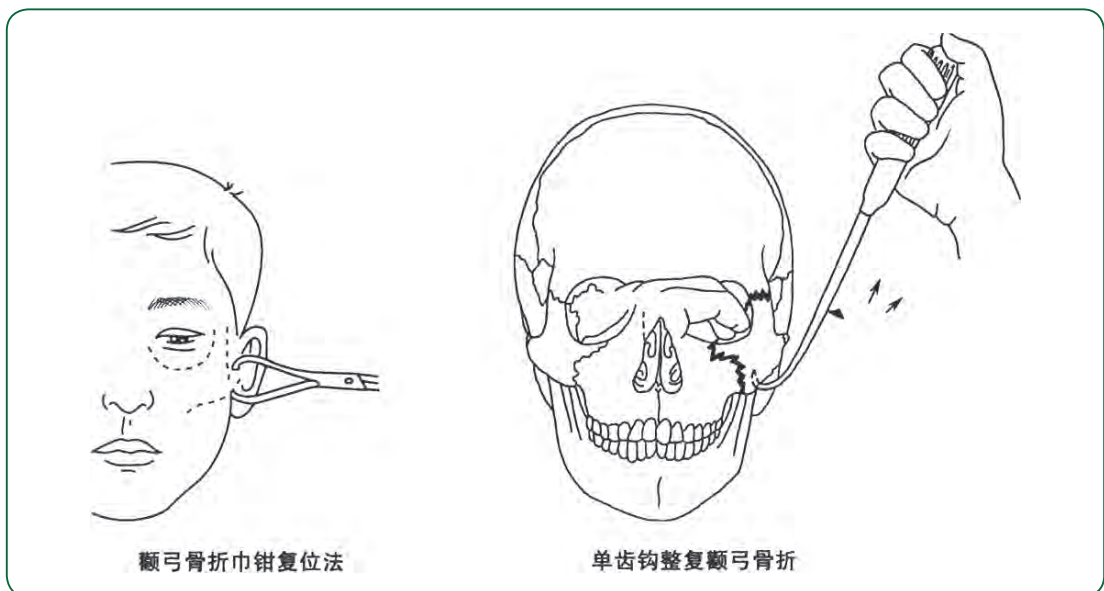
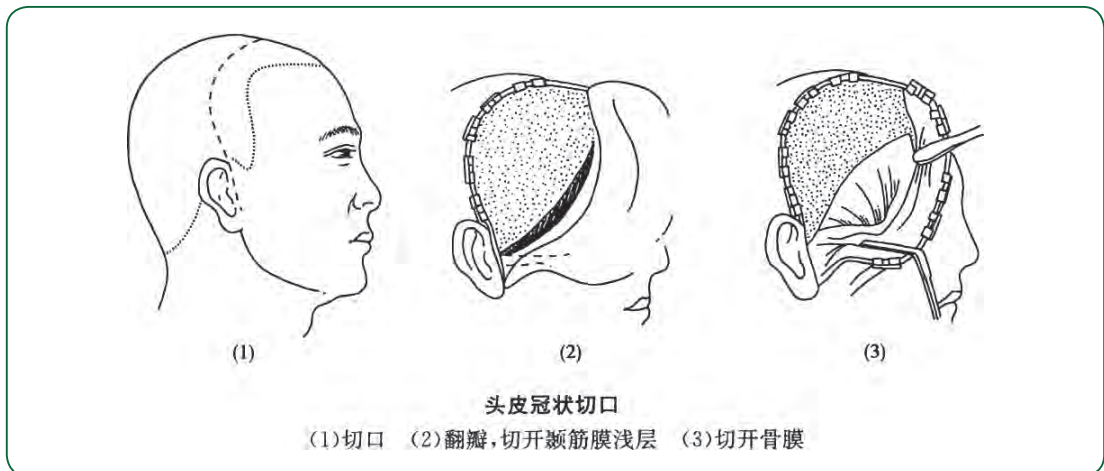
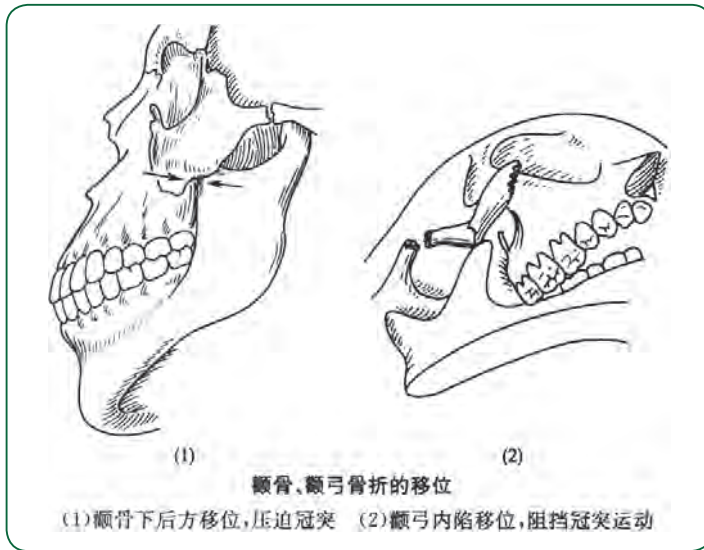
颊间隙脓肿口内切开引流术
(1)口内切口线 (2)分离脓腔

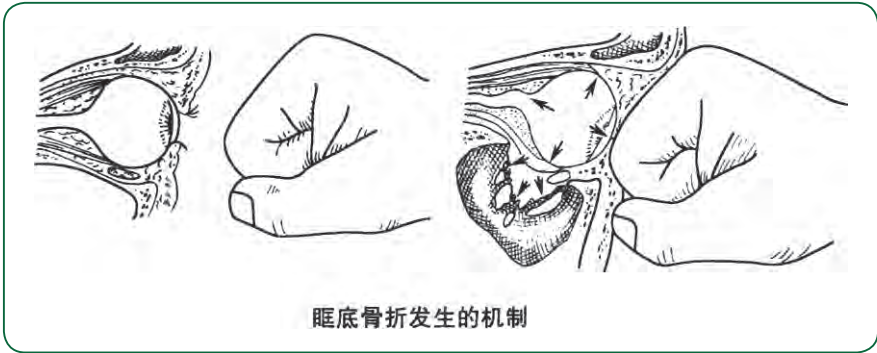




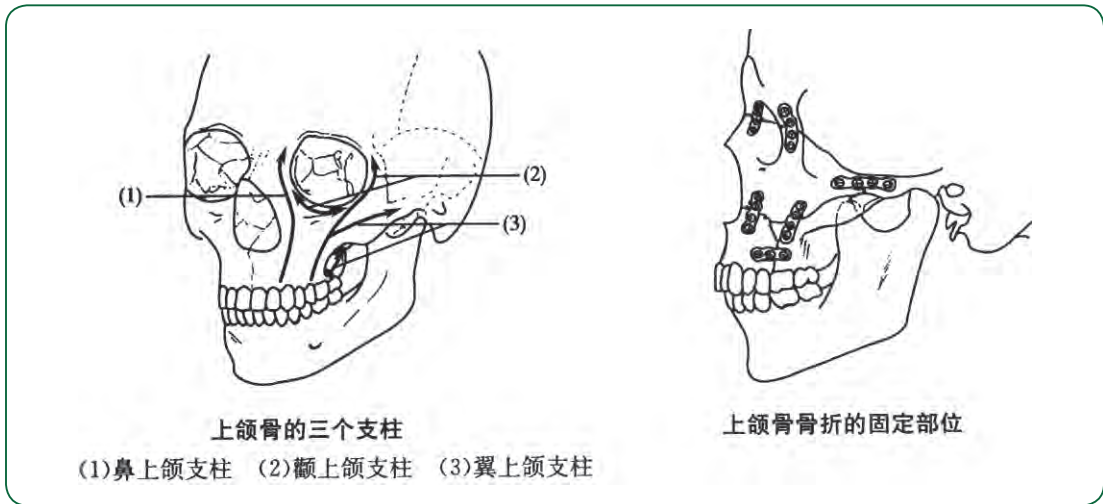








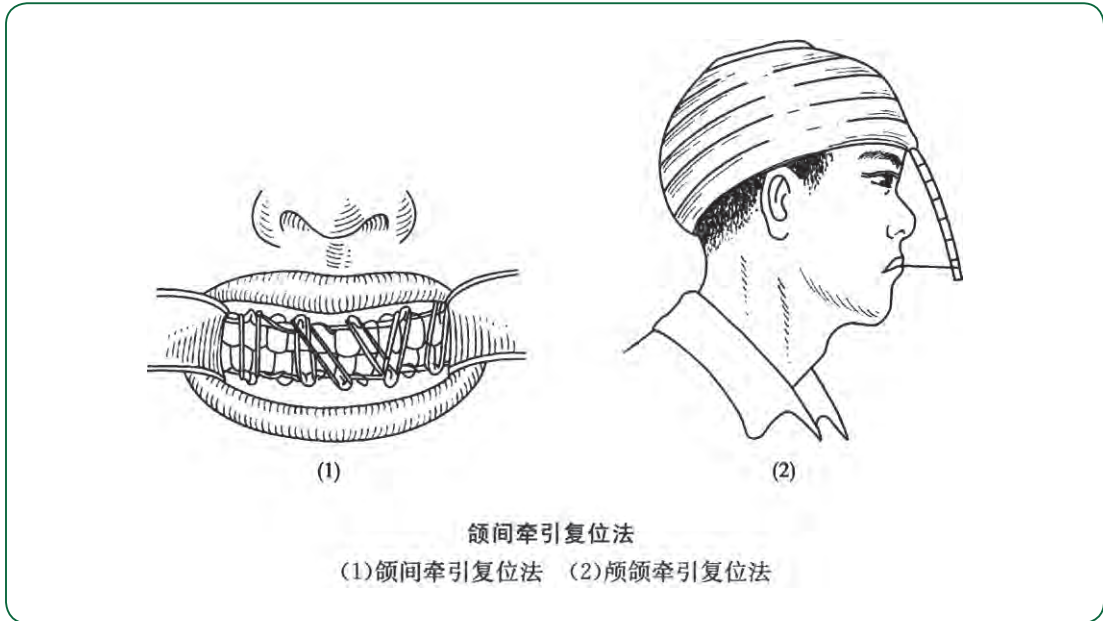
眶底骨折发生的机制



上颌骨三个支柱

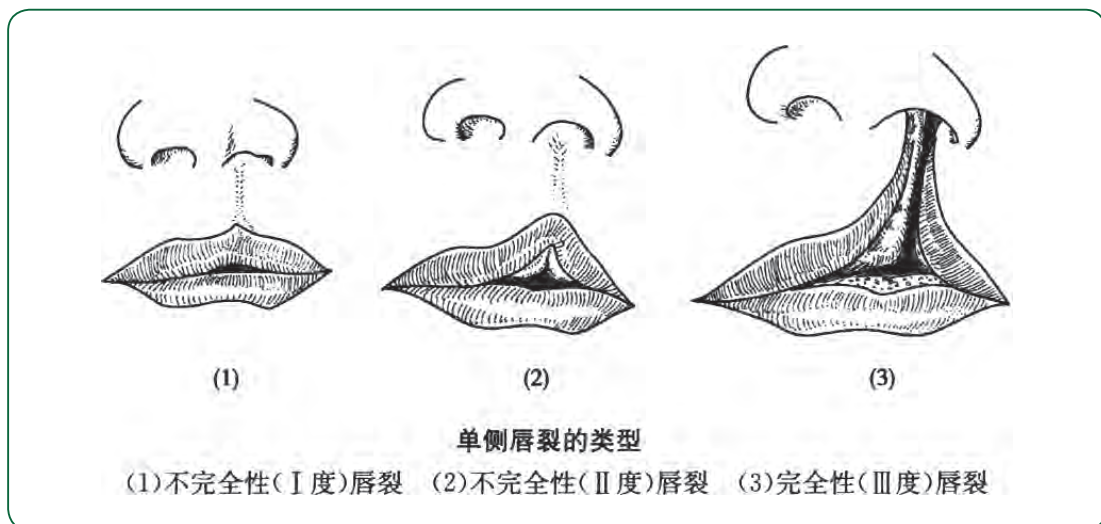
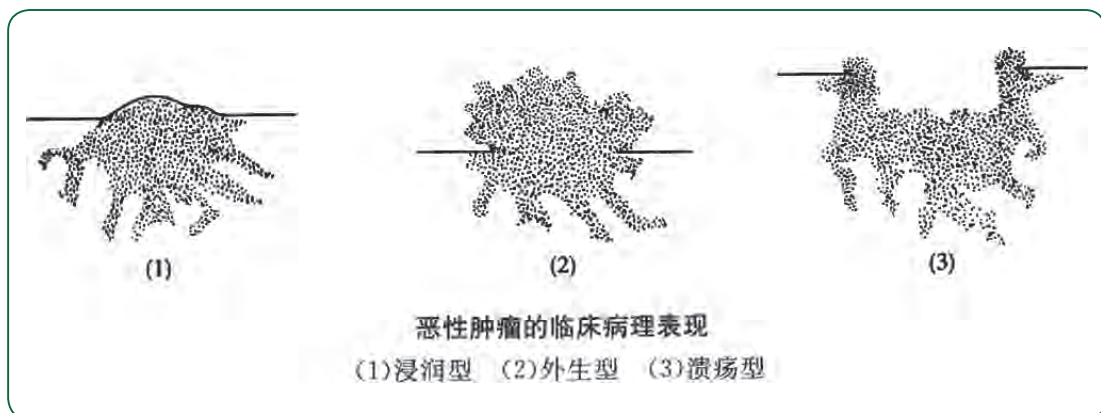
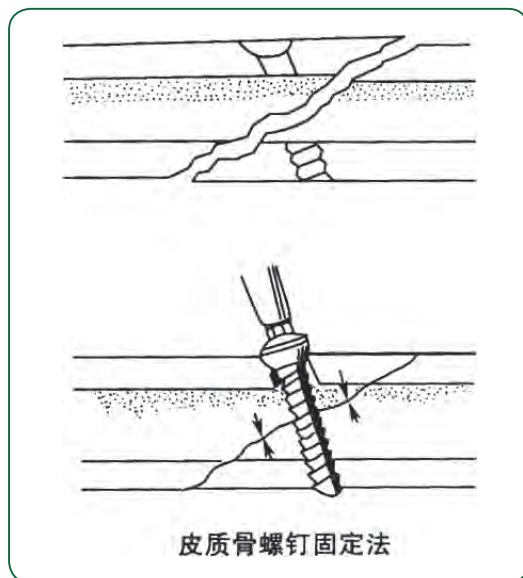
(1)鼻上颌支柱 (2)颧上颌支柱 (3)翼上颌支柱

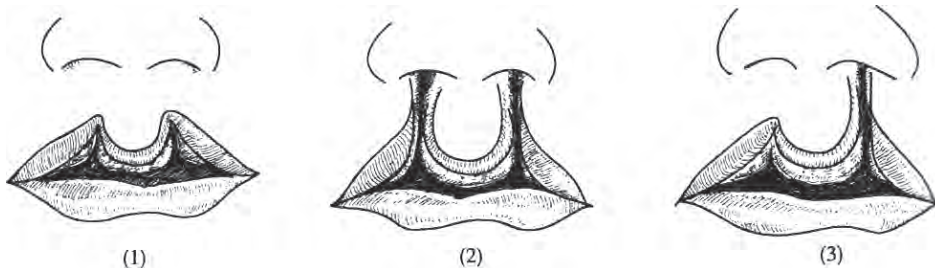
上颌骨骨折的固定部位



颌间牵引复位法

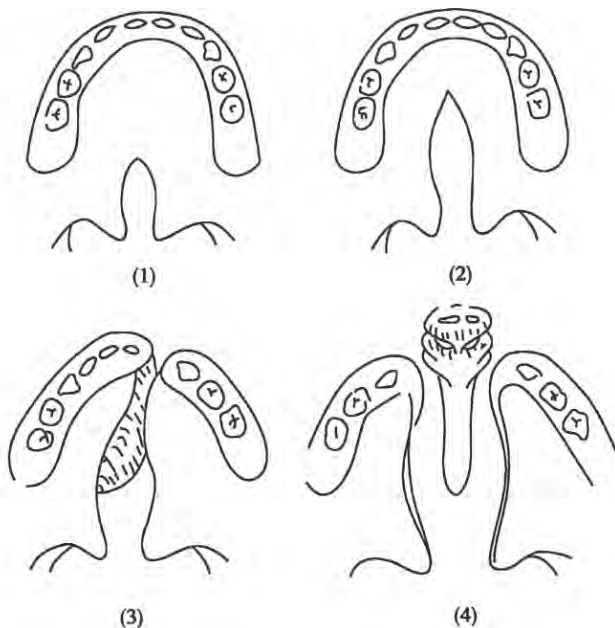
(1)颌间牵引复位法 (2)颅颌牵引复位法





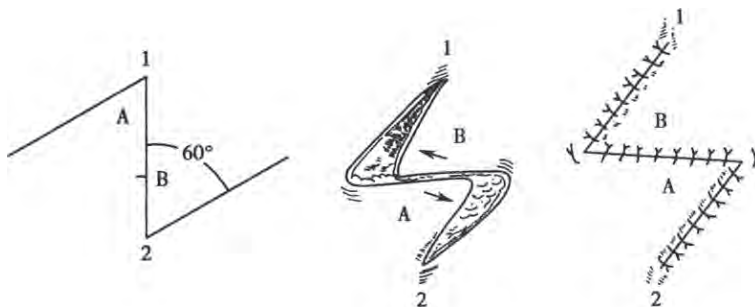
双侧唇裂的类型

- (1) 双侧不完全性(双侧Ⅱ度)唇裂 (2) 双侧完全性(双侧Ⅲ度)唇裂
 (3) 双侧混合性(左侧Ⅲ度, 右侧Ⅱ度)唇裂

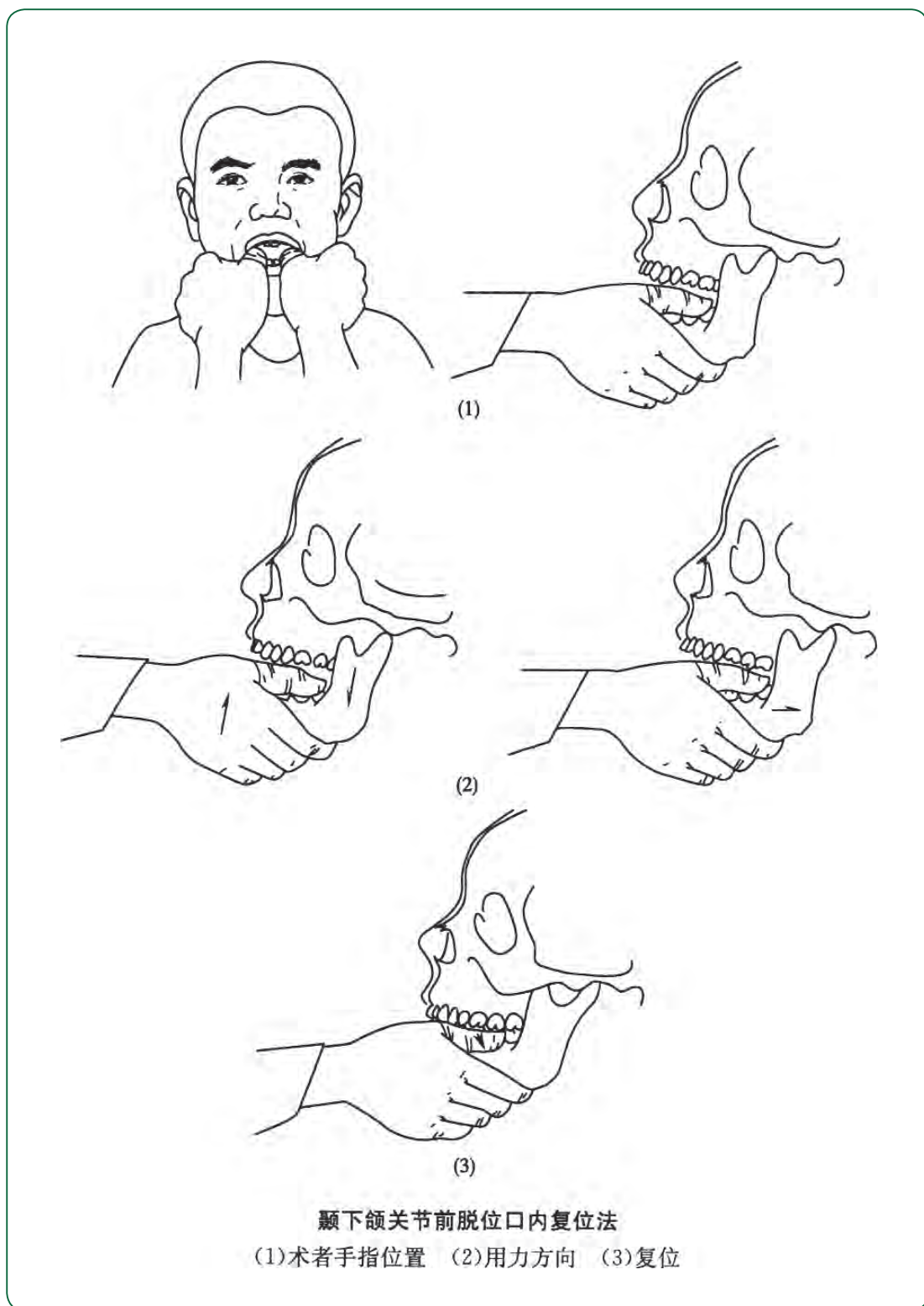


腭裂的临床分类

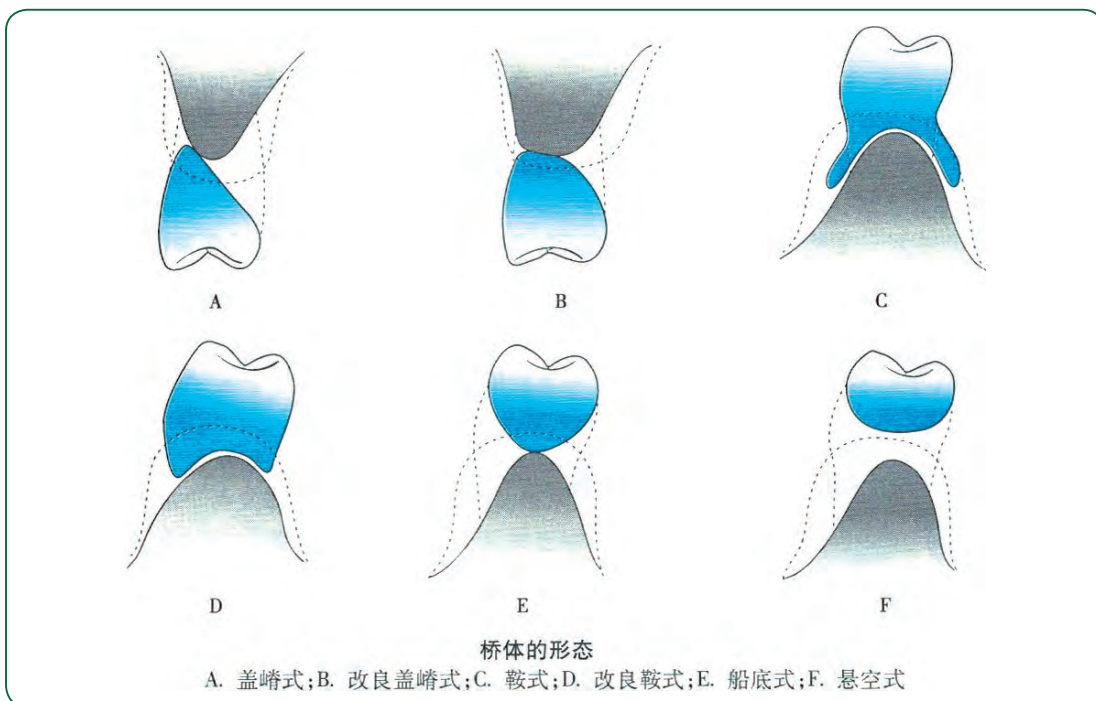
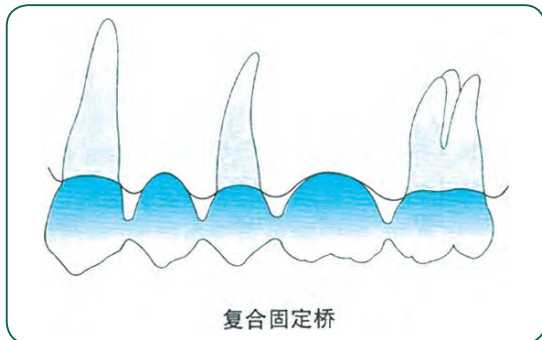
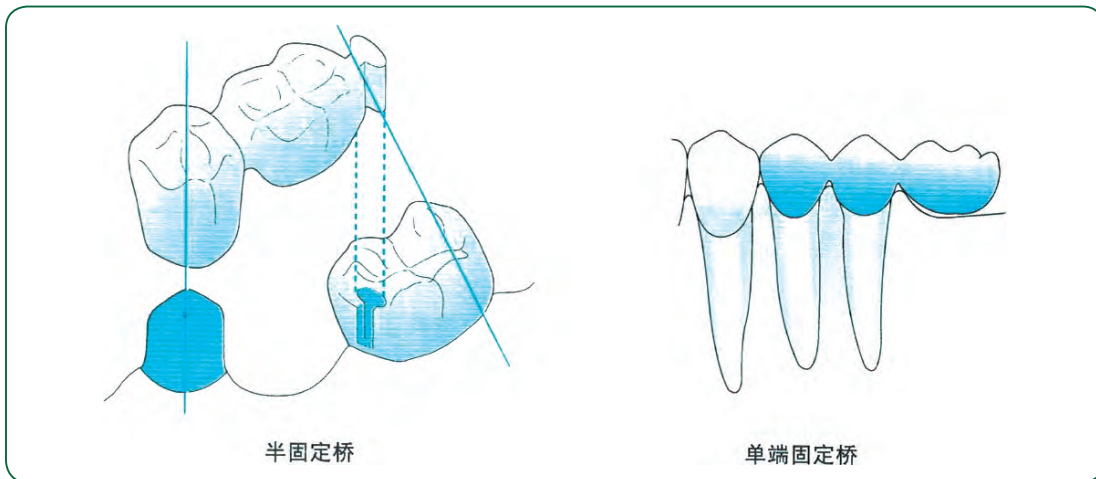
- (1) 软腭裂 (2) 不完全腭裂 (3) 单侧完全性腭裂 (4) 双侧完全性腭裂

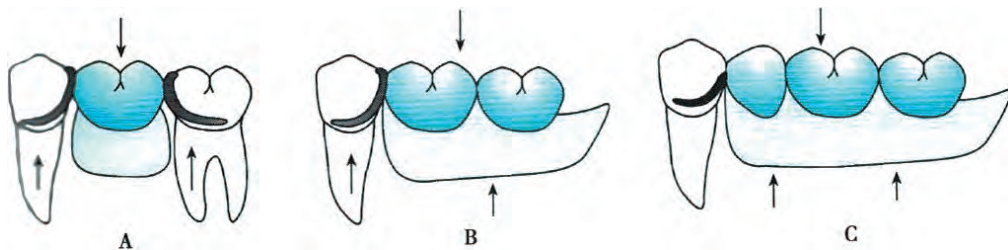


Z成形术示意



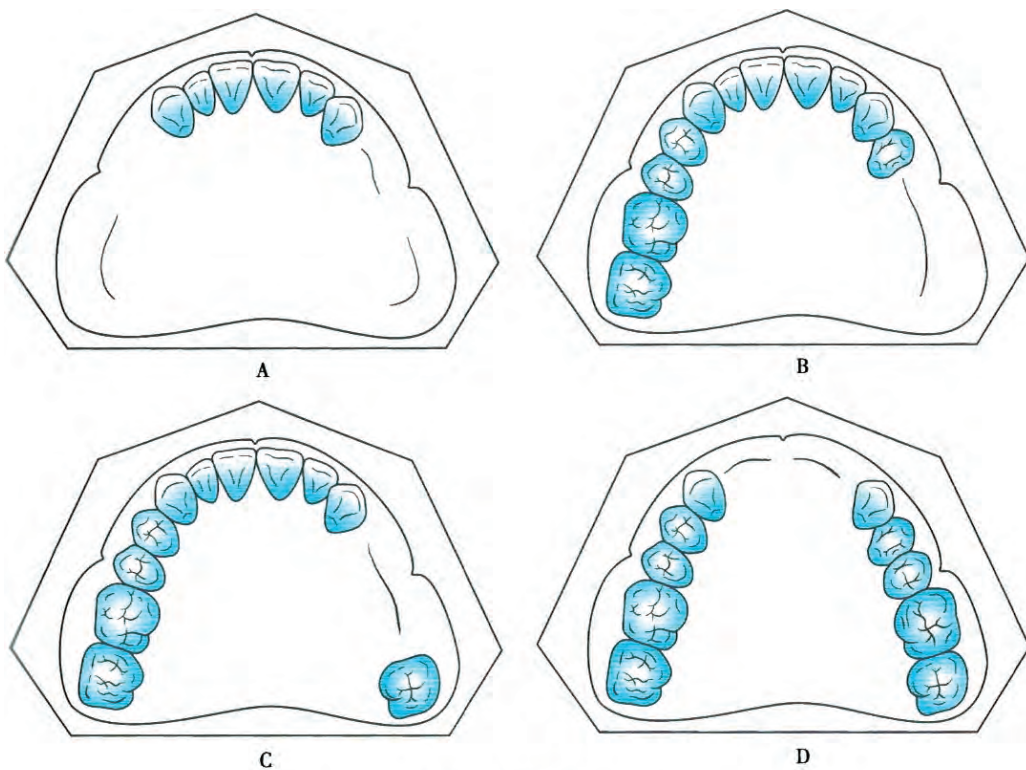
口腔修复学





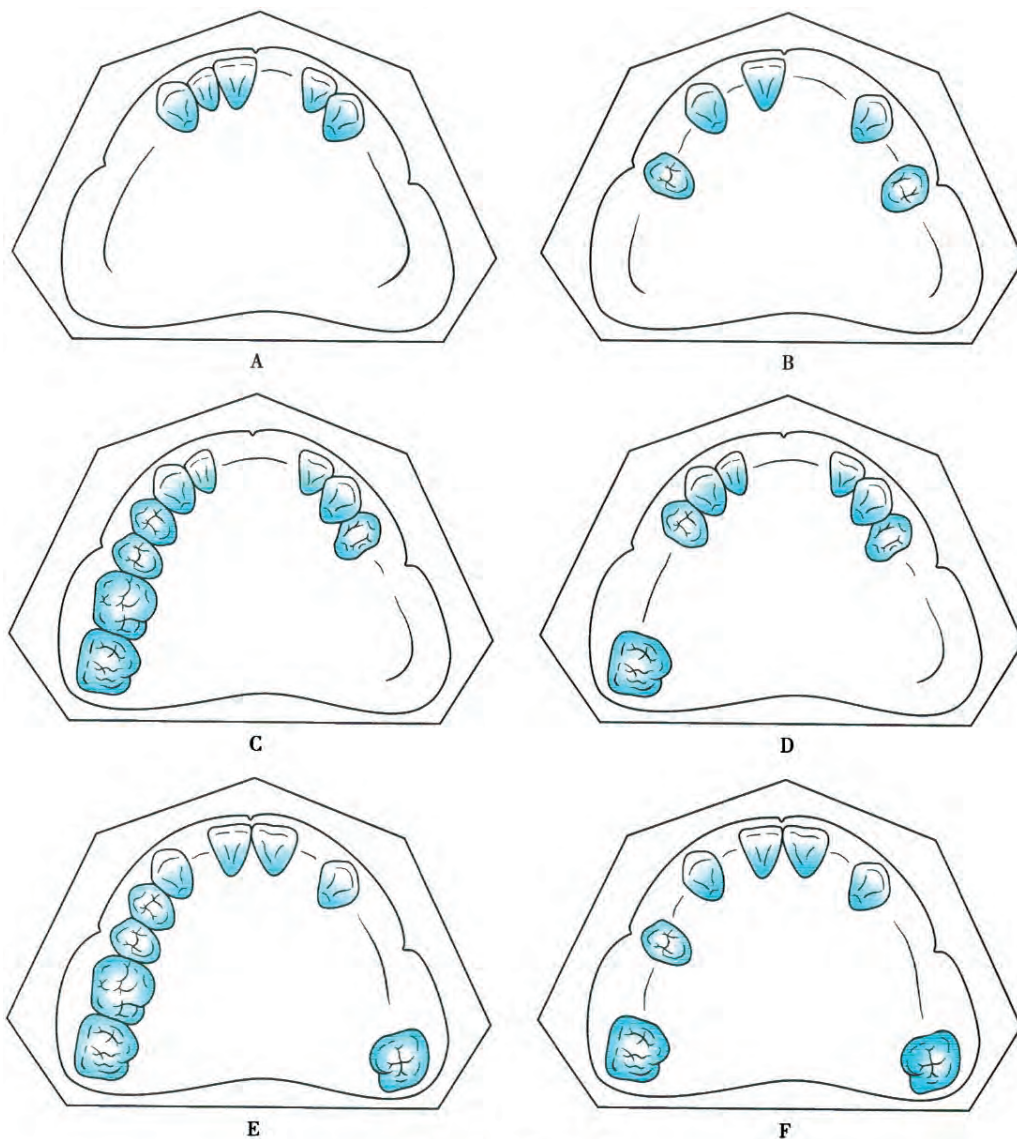
可摘局部义齿的支持方式

A. 牙支持式; B. 混合支持式; C. 黏膜支持式



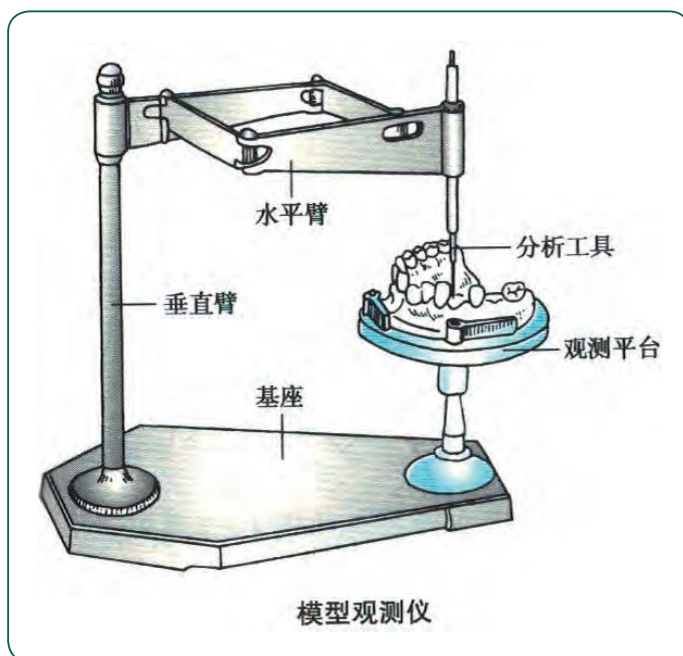
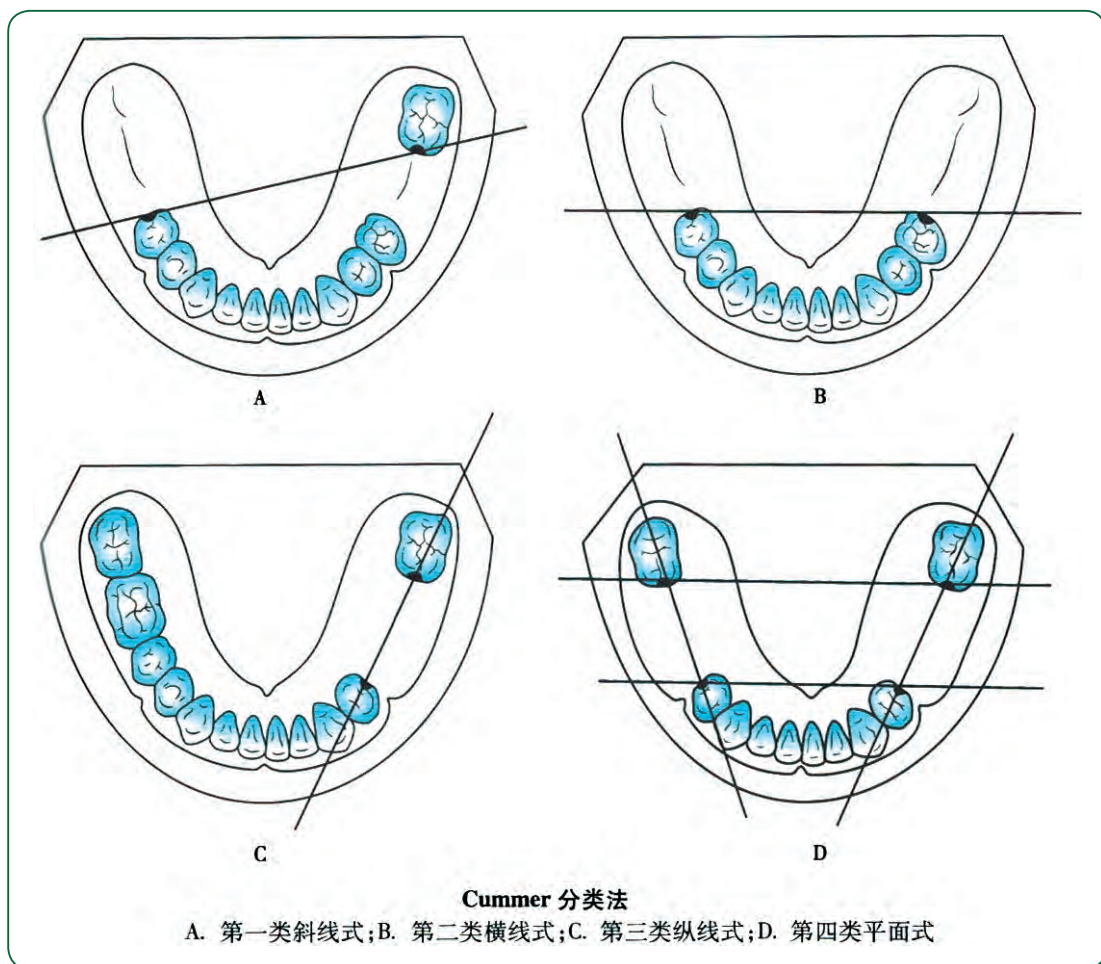
Kennedy 分类法

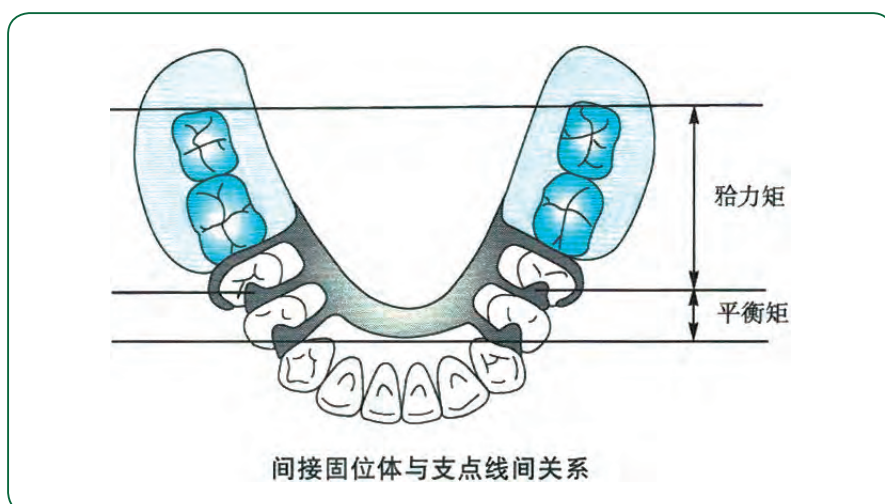
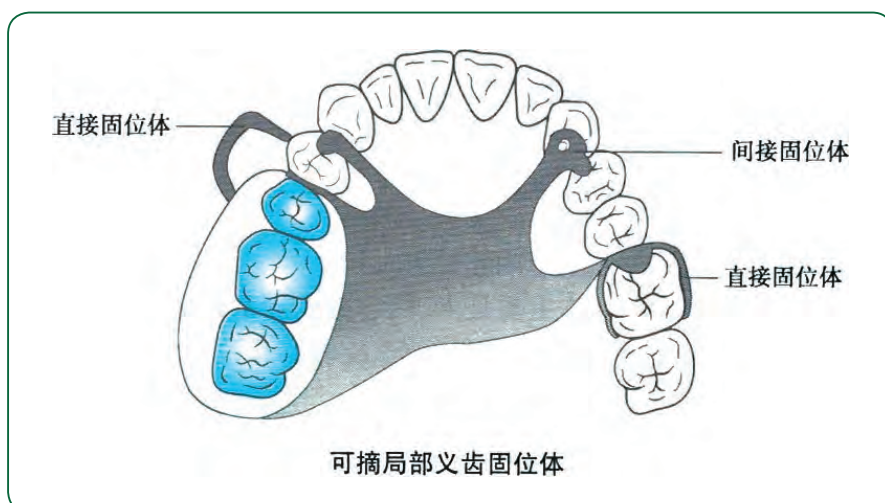
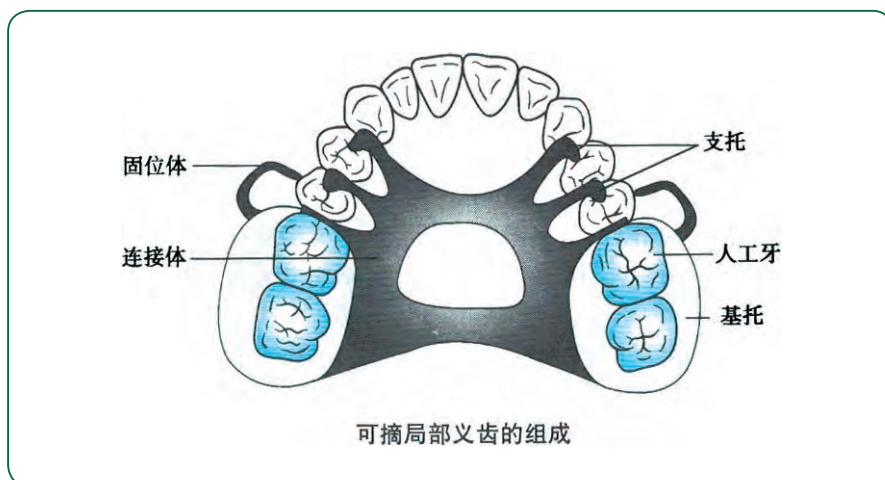
A. Kennedy 第一类; B. Kennedy 第二类; C. Kennedy 第三类; D. Kennedy 第四类

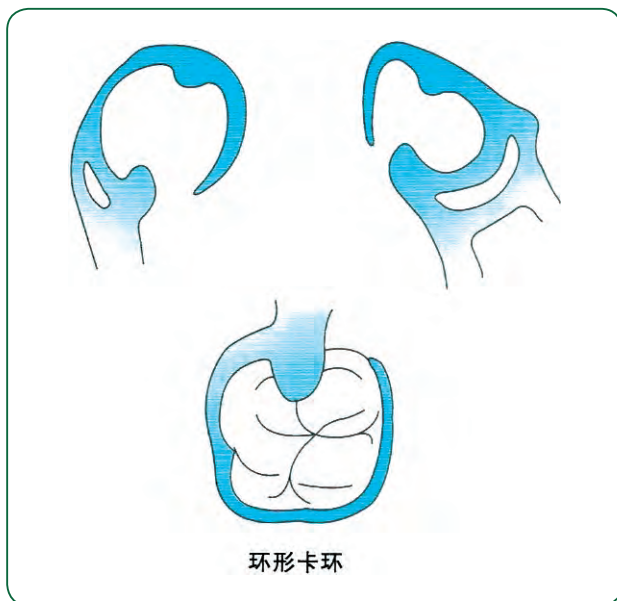


Kennedy 分类的亚类

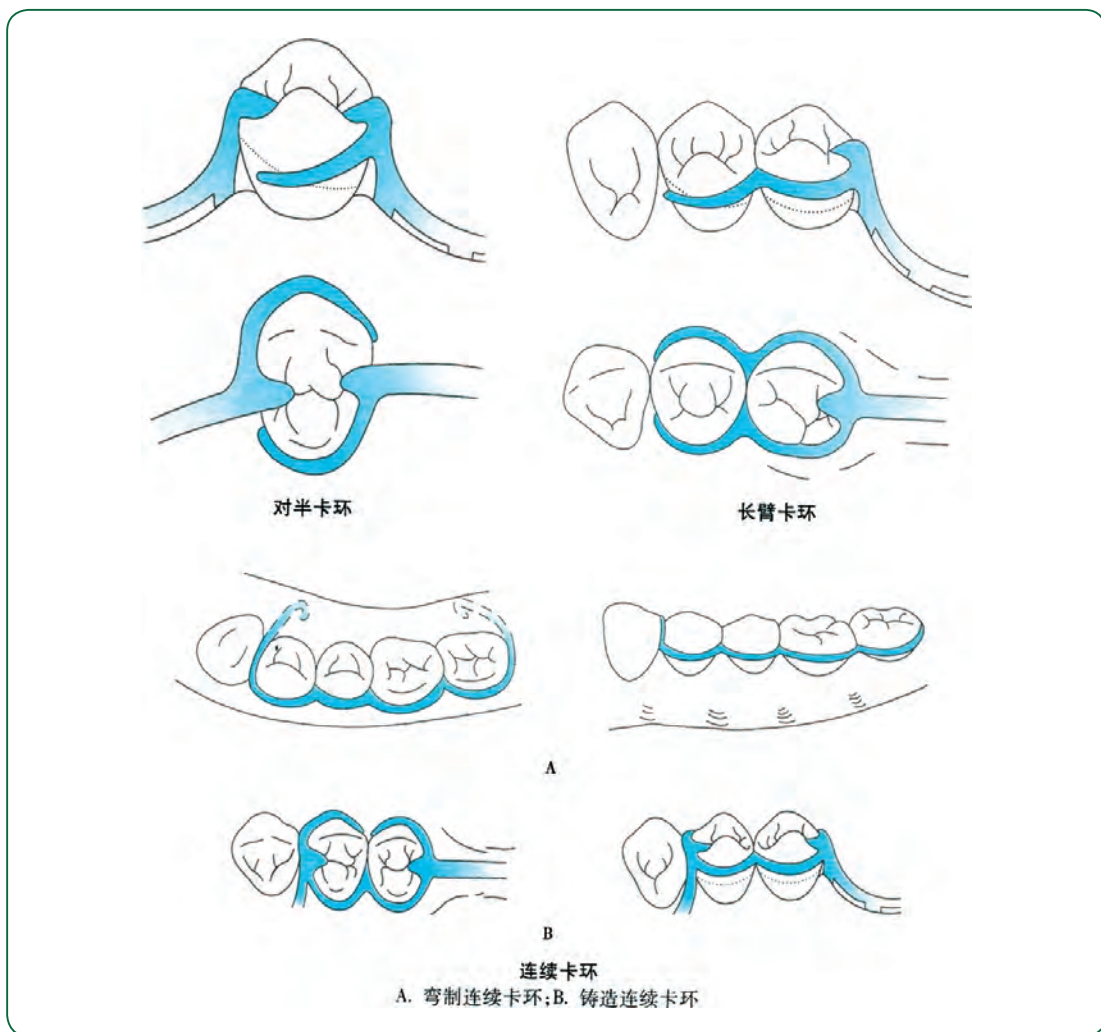
A. Kennedy 第一类第一亚类; B. Kennedy 第一类第四亚类; C. Kennedy 第二类第一亚类; D. Kennedy 第二类第二亚类; E. Kennedy 第三类第二亚类; F. Kennedy 第三类第四亚类







环形卡环



对半卡环

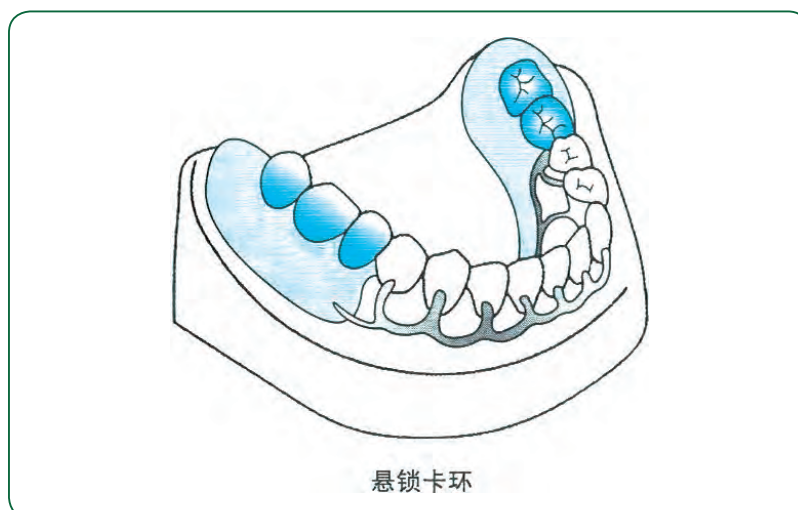
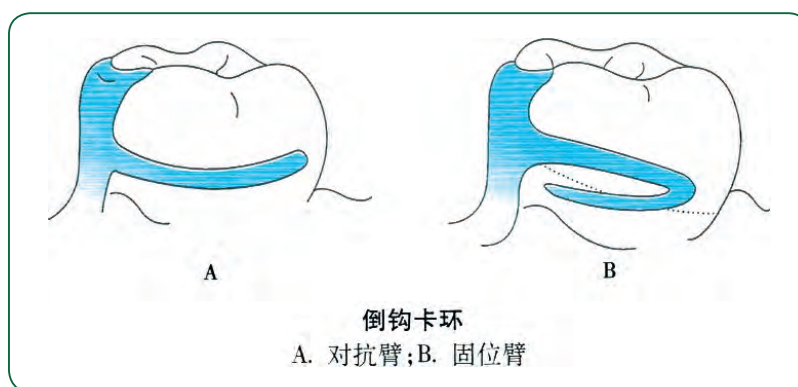
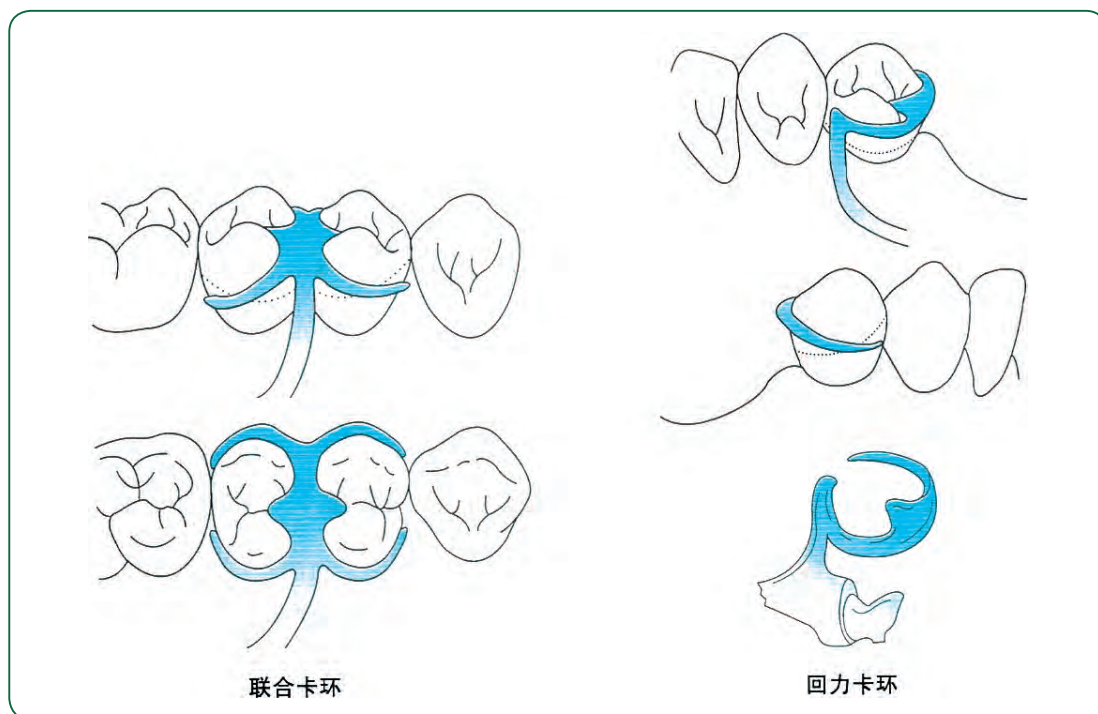
长臂卡环

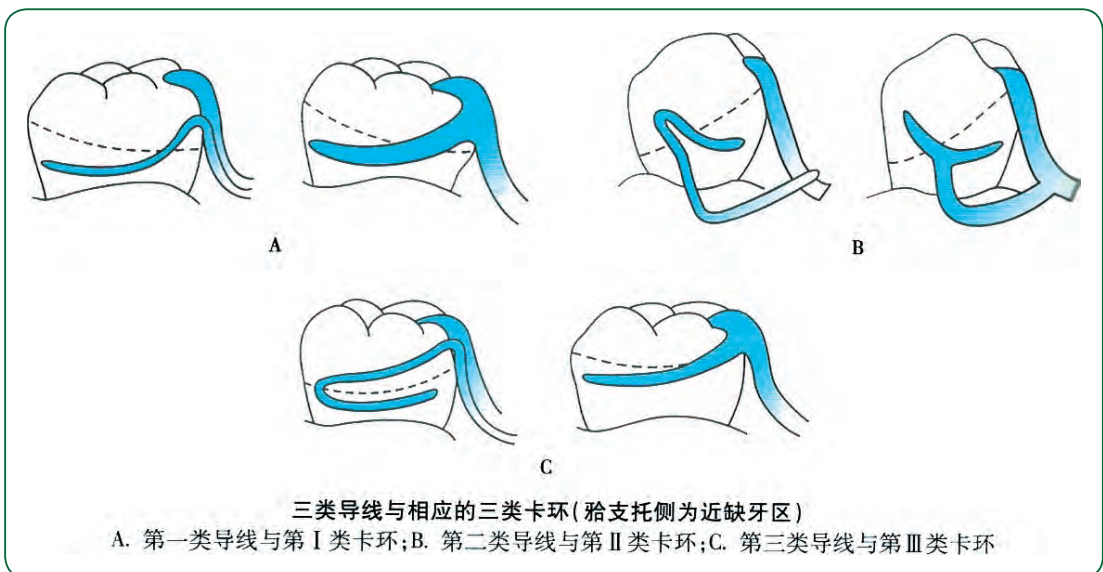
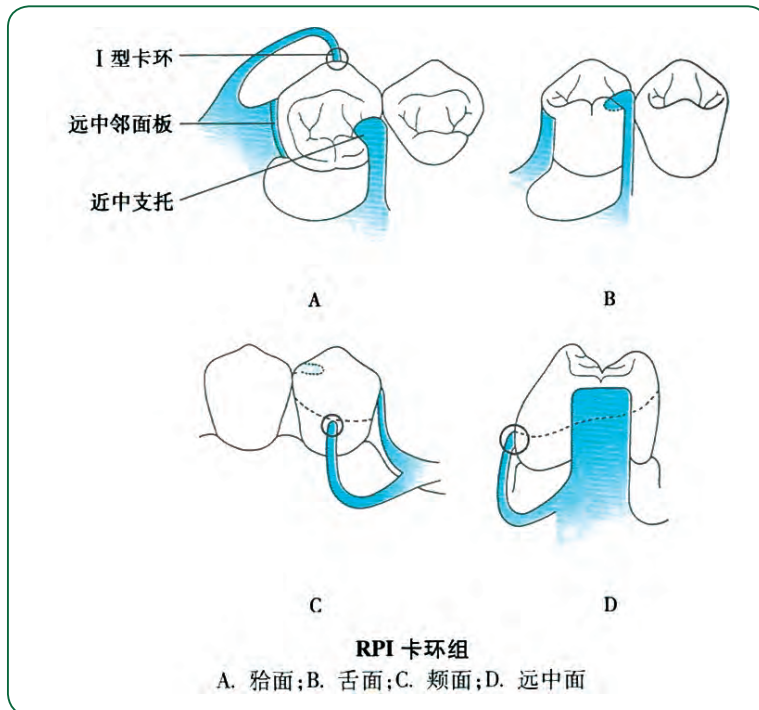
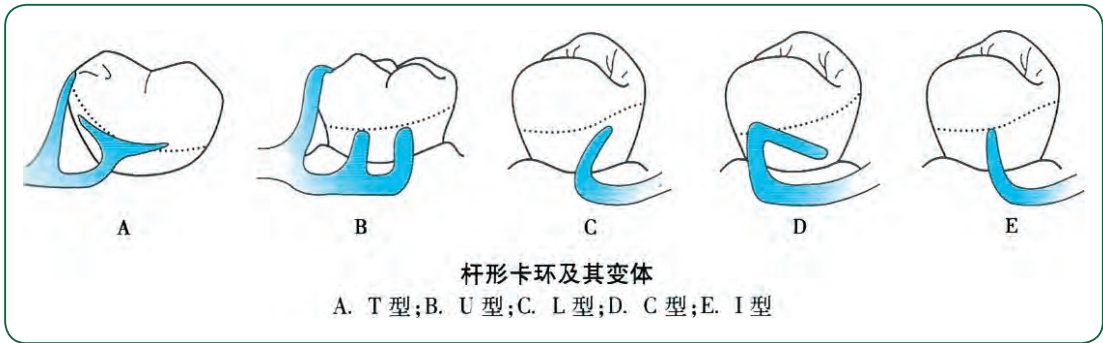
A

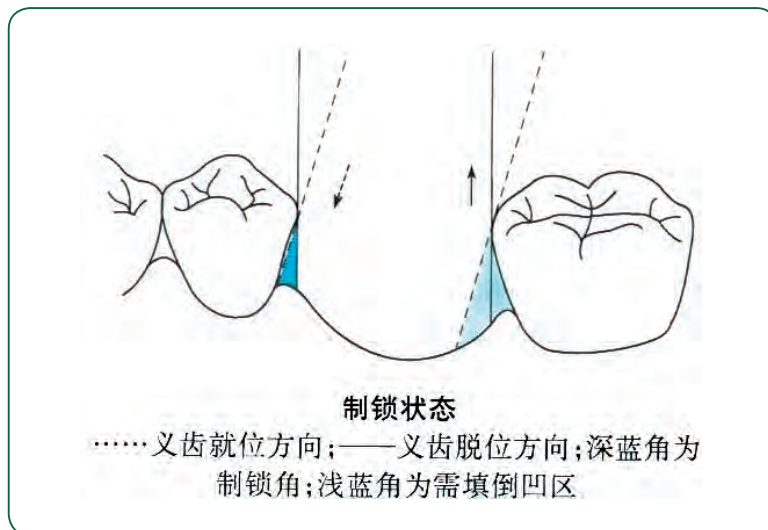
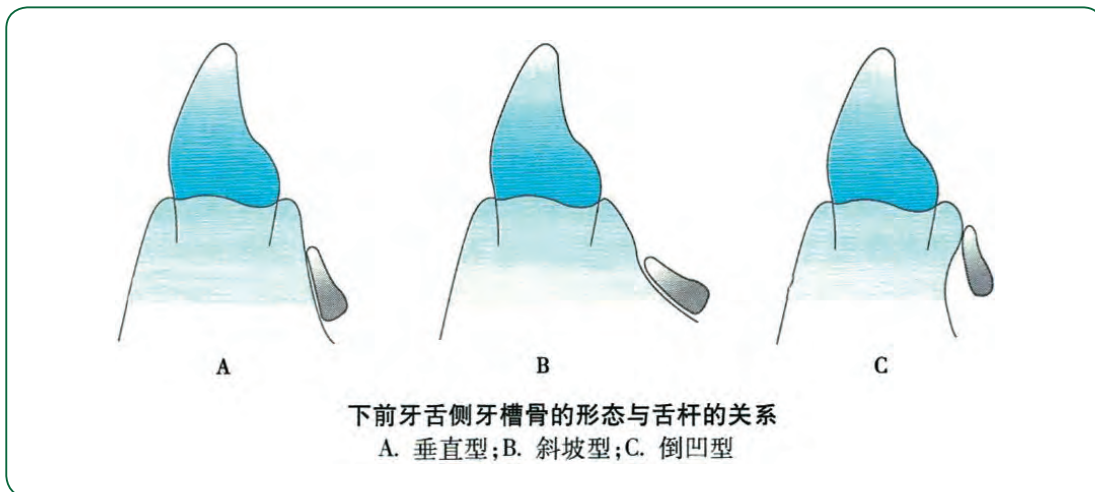
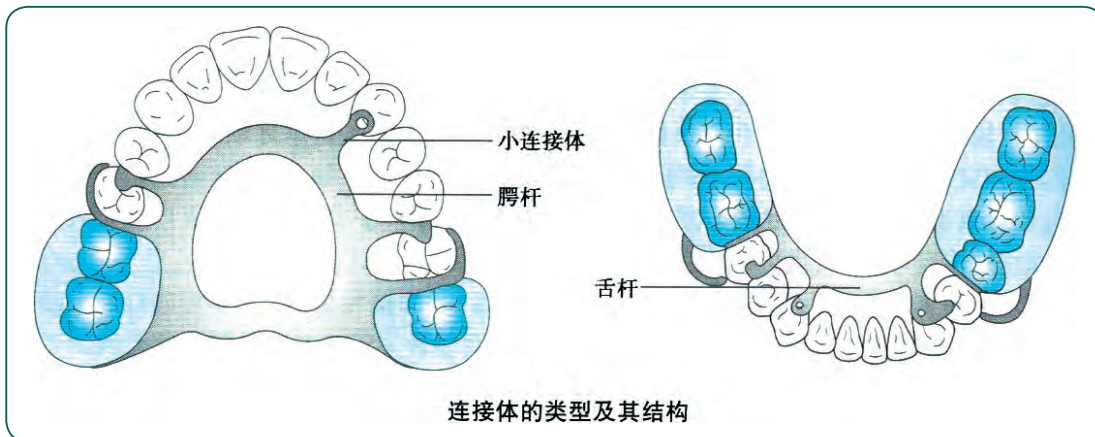
B

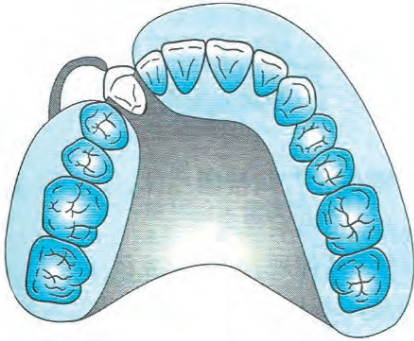
连续卡环

A. 弯制连续卡环; B. 铸造连续卡环

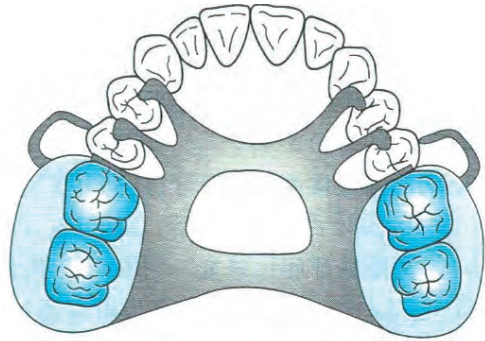




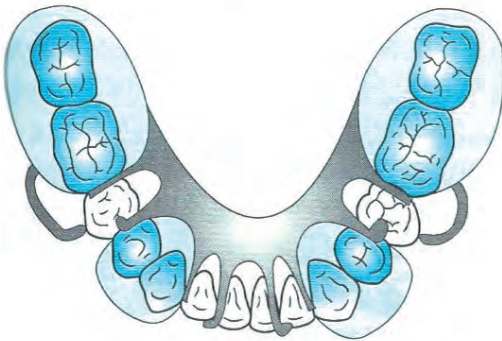




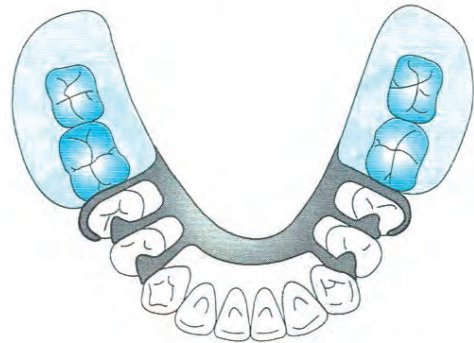上颌 Kennedy 第一类牙列缺损的
义齿设计



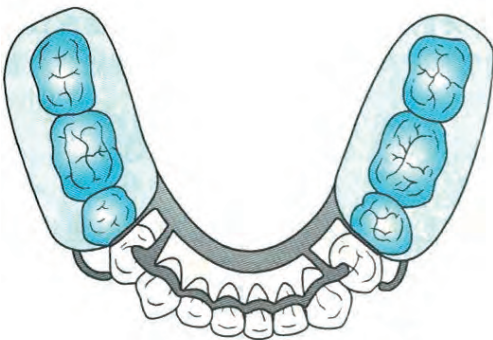
上颌 Kennedy 第一类牙列缺损的
义齿设计



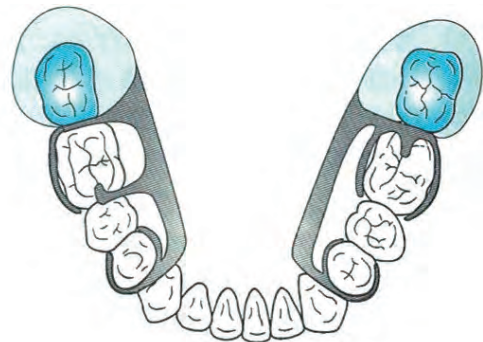
下颌 Kennedy 第一类牙列
缺损的义齿设计



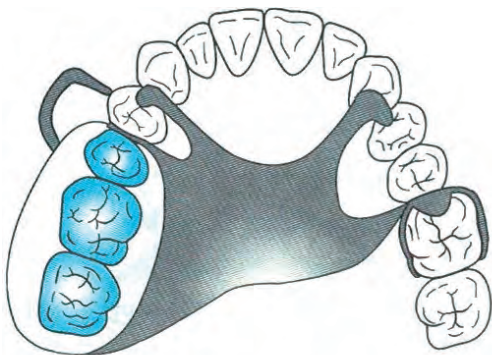
下颌 Kennedy 第一类牙列
缺损的义齿设计



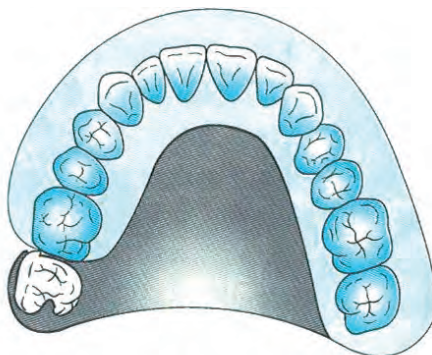
下颌 Kennedy 第一类牙列
缺损的义齿设计



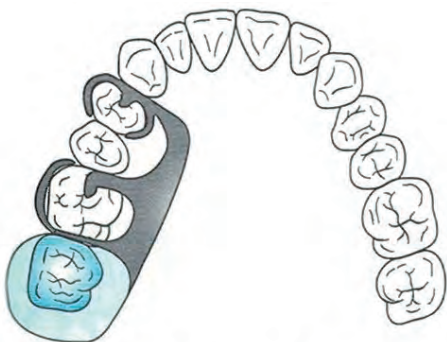
下颌 Kennedy 第一类牙列
缺损的义齿设计



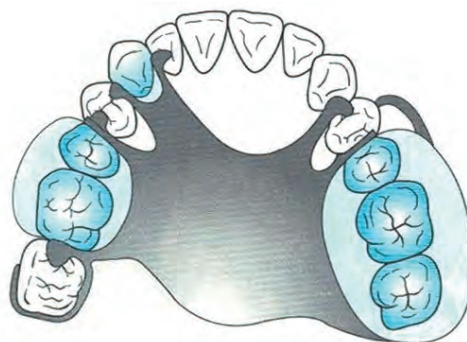
上颌 Kennedy 第二类牙列
缺损的义齿设计



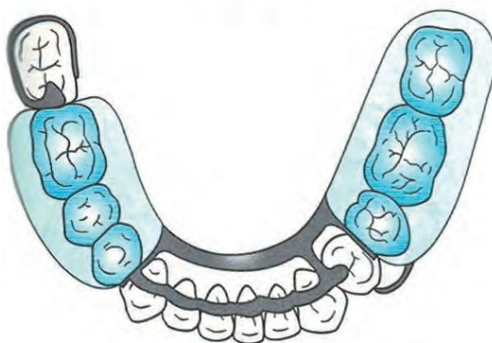
上颌 Kennedy 第二类牙列
缺损的义齿设计



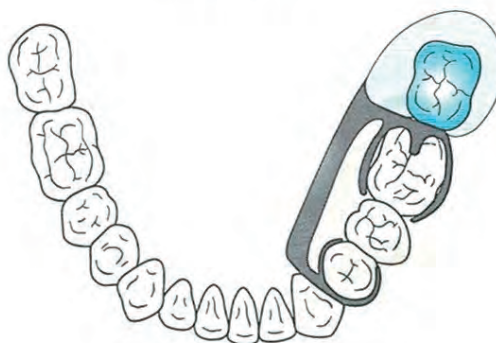
上颌 Kennedy 第二类牙列
缺损的义齿设计



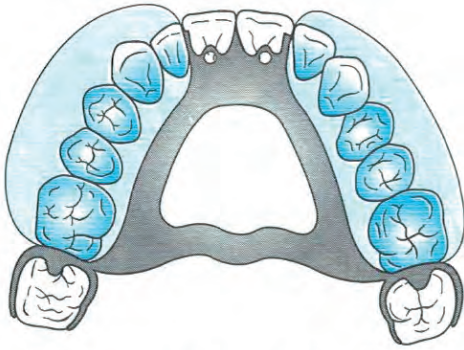
上颌 Kennedy 第二类牙列
缺损的义齿设计



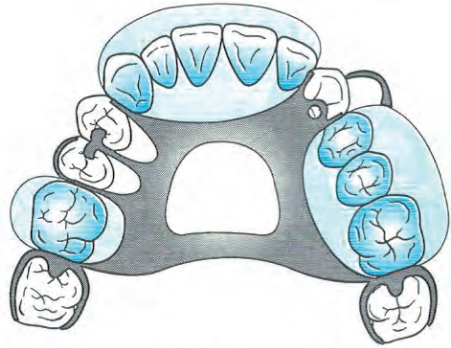
下颌 Kennedy 第二类牙列
缺损的义齿设计



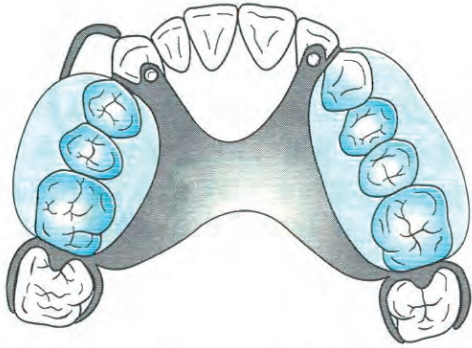
下颌 Kennedy 第二类牙列
缺损的义齿设计



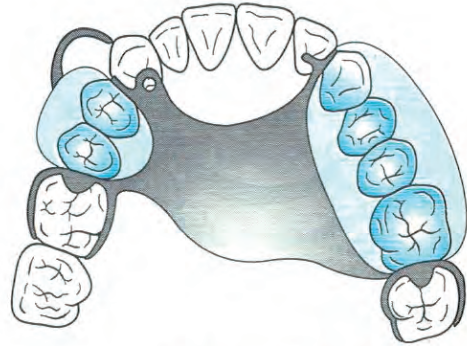
上颌 Kennedy 第三类牙列
缺损的义齿设计



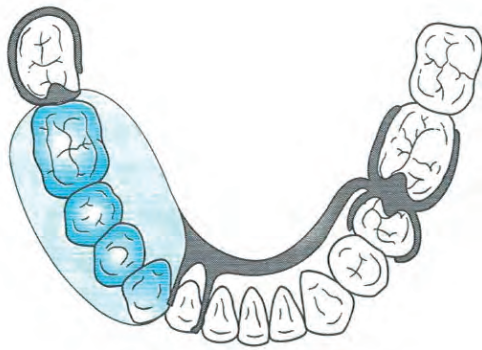
上颌 Kennedy 第三类牙列
缺损的义齿设计



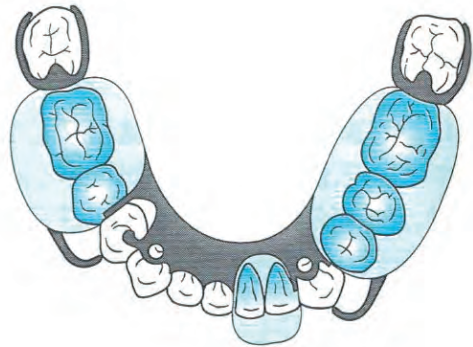
上颌 Kennedy 第三类牙列
缺损的义齿设计



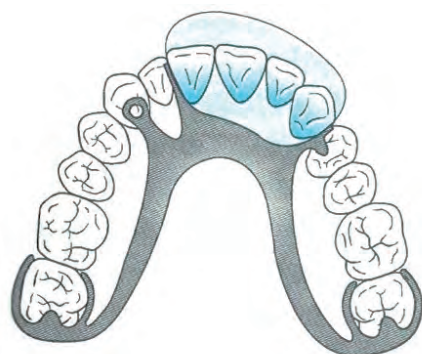
上颌 Kennedy 第三类牙列
缺损的义齿设计



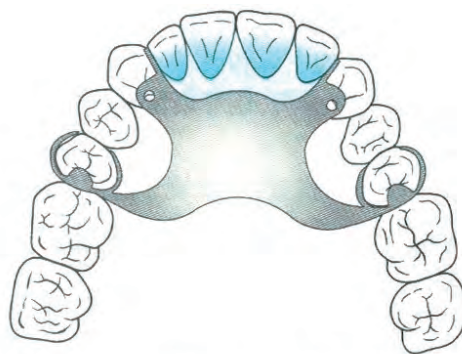
下颌 Kennedy 第三类牙列
缺损的义齿设计



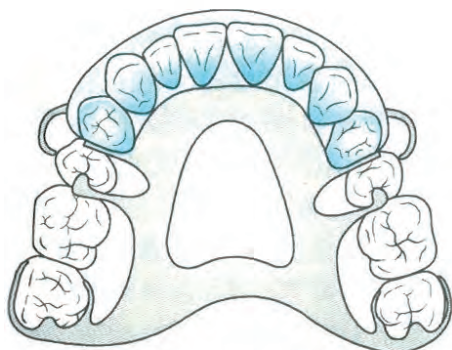
下颌 Kennedy 第三类牙列
缺损的义齿设计



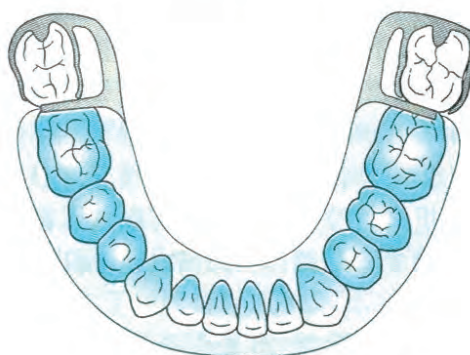
上颌 Kennedy 第四类牙列
缺损的义齿设计



上颌 Kennedy 第四类牙列
缺损的义齿设计

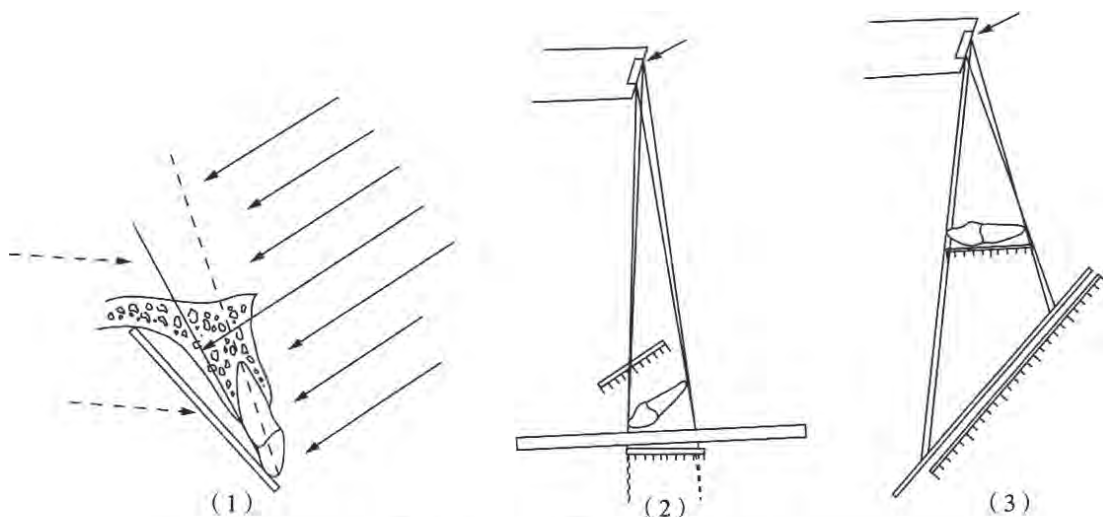


上颌 Kennedy 第四类牙列
缺损的义齿设计



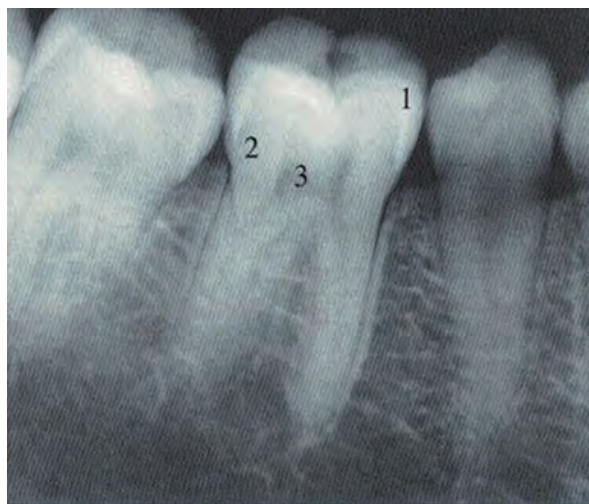下颌 Kennedy 第四类牙列
缺损的义齿设计

口腔颌面影像诊断学



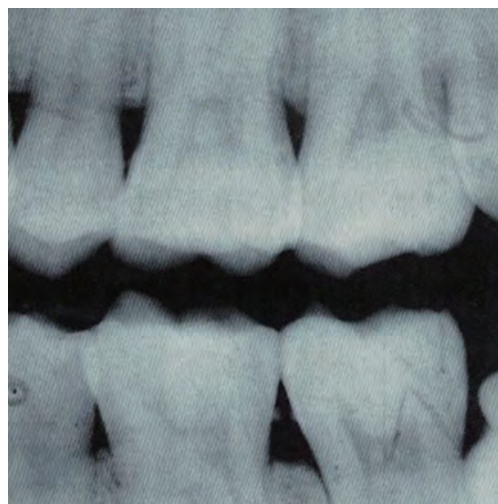分角线投照技术原理示意图

- (1) X线中心线垂直于被照牙与胶片夹角的角平分线；(2) X线中心线垂直于胶片，牙体影像缩小；
(3) X线中心线垂直于被照牙体，则牙体影像放大

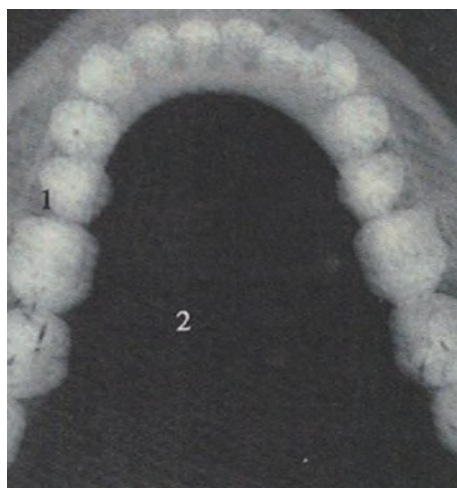


下颌后牙根尖片

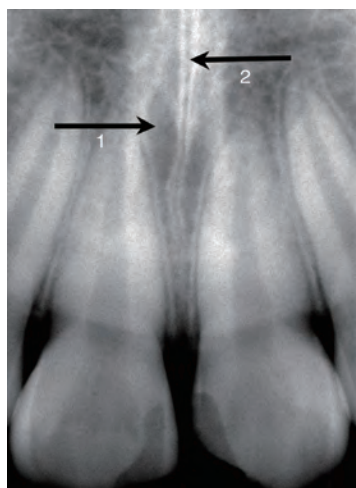
- (1) 牙釉质；(2) 牙本质；(3) 髓腔



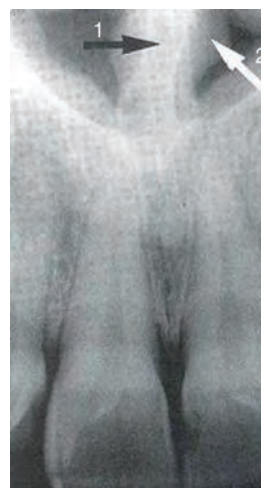牙合翼片



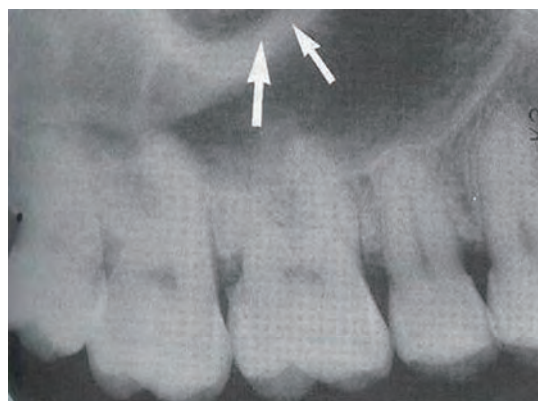
下颌横断牙合片



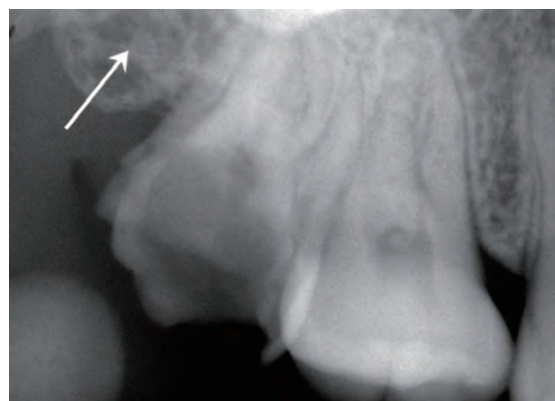
1. 切牙孔 2. 腭中缝



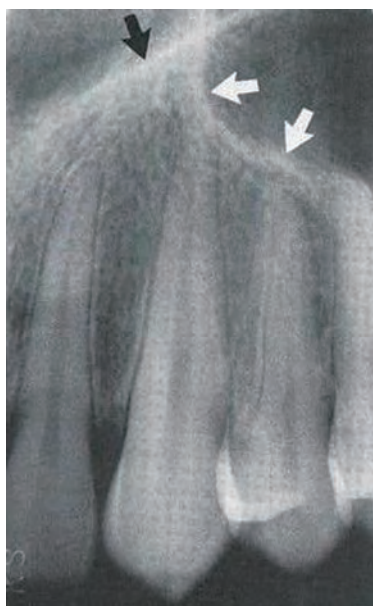1. 鼻中隔 2. 鼻腔



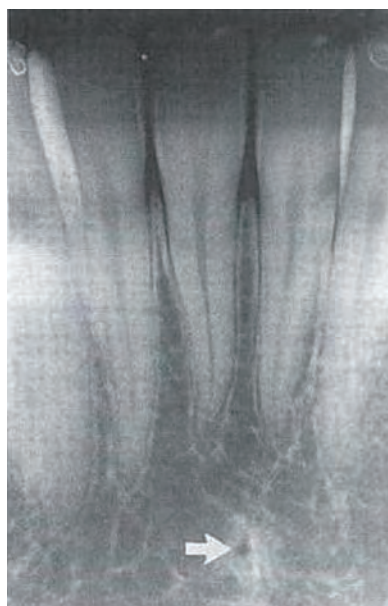
颧骨



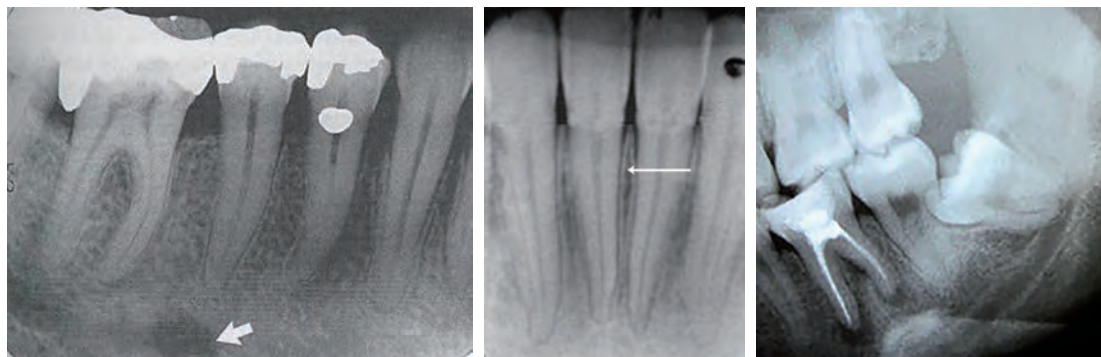
上颌结节



上颌窦



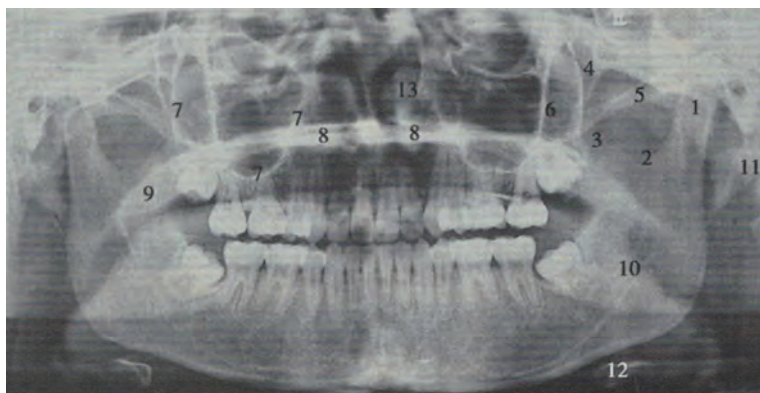颞棘



颞孔

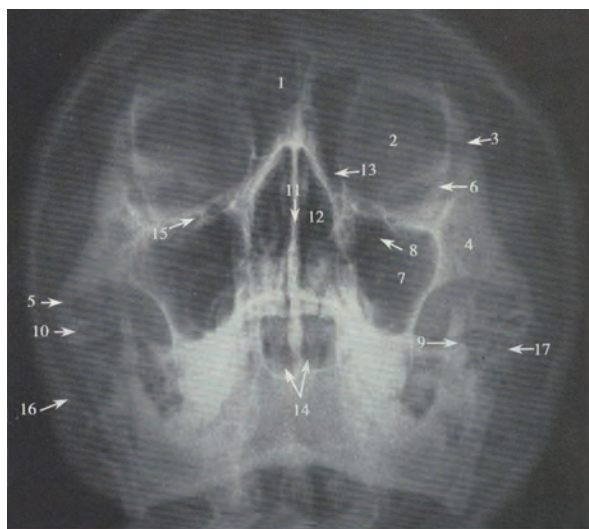
营养管

下颌管



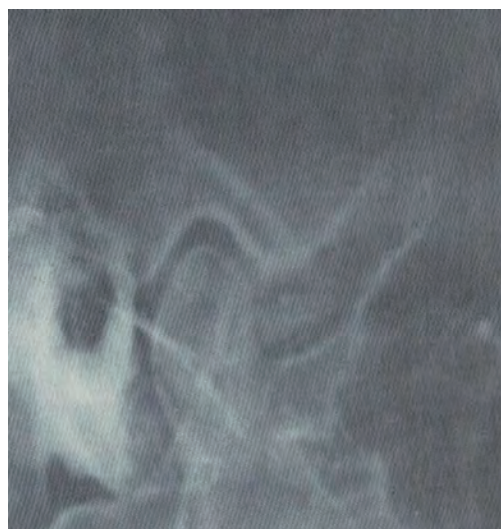
曲面体层片

1. 髁突; 2. 乙状切迹; 3. 喙突; 4. 翼腭窝; 5. 颧弓; 6. 颧骨; 7. 上颌窦; 8. 硬腭;
9. 软腭; 10. 下颌管; 11. 茎突; 12. 舌骨; 13. 鼻腔

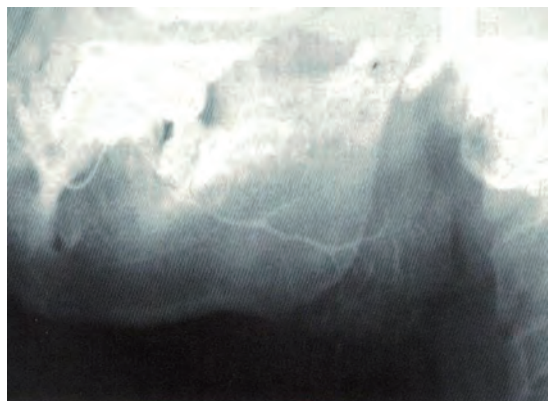


正常华特位图像

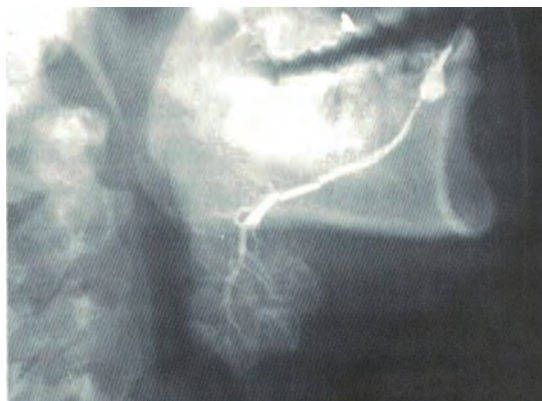
1. 额窦; 2. 眼眶; 3. 颧额缝; 4. 颧骨; 5. 颧弓; 6. 无名线; 7. 上颌窦;
8. 眶上裂; 9. 喙突; 10. 关节结节; 11. 鼻中隔; 12. 鼻腔; 13. 筛窦;
14. 蝶窦; 15. 眶下孔; 16. 乳突蜂房; 17. 髁突



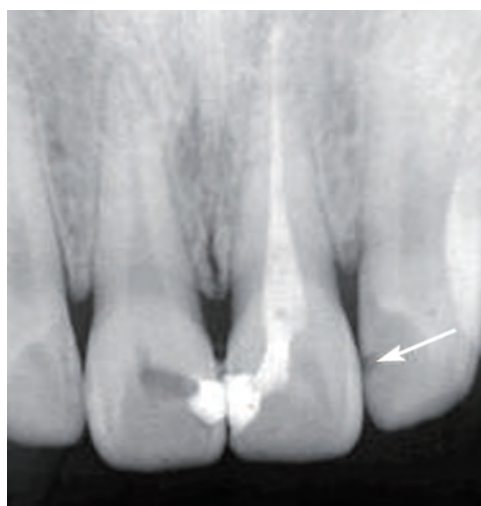许勒位



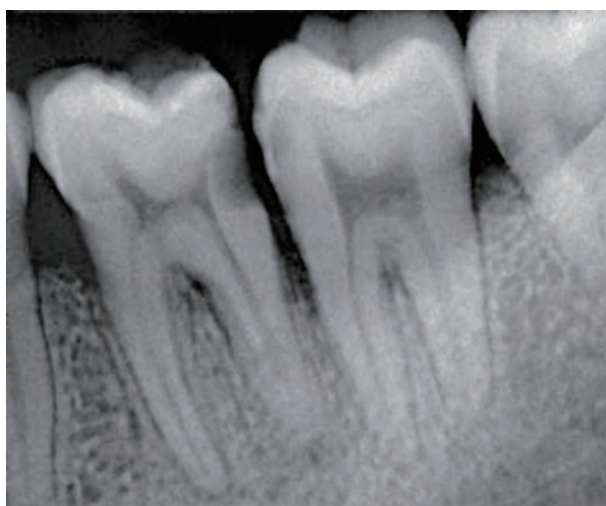
腮腺造影



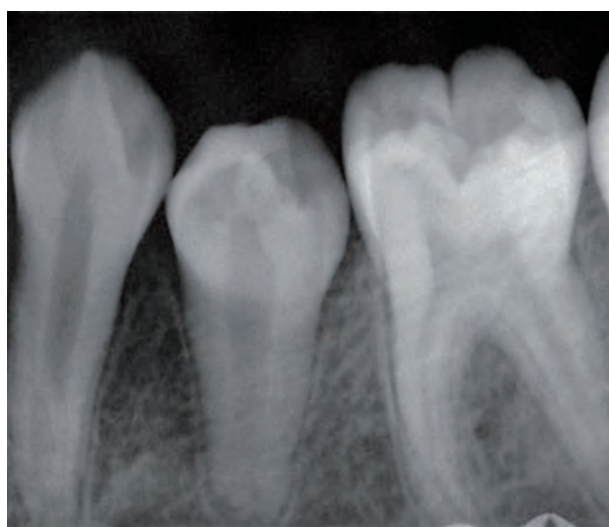
下颌下腺造影



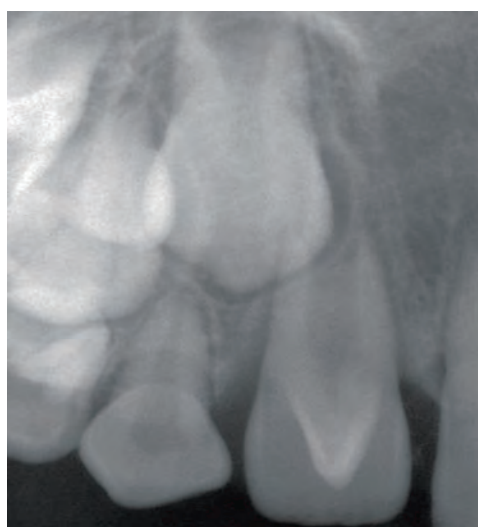浅龋



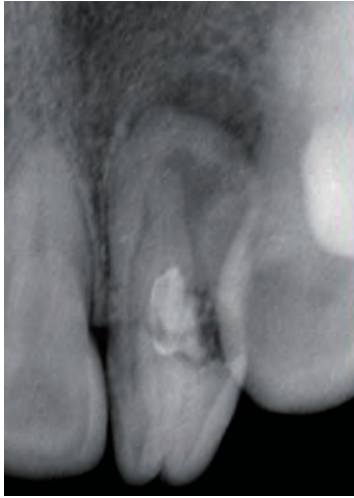
深龋



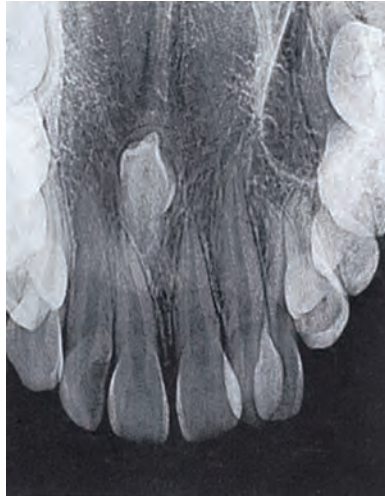畸形舌侧尖



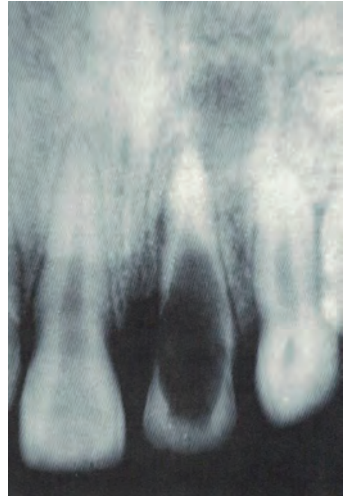畸形舌侧尖



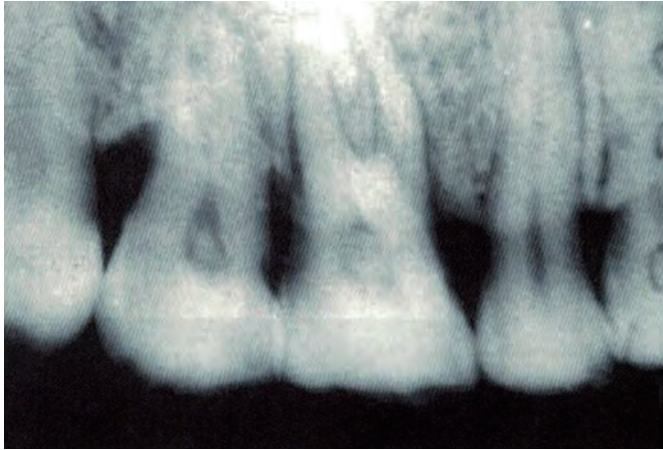牙中牙



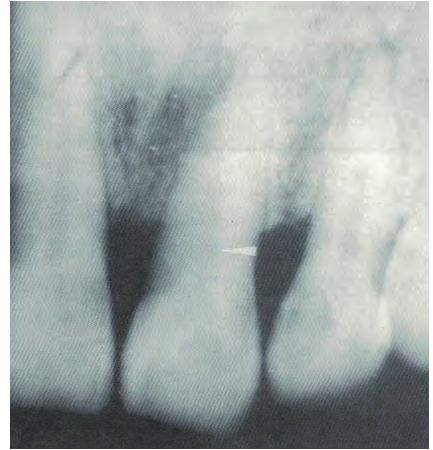额外牙



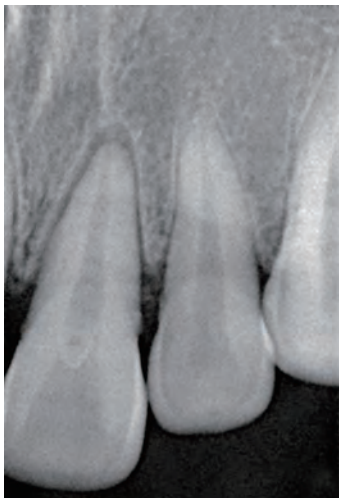
牙内吸收



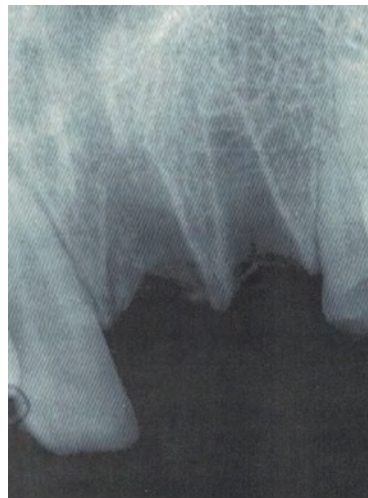
髓石



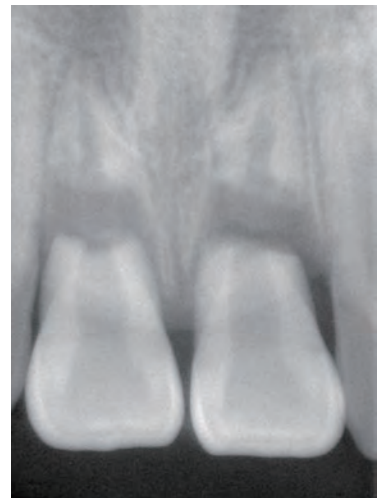
牙髓钙化



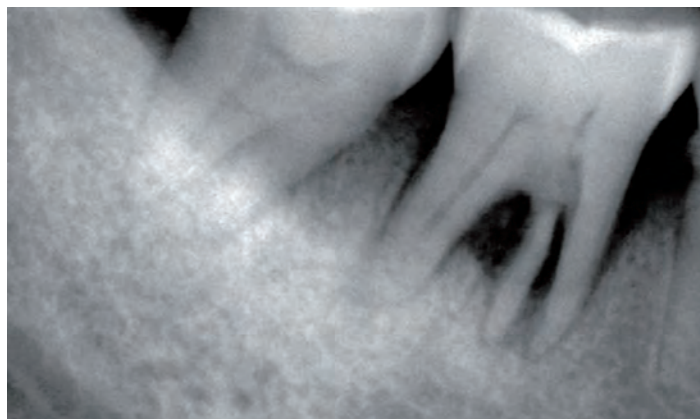
牙脱位



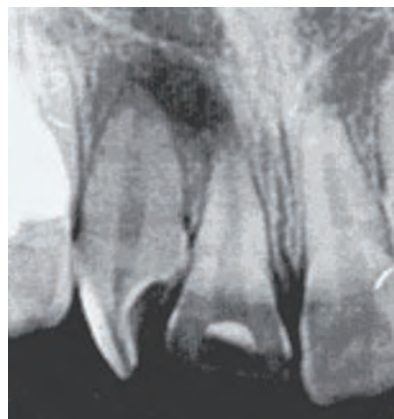牙脱位



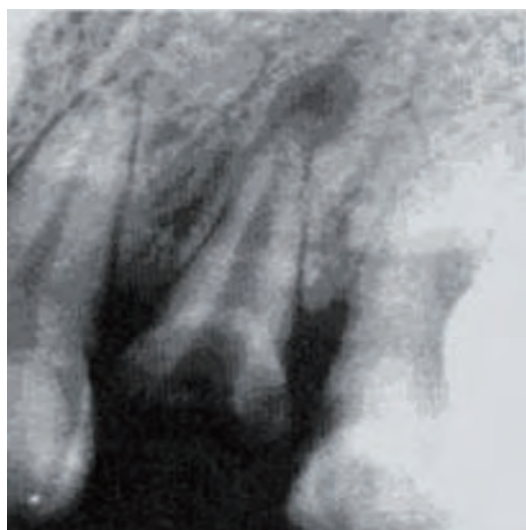
牙折



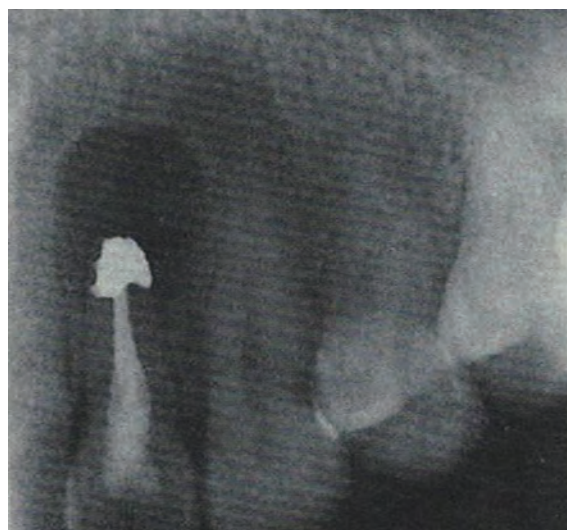
牙根折裂



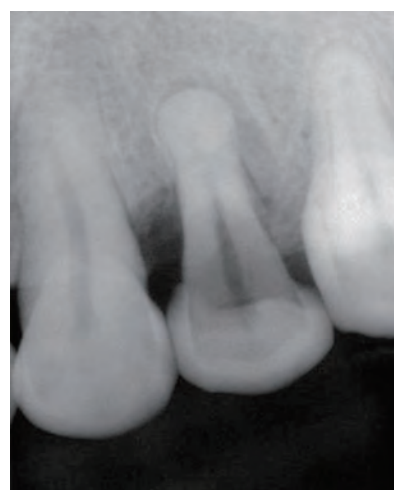
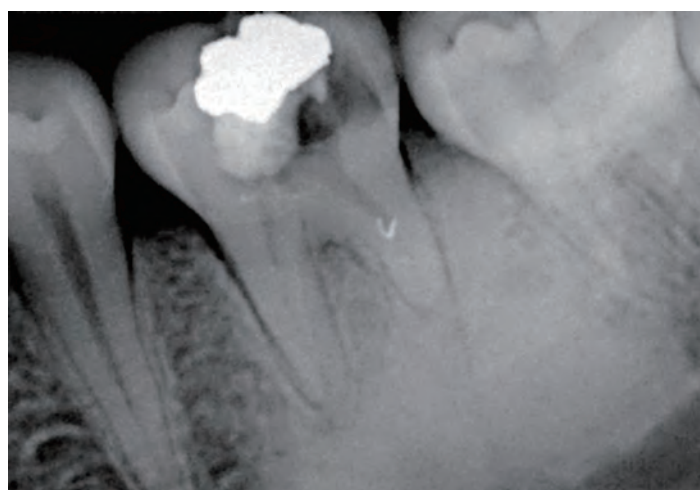
根尖周脓肿



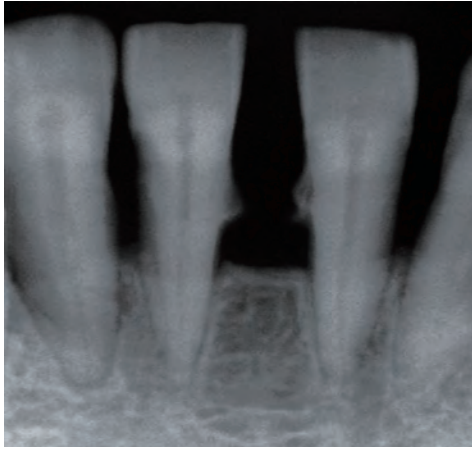
根尖周肉芽肿



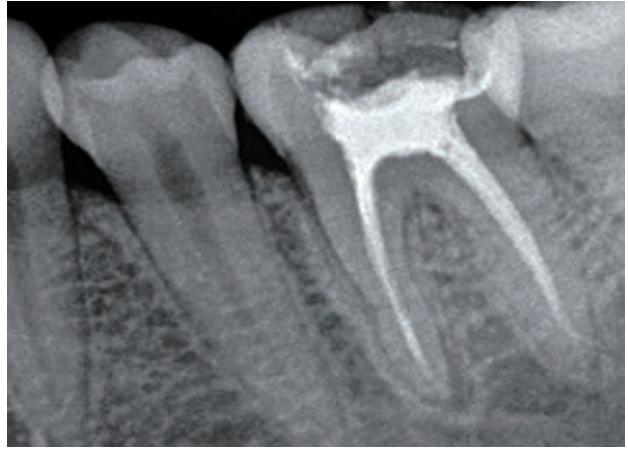根尖周囊肿



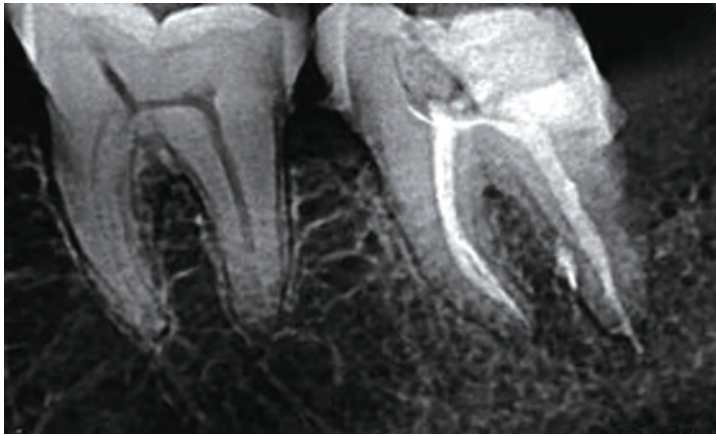
牙骨质增生



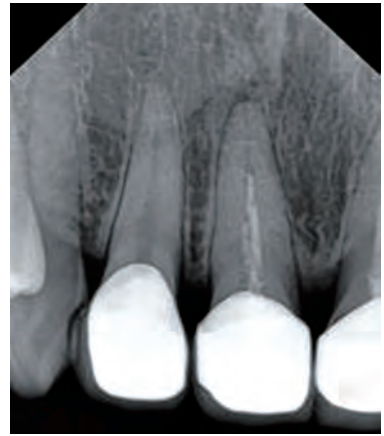
牙周炎



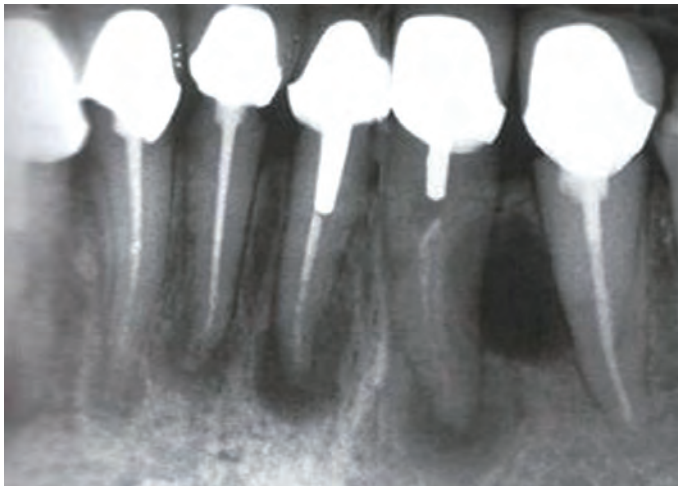
恰填



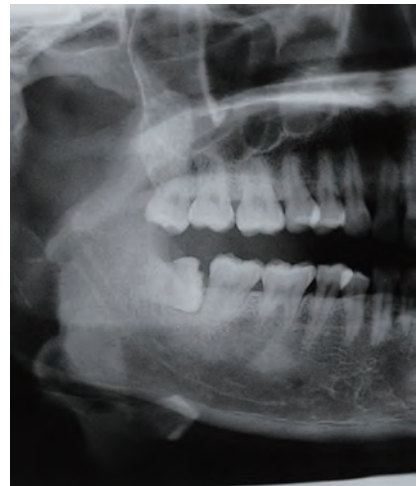超填



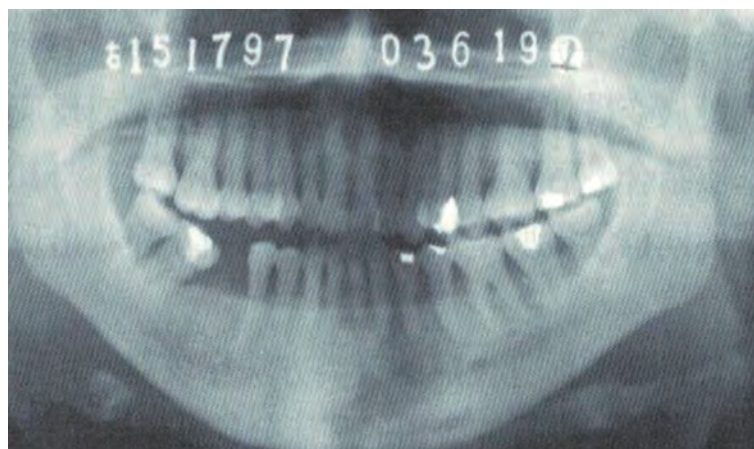欠填



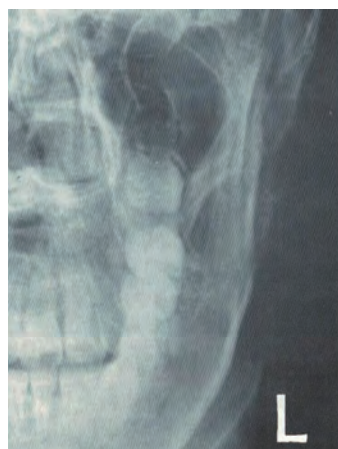充填不严密



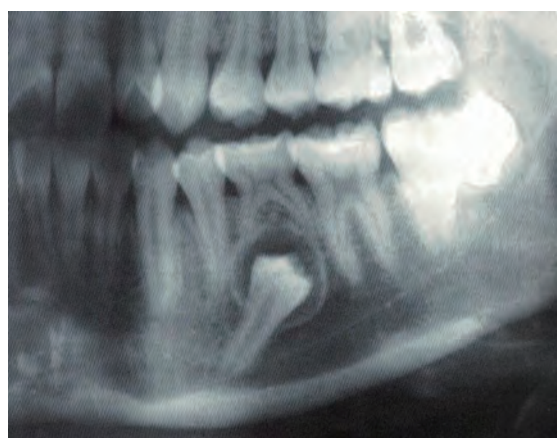第三磨牙阻生



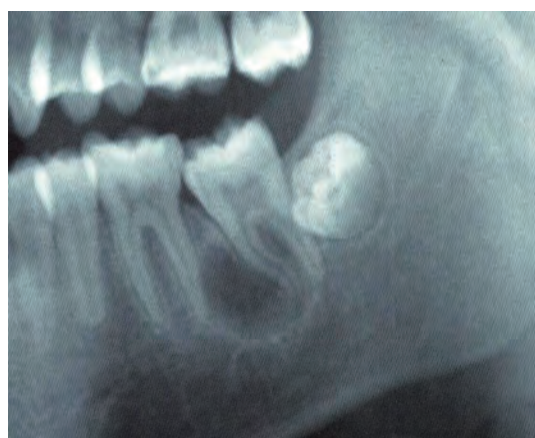中央性颌骨骨髓炎



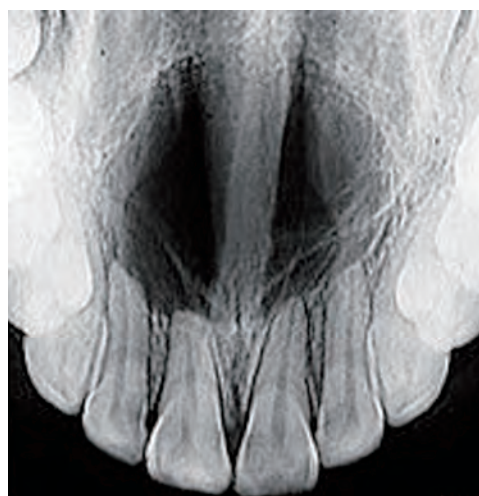边缘性颌骨骨髓炎



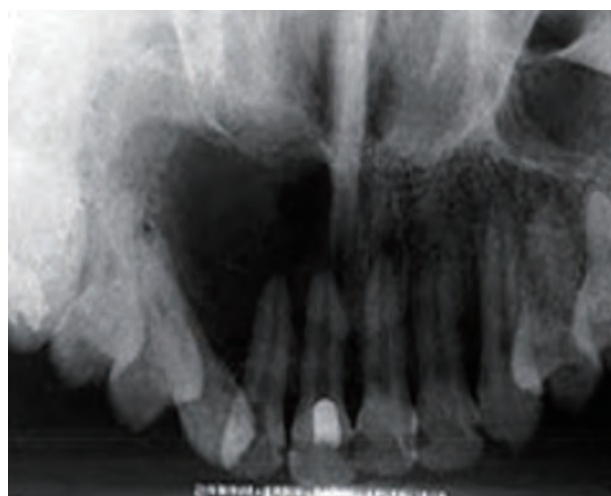
含牙囊肿



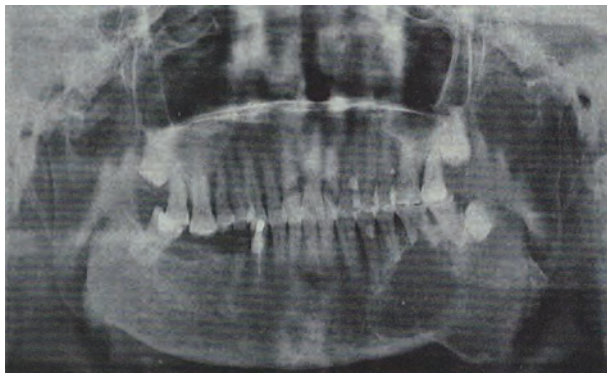根侧囊肿



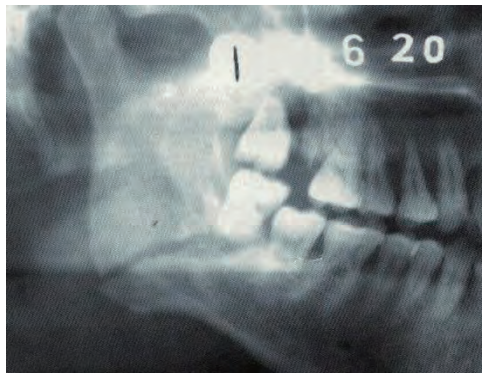
鼻腭囊肿



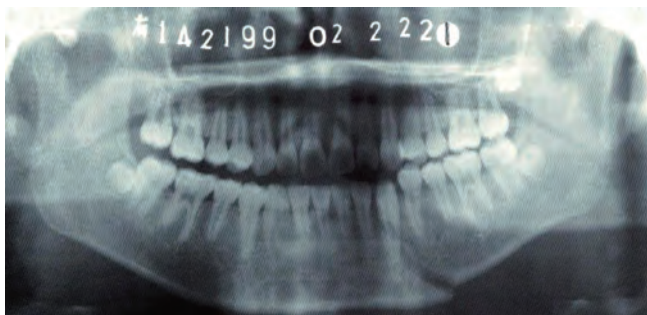球上颌囊肿



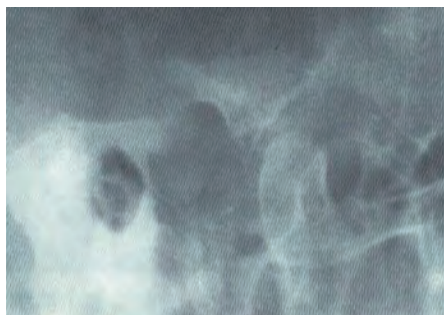
成釉细胞瘤



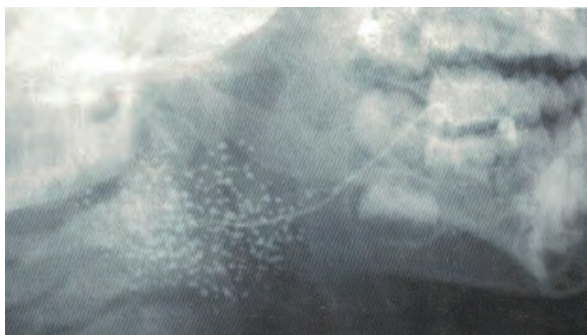下颌角骨折



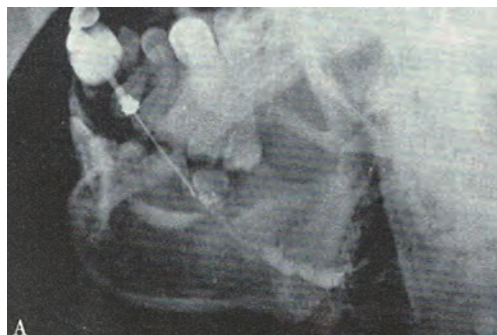颧孔区骨折



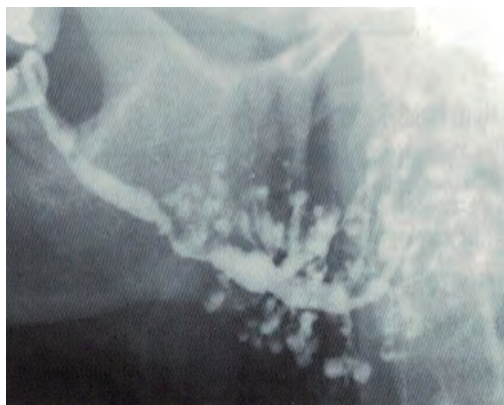颞下颌关节脱位



慢性复发性腮腺炎



慢性阻塞性腮腺炎



舍格伦综合征