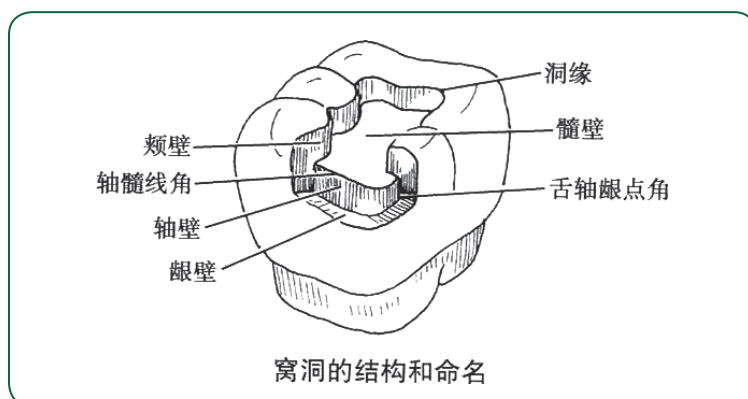
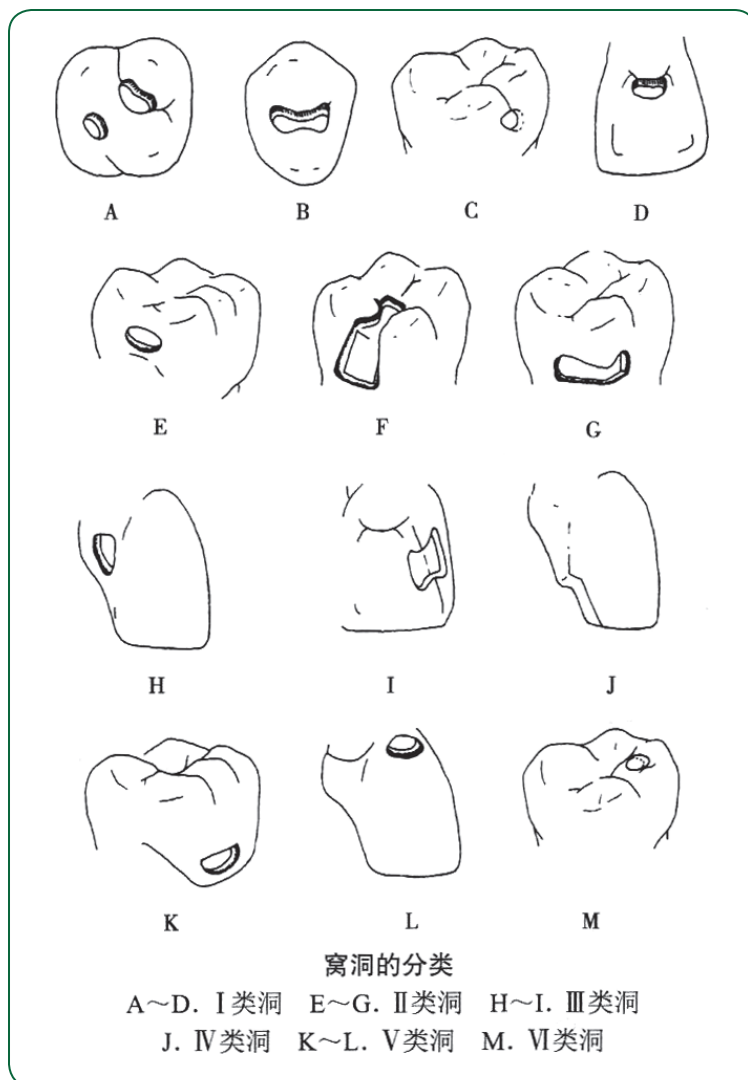
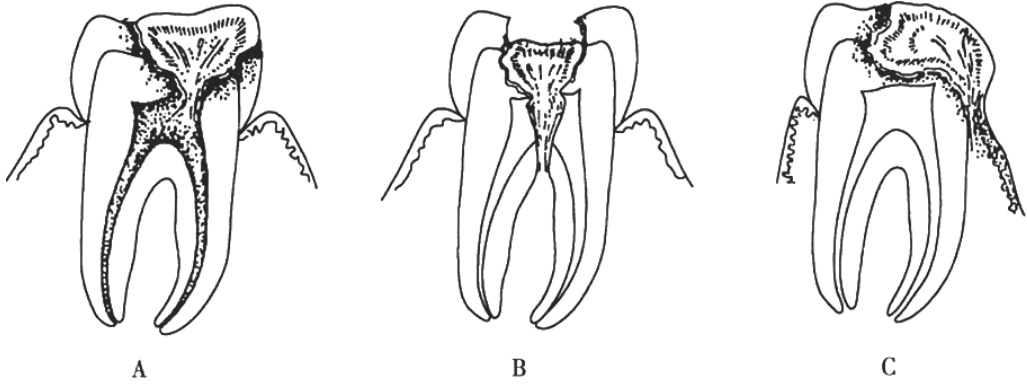


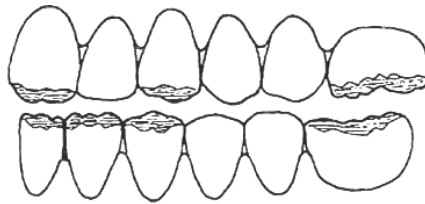
# 牙体牙髓病学、儿童口腔医学



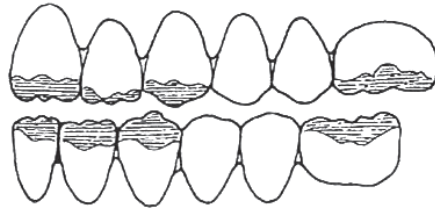


龋洞内息肉的来源

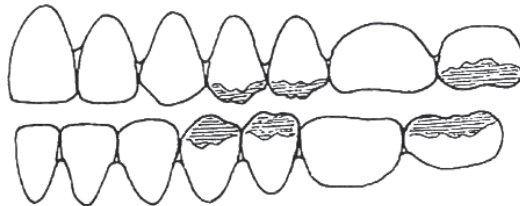
A. 牙髓息肉 B. 牙周膜息肉 C. 牙龈息肉



A. 出生后第1年罹患牙位

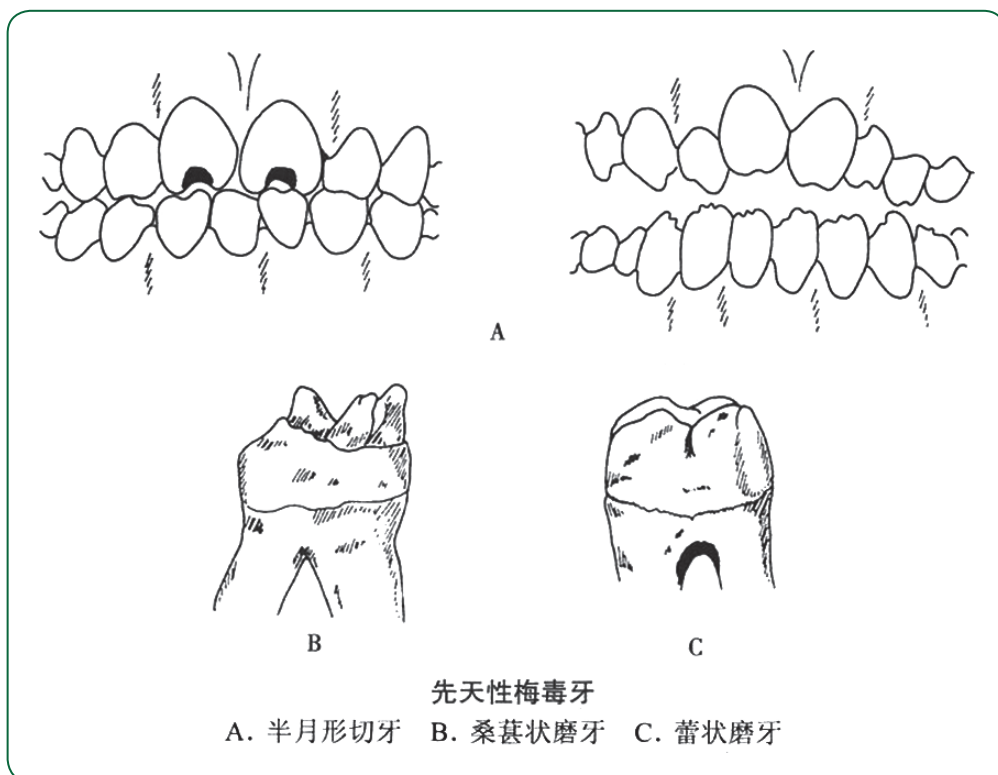
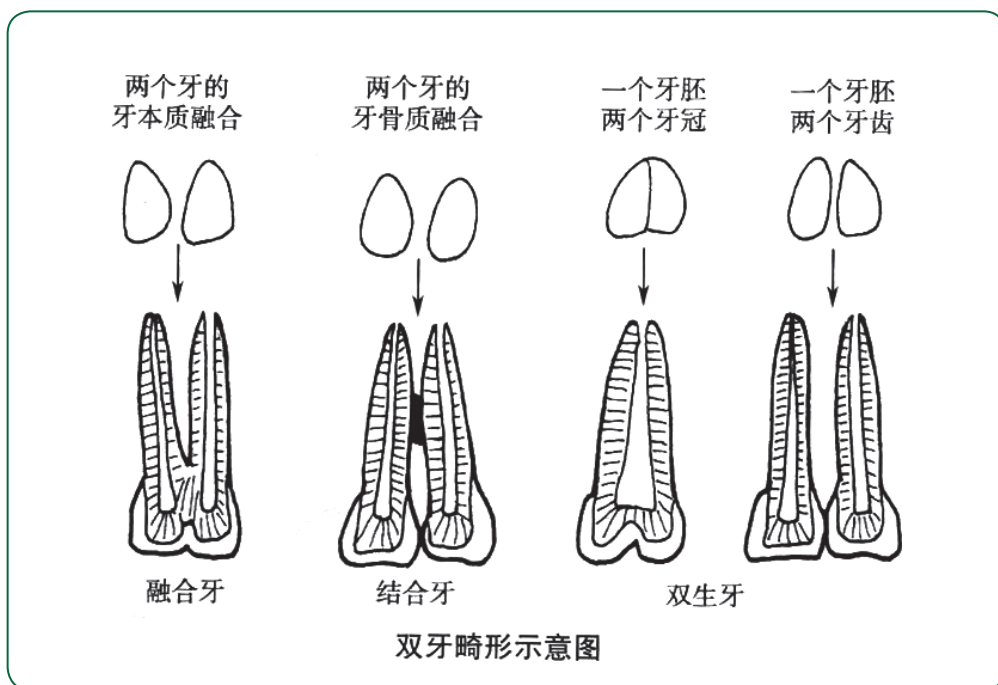


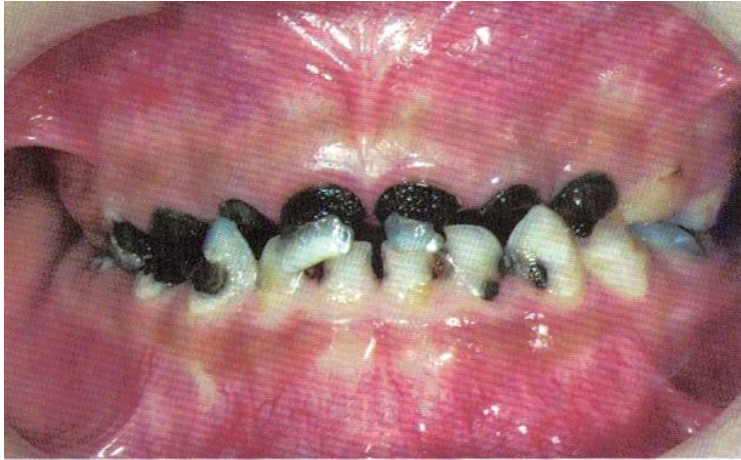B. 出生后第1、2年罹患牙位



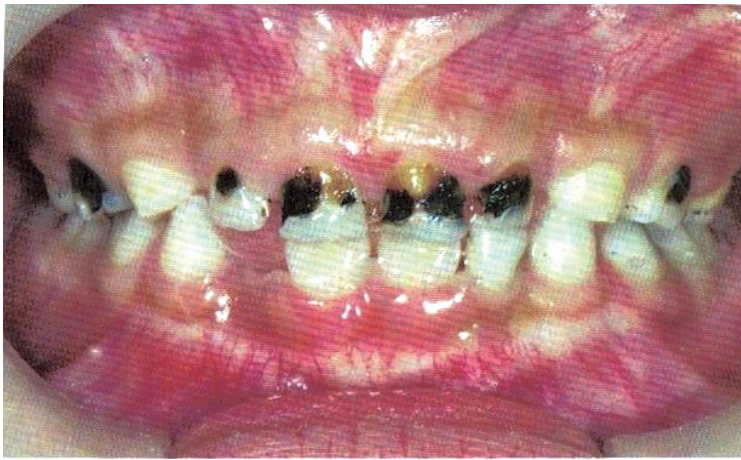
C. 出生后第3年罹患牙位

不同年龄釉质发育不全的罹患牙位

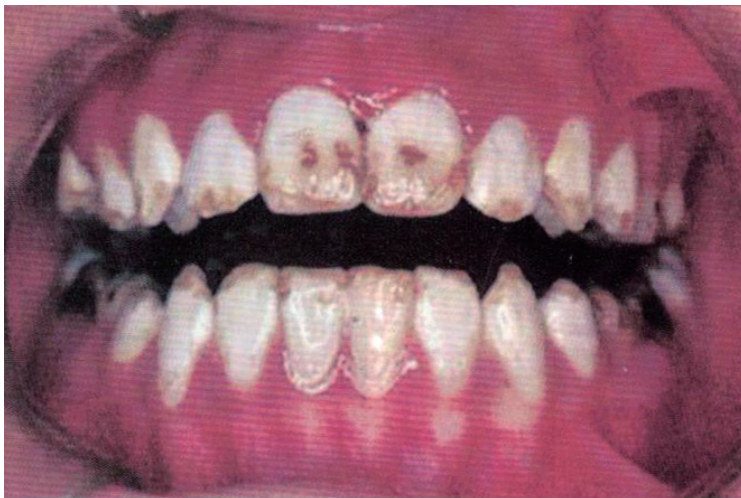




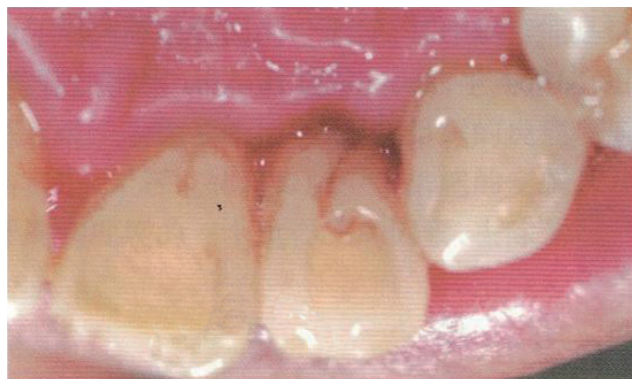猛性龋



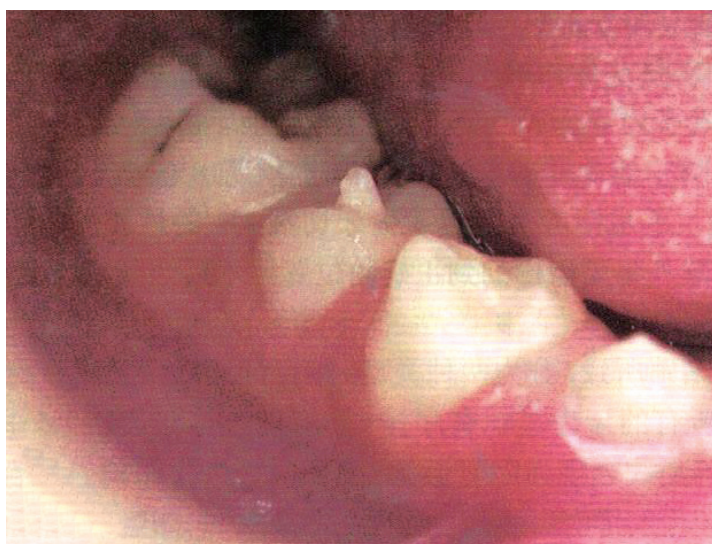环状龋



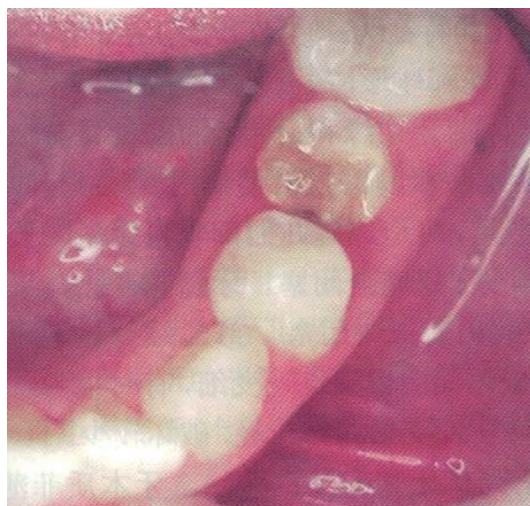氟牙症



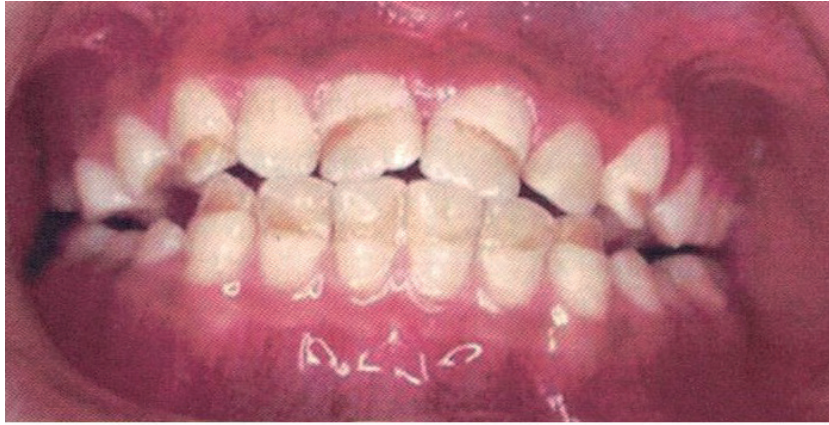
畸形舌侧沟



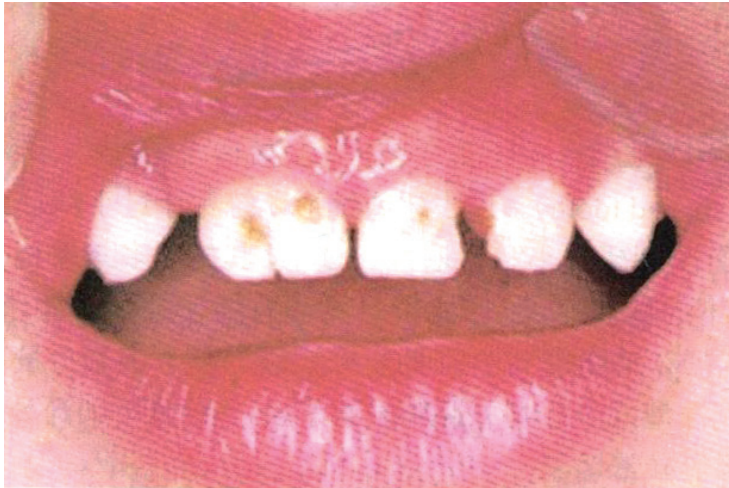畸形中央尖(45)



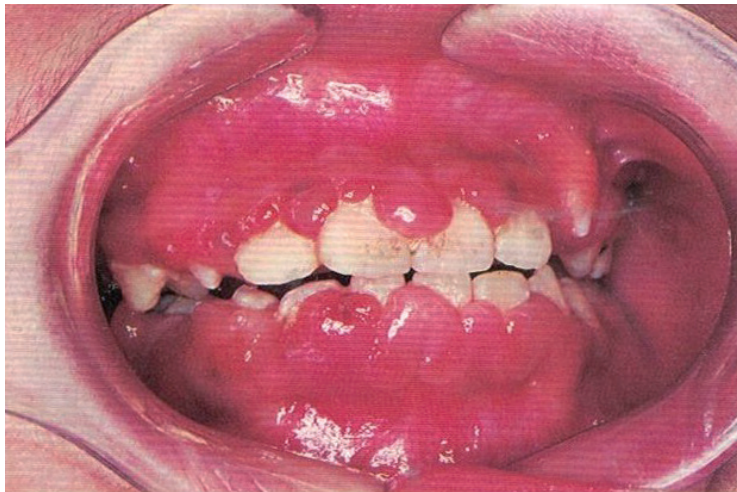
特纳牙(35)



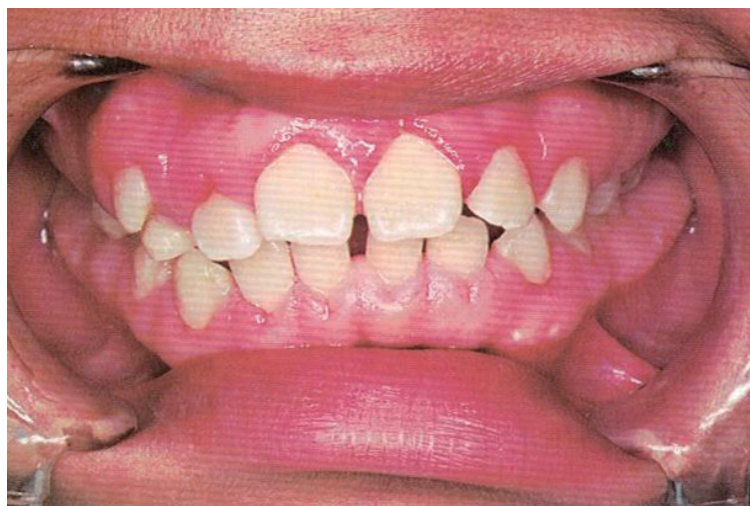釉质发育不全



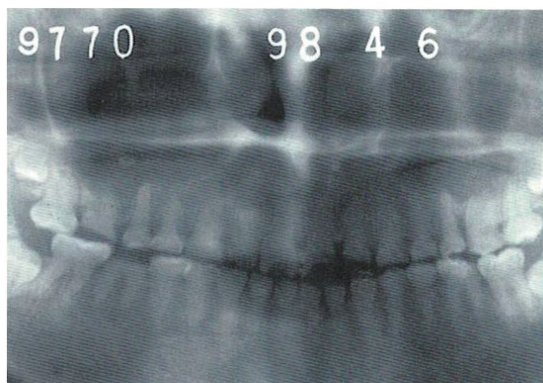
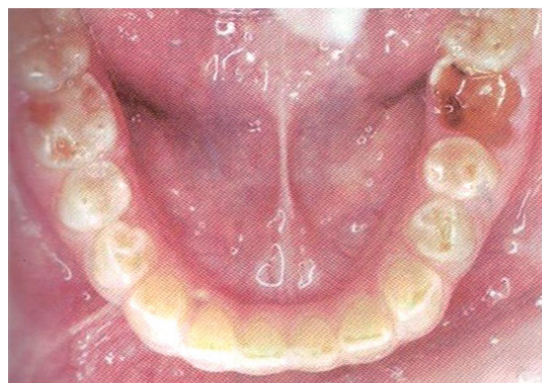
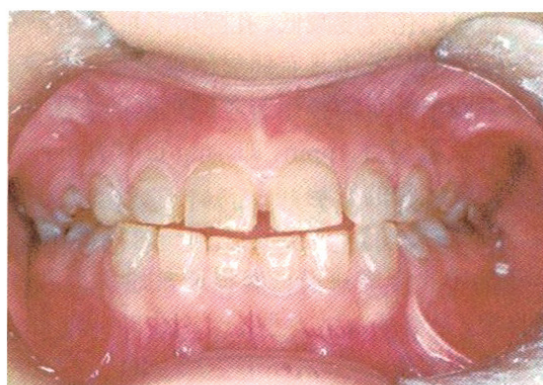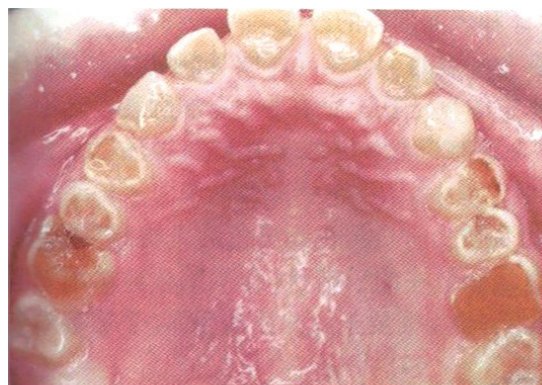融合牙(51, 52)



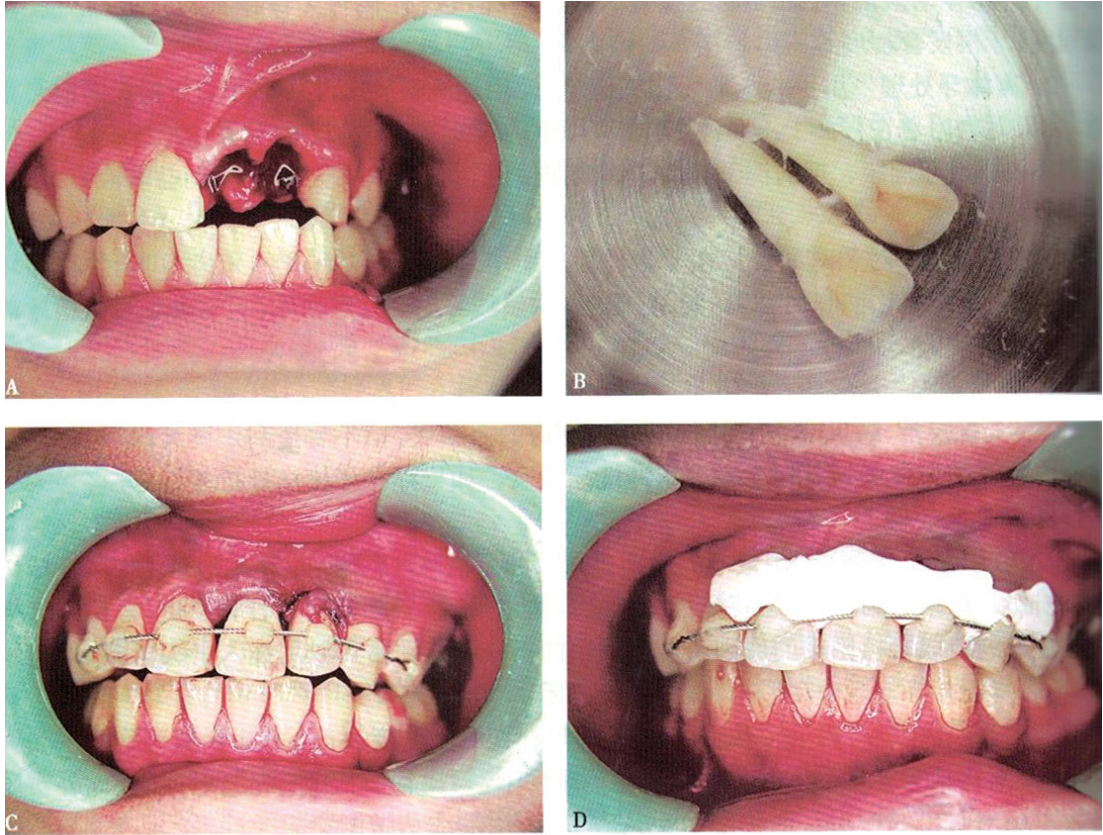
药物性牙龈增生(女, 10岁)



牙龈纤维瘤病(男, 13岁)



遗传性乳光牙本质

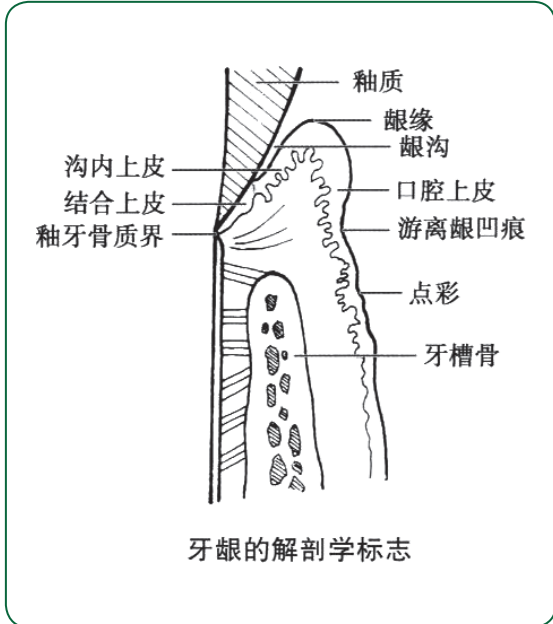


全脱出的复位固定(21, 22)

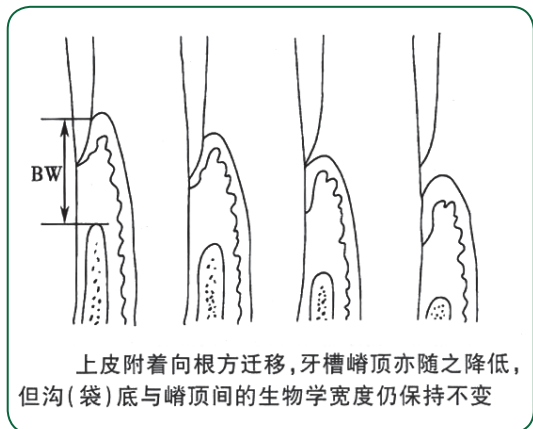
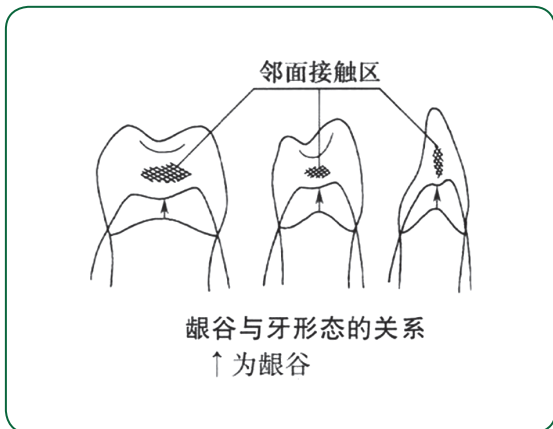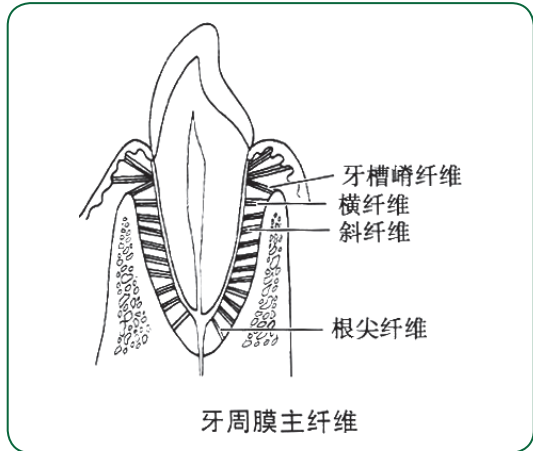
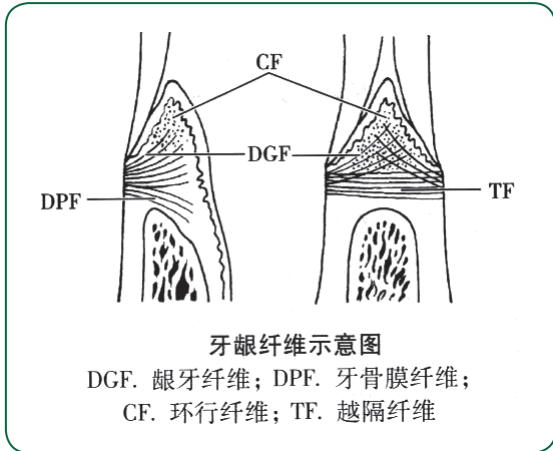
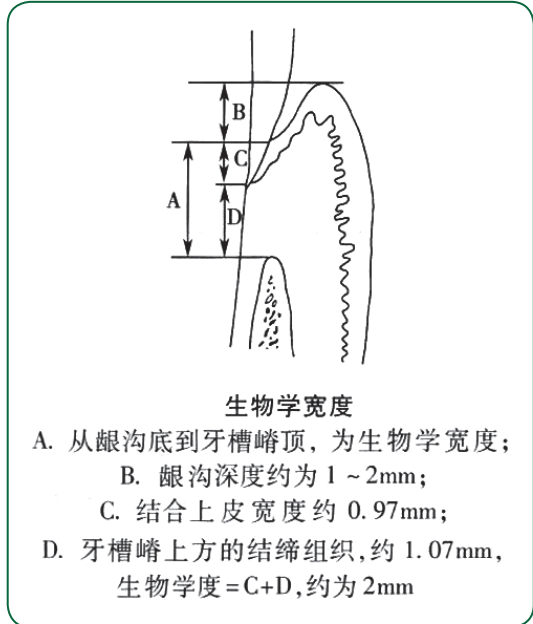
- A. 牙齿全脱出(21, 22) B. 浸泡在生理盐水内的全脱出牙  
C. 全脱出的复位固定(21, 22) D. 全脱出的复位固定后牙周塞治剂保护牙龈

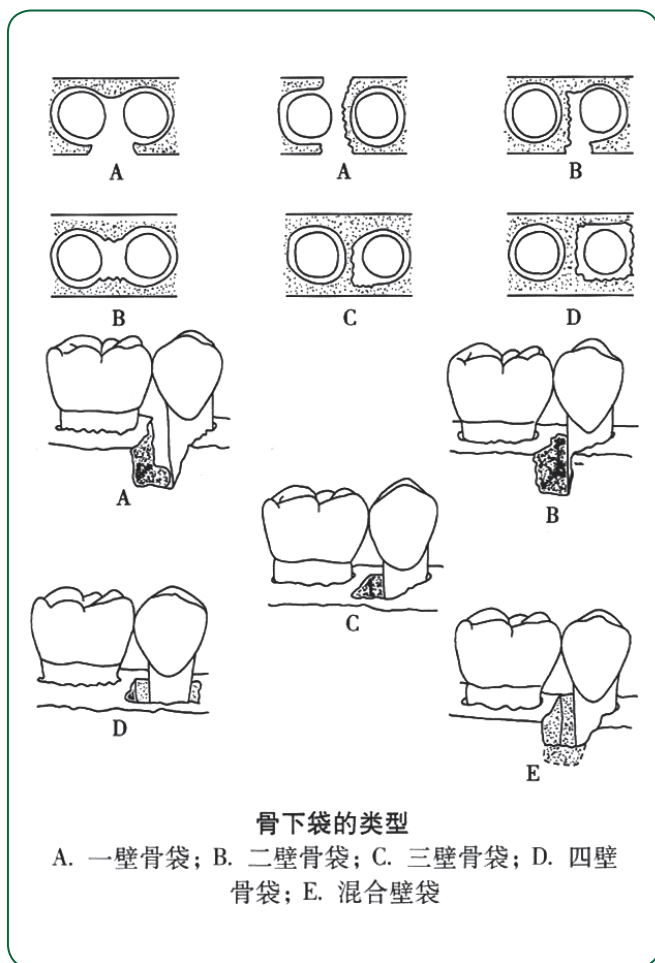
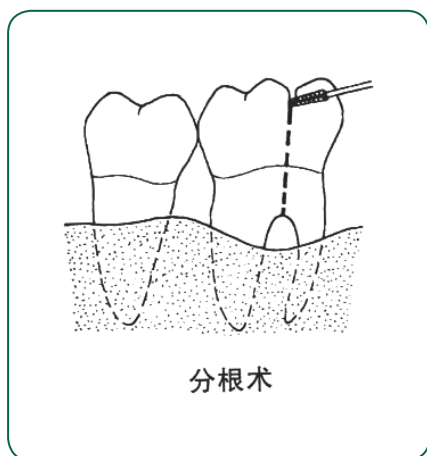
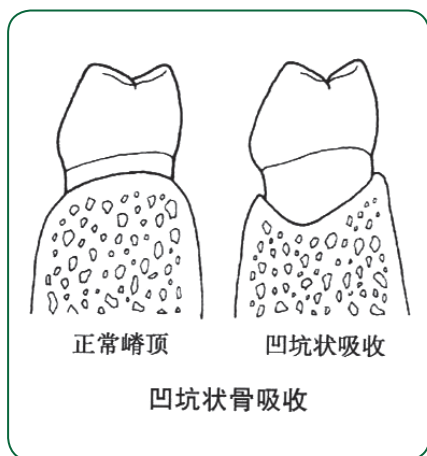
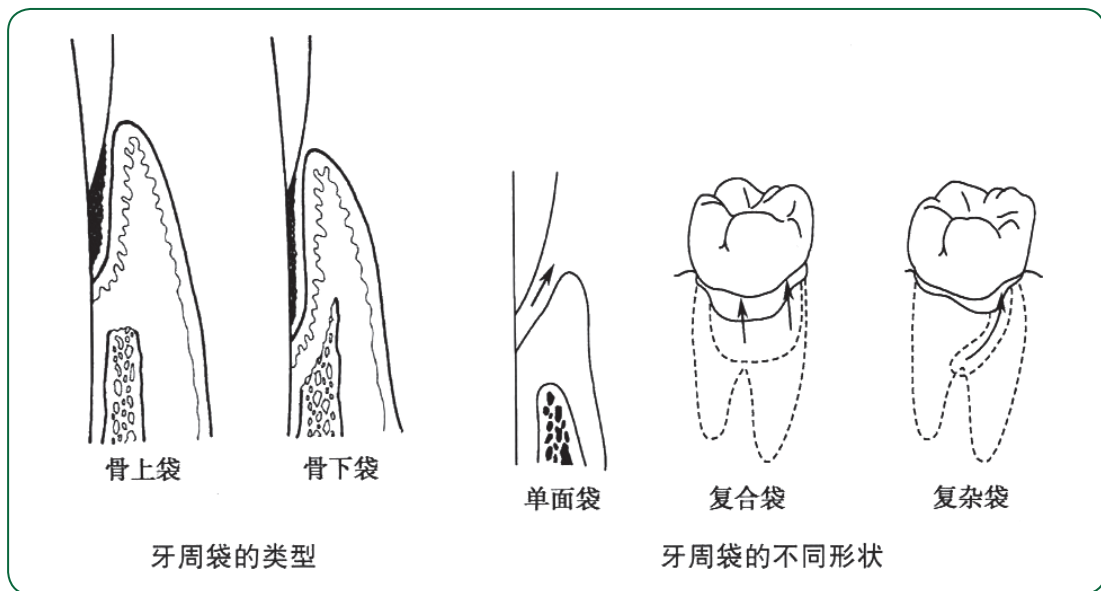


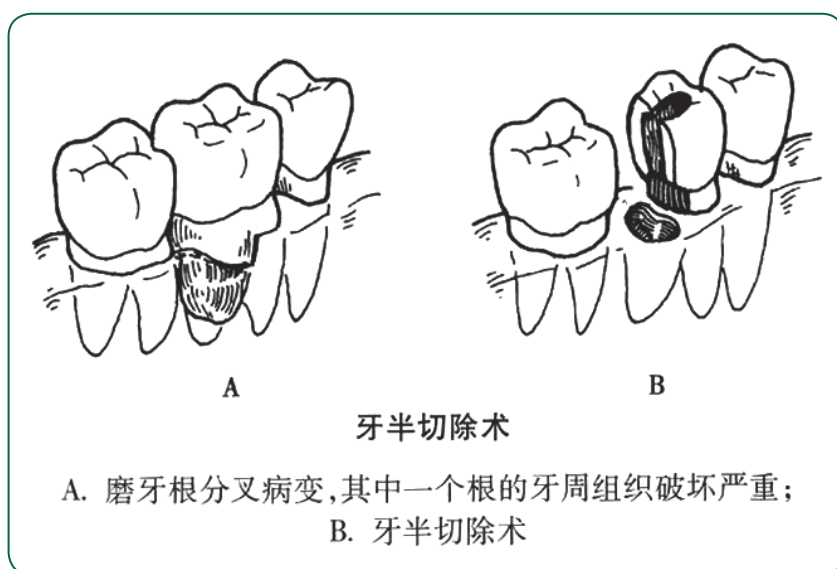
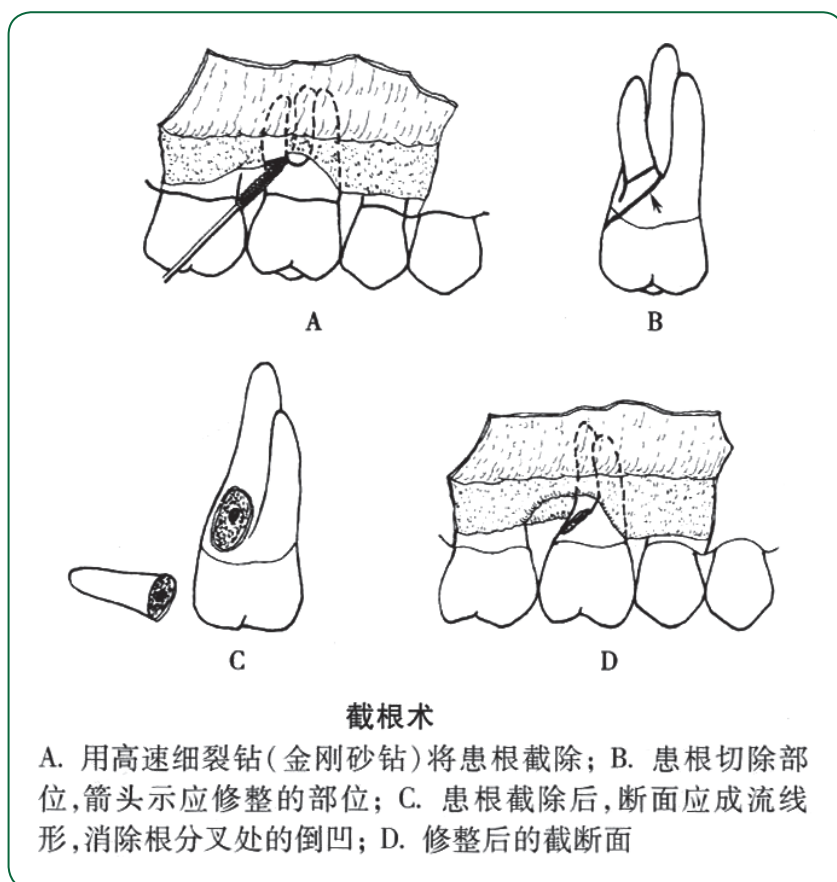
# 牙周病学

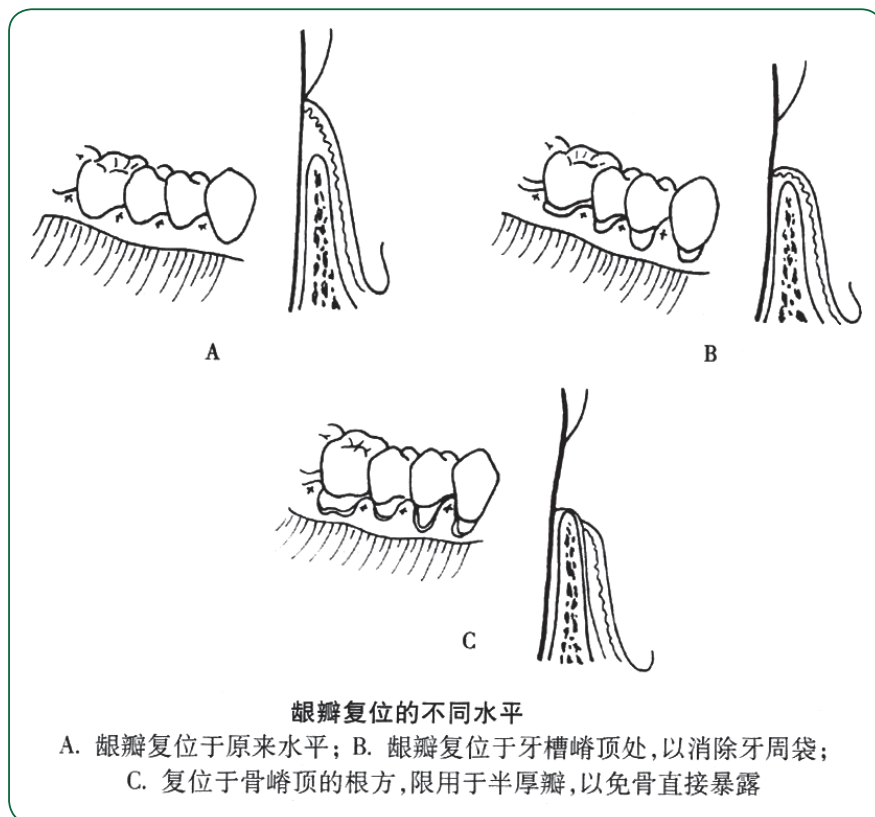
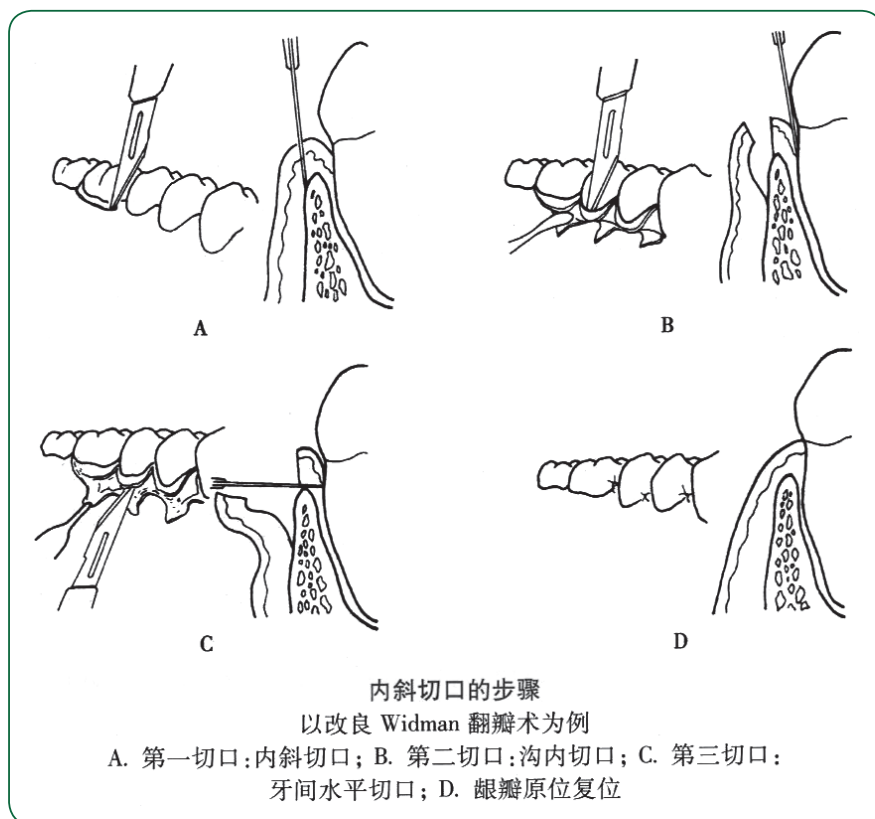


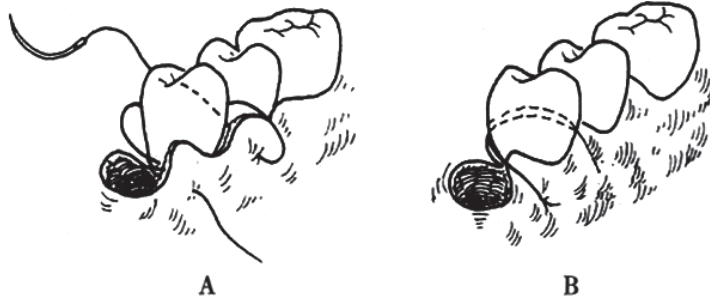
牙龈的解剖学标志





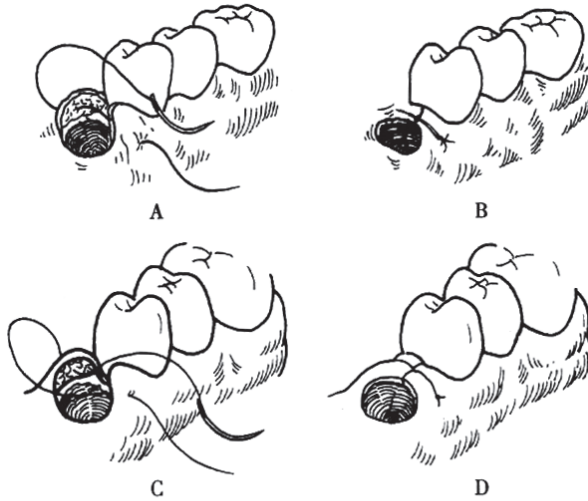






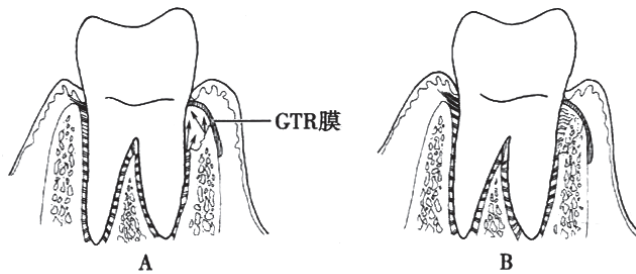
单侧翻瓣时的双乳头悬吊缝合

A. 从瓣的近中乳头外表面进针,缝线环绕牙齿,到达同侧龈瓣的远中,再从远中龈乳头的外表面进针; B. 返回近中乳头处,打结,将单侧瓣的二个乳头悬吊在牙上



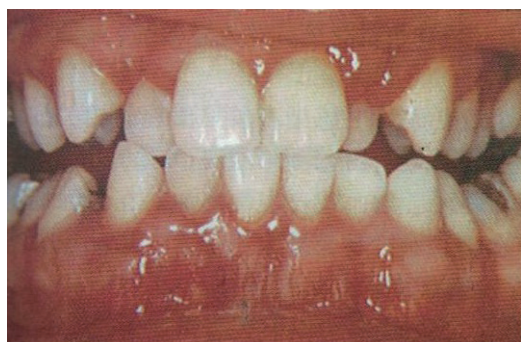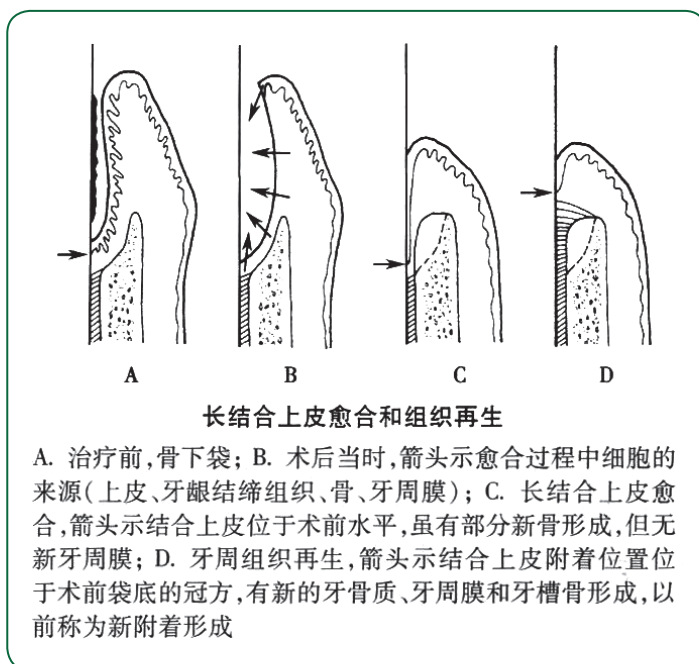
牙间间断缝合

A、B. 直接环形间断缝合; C、D. 8字形间断缝合

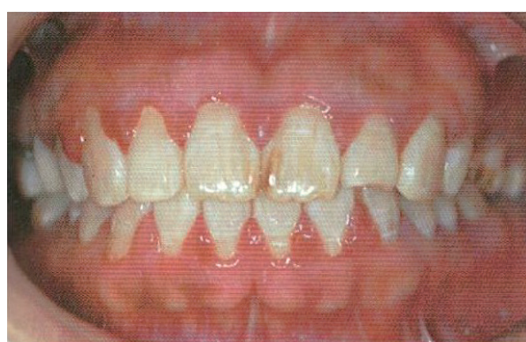

牙周引导性组织再生术(GTR)

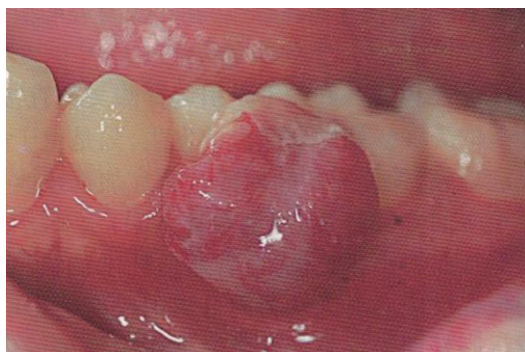
A. 在术区放置屏障膜,引导具有形成新附着能力的牙周膜细胞优先占领根面; B. 愈合后形成牙周组织的再生



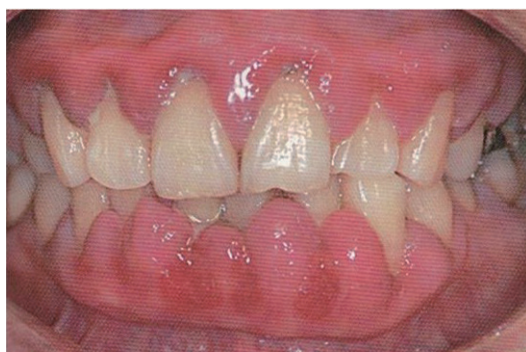慢性龈炎



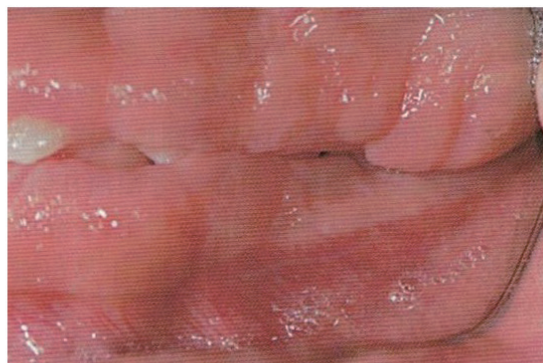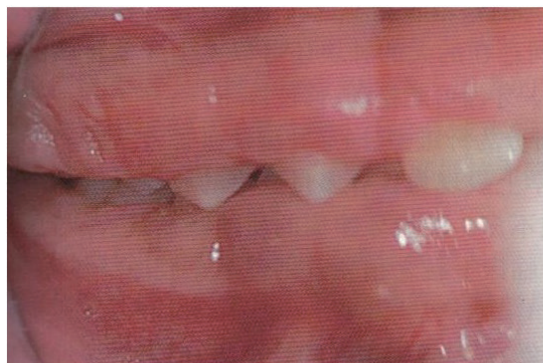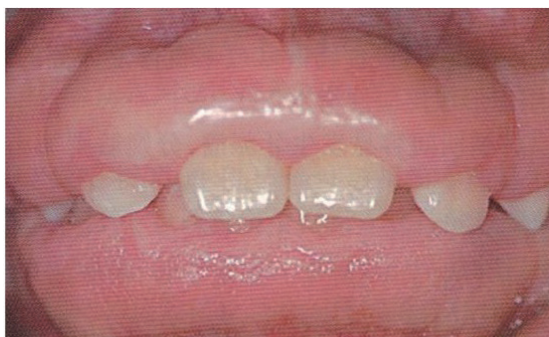妊娠期龈炎



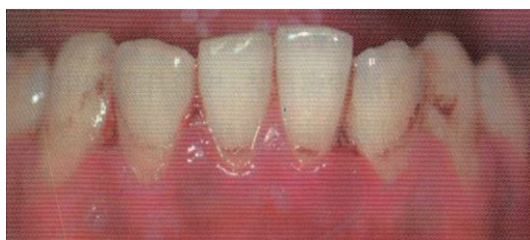妊娠期龈瘤



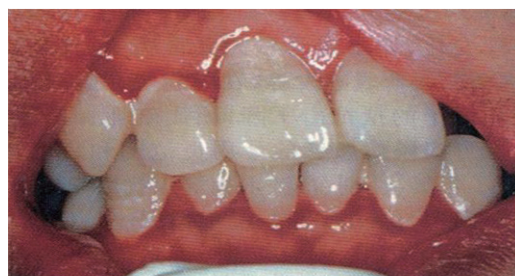苯妥英钠引起的牙龈增生



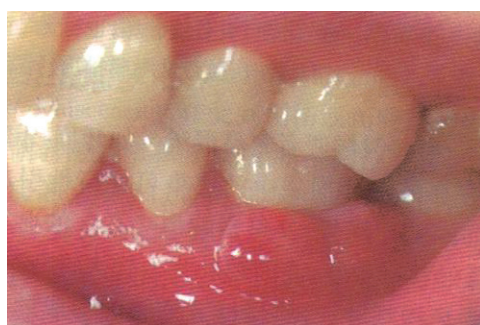牙龈纤维瘤病



急性坏死性溃疡性龈炎

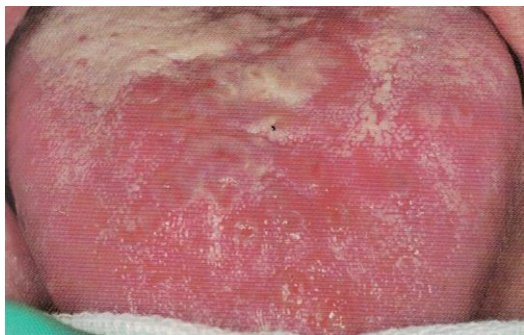

艾滋病患者的龈缘红线

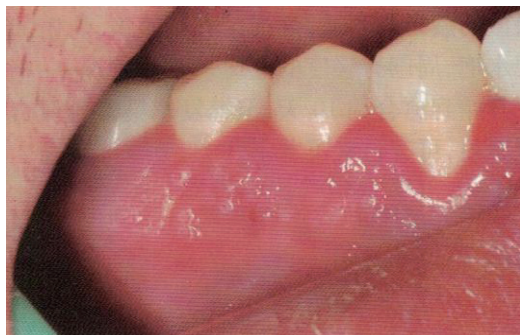

急性牙周脓肿

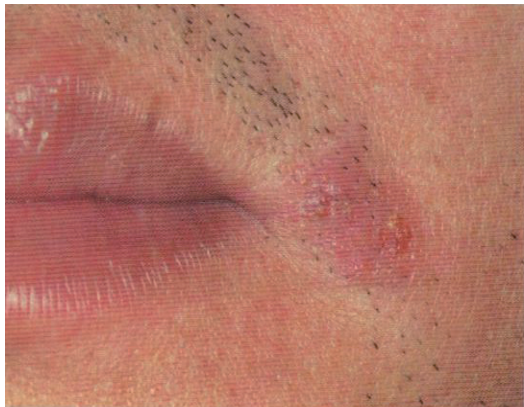# 口腔黏膜病学



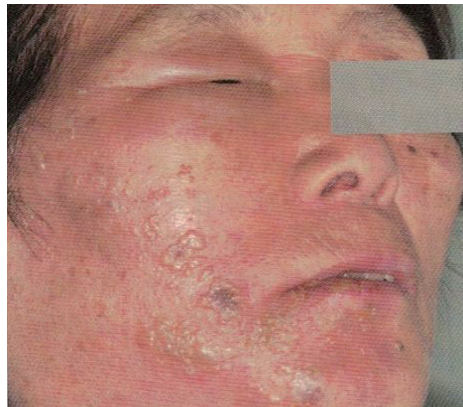原发性疱疹性口炎



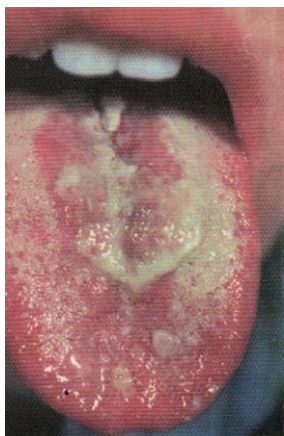原发性疱疹性口炎



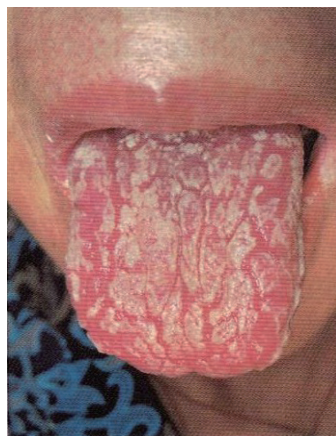
复发性疱疹性口炎



带状疱疹

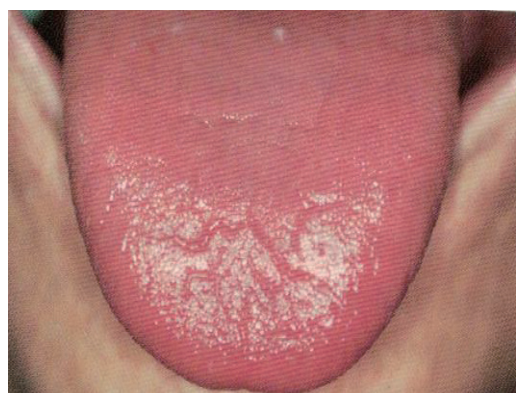


球菌性口炎

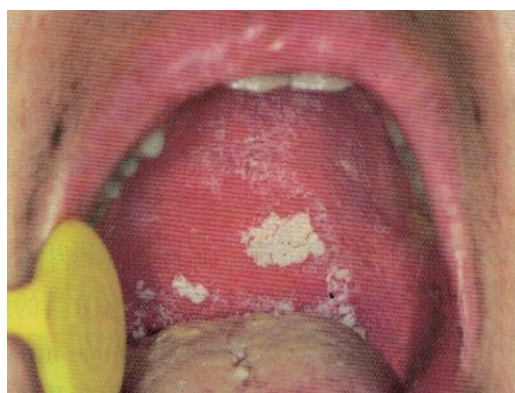


增殖型念珠菌口炎

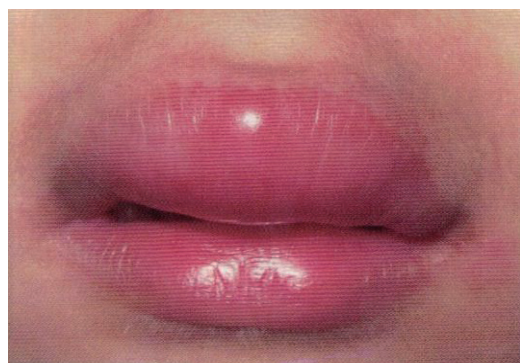




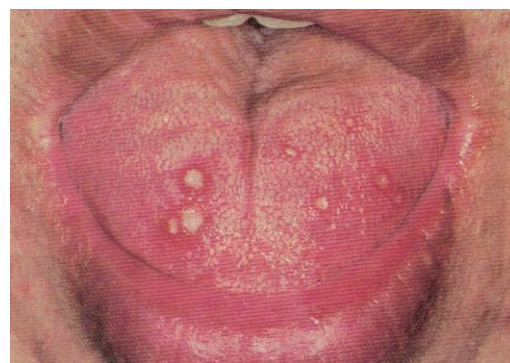
急性红斑型念珠菌性口炎



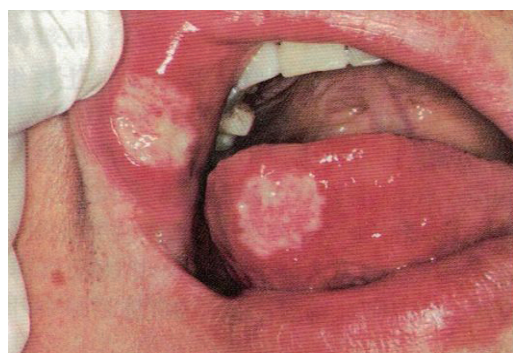急性假膜型念珠菌性口炎



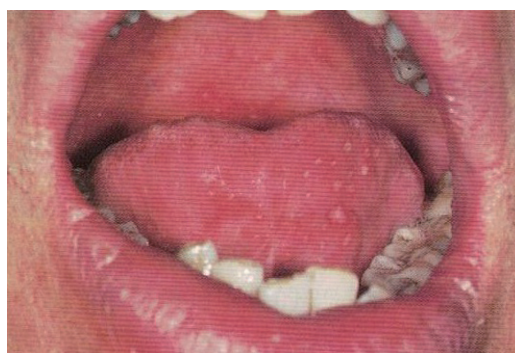
血管神经性水肿



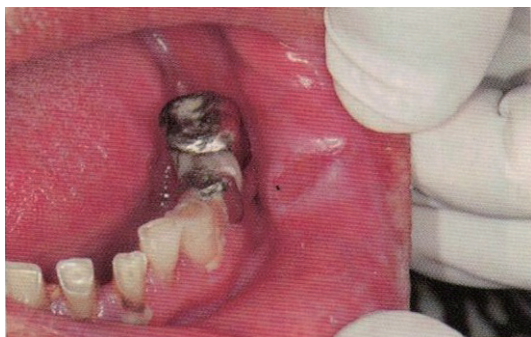轻型复发性阿弗他溃疡



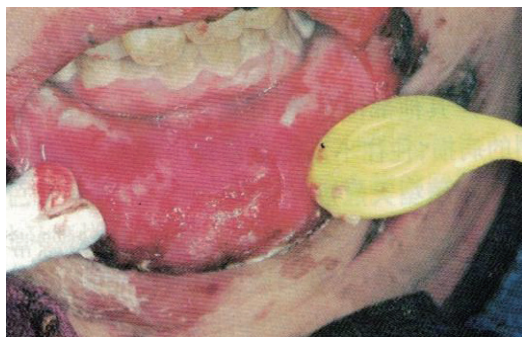重型复发性阿弗他溃疡



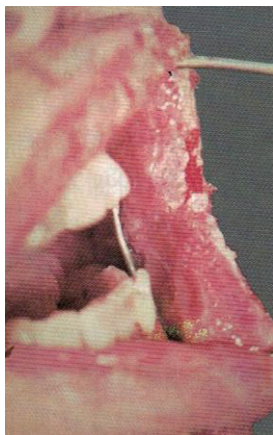
疱疹型复发性阿弗他溃疡



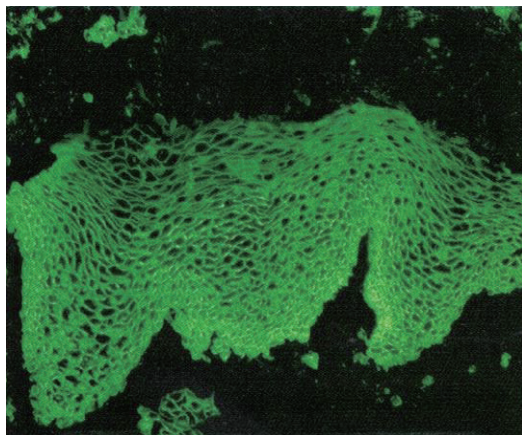
创伤性溃疡



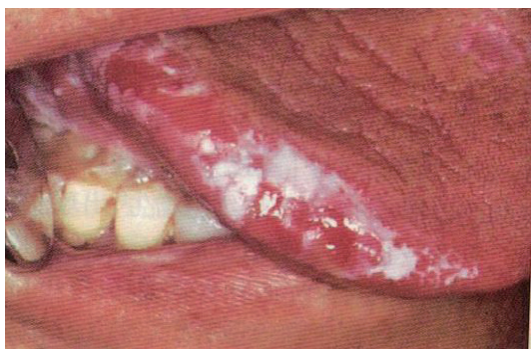寻常型天疱疮



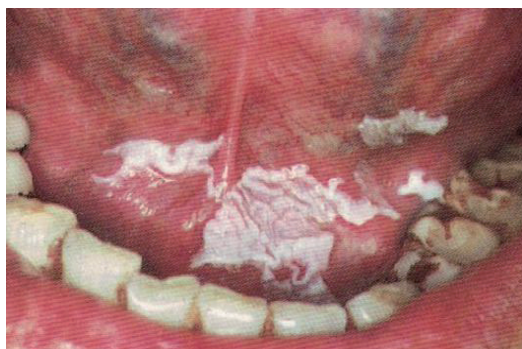寻常型天疱疮



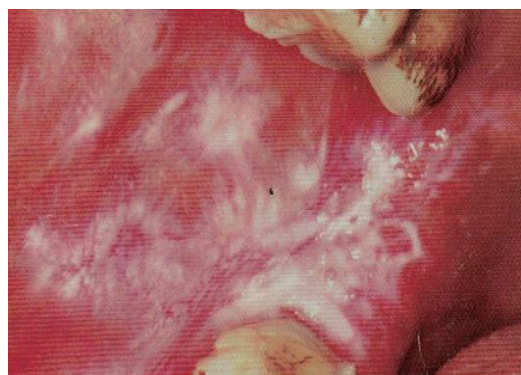天疱疮免疫荧光图



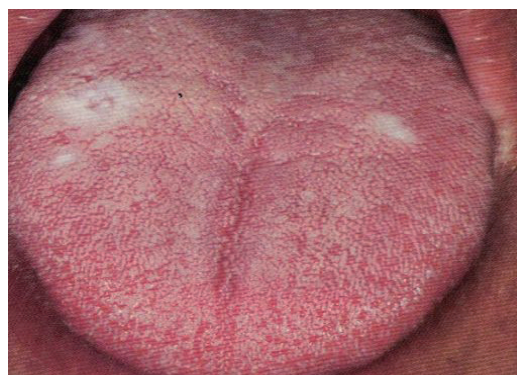白斑 ( 溃疡型 )



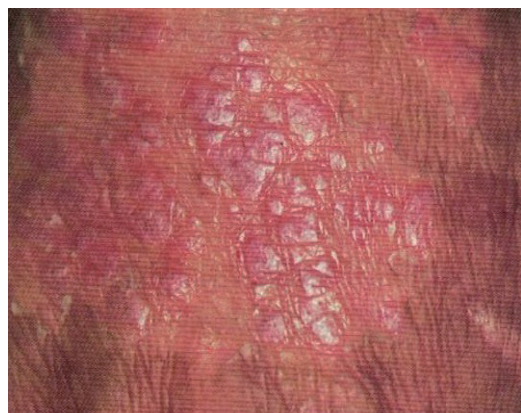白斑 ( 皱纸状 )



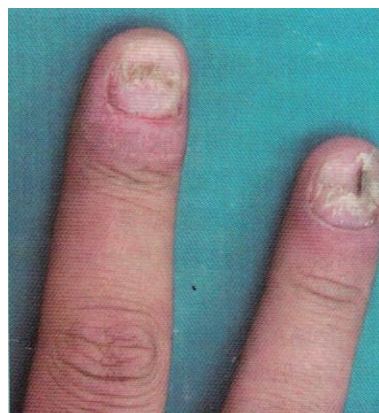扁平苔藓



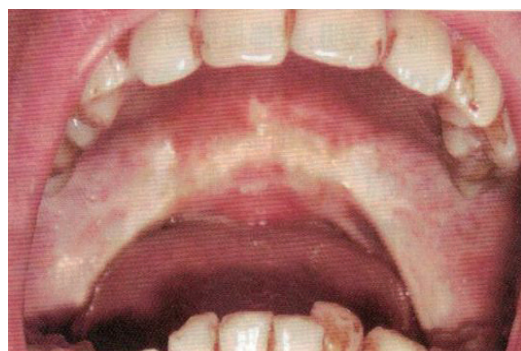扁平苔藓



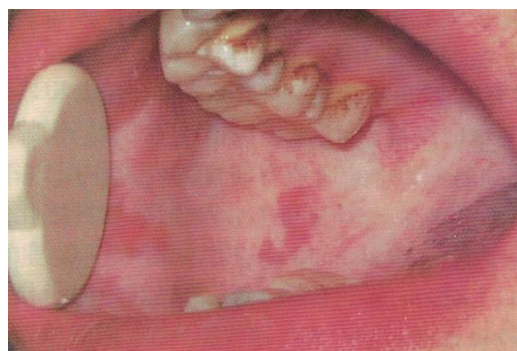扁平苔藓 (皮肤损害)



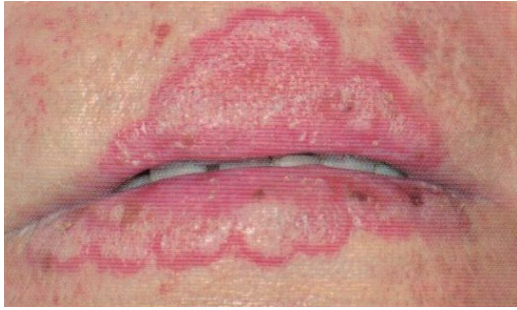扁平苔藓 (指甲损害)



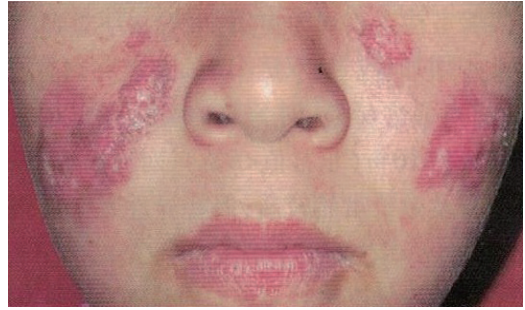口腔黏膜下纤维化 (腭部)



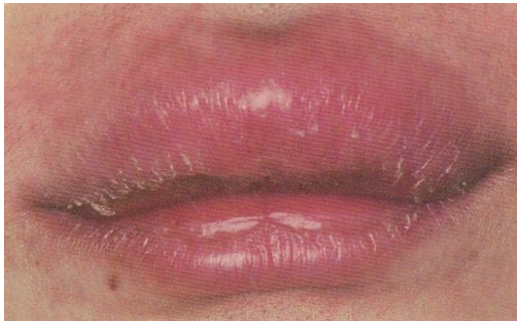口腔黏膜下纤维化 (颊部)



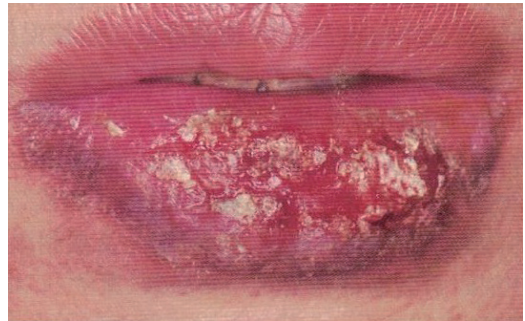盘状红斑狼疮



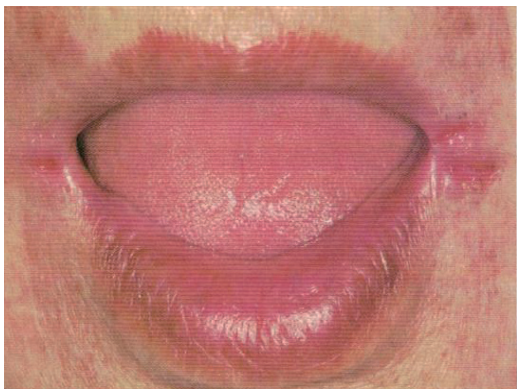
盘状红斑狼疮



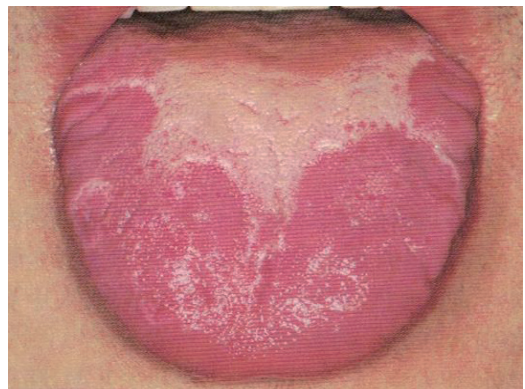
肉芽肿性唇炎



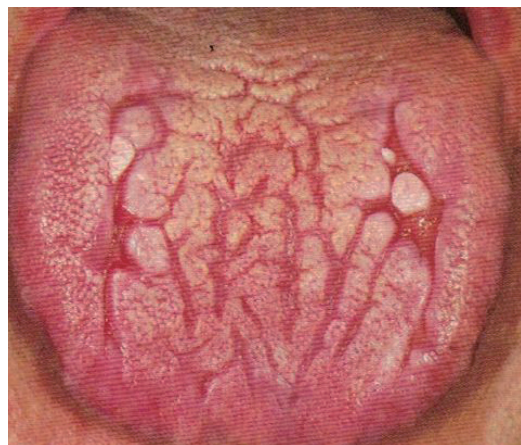
慢性糜烂性唇炎



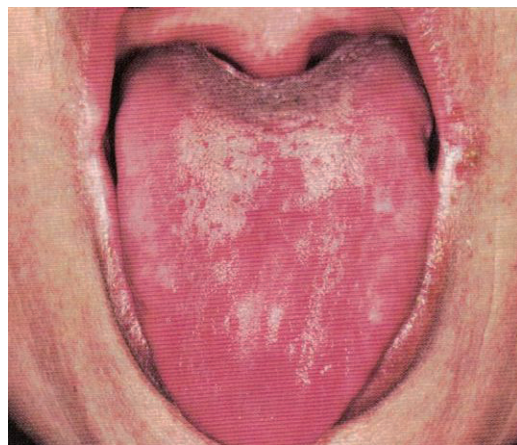
营养不良性口角炎



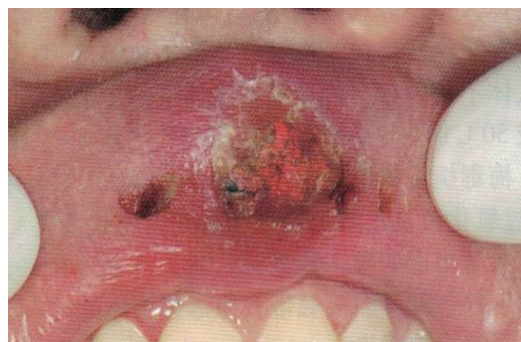地图舌



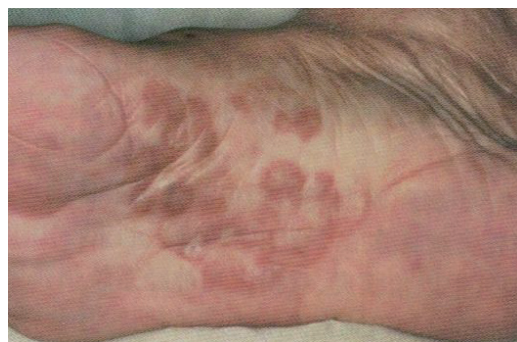沟纹舌



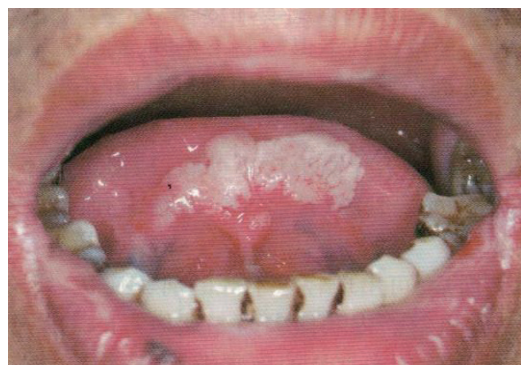萎缩性舌炎



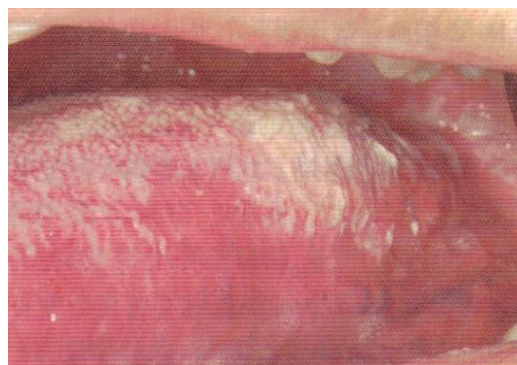
唇硬下疳



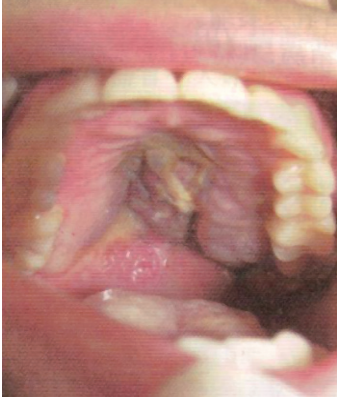梅毒疹



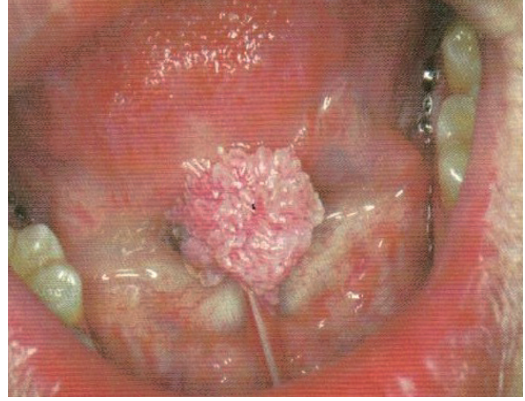
黏膜斑



毛状白斑

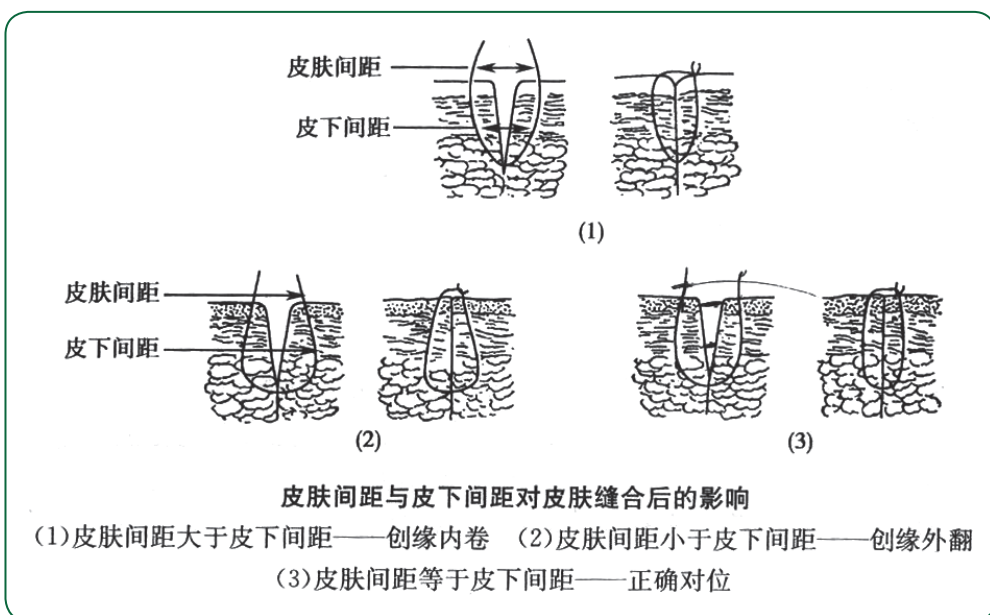
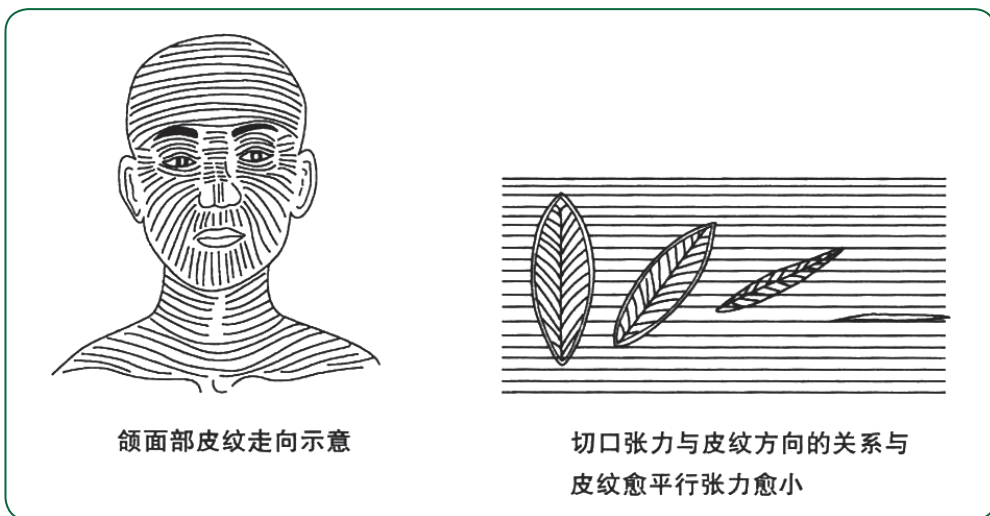
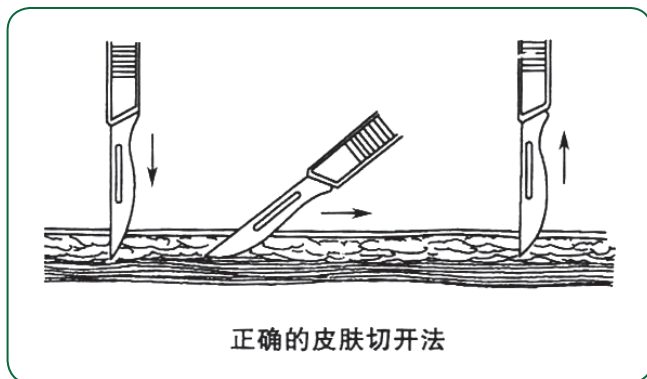
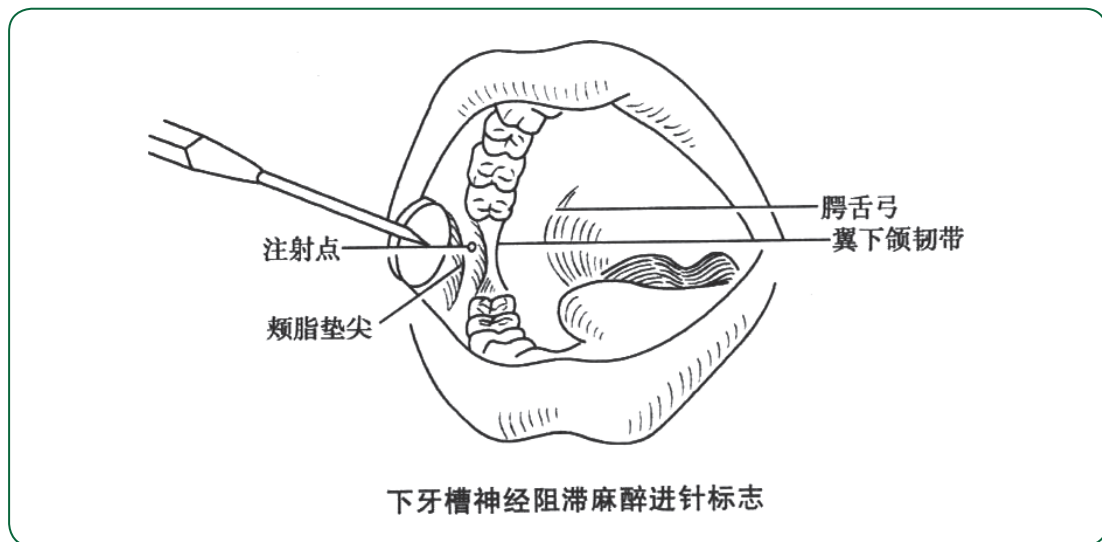

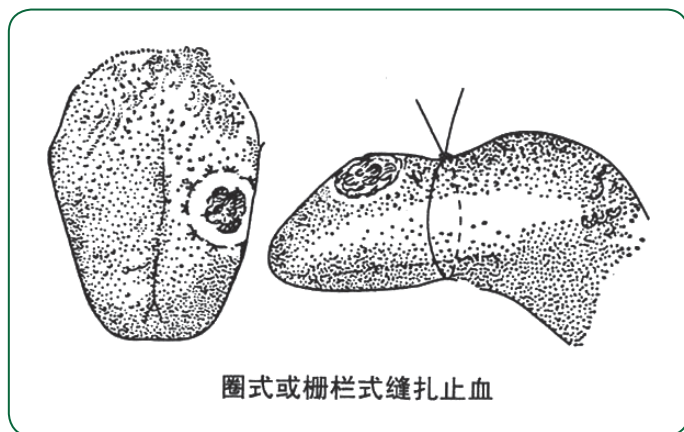
卡波西肉瘤



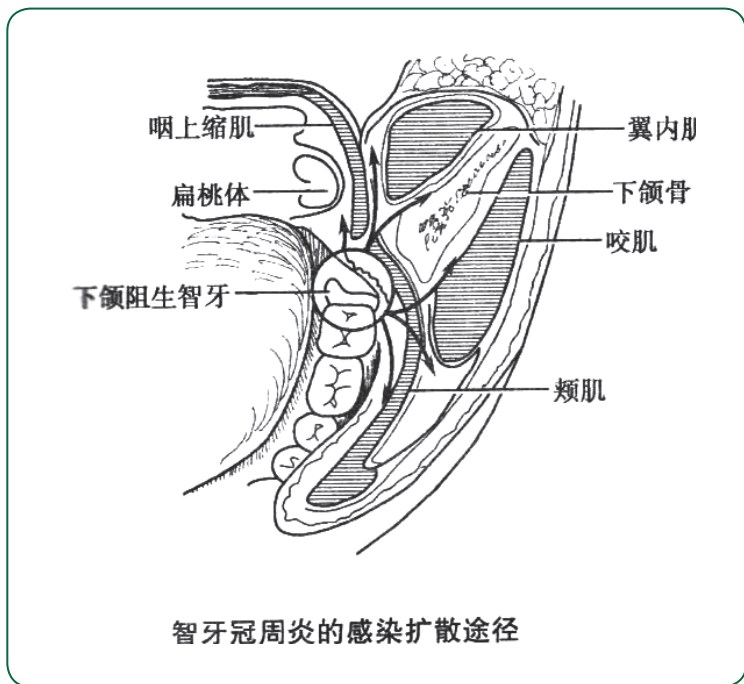
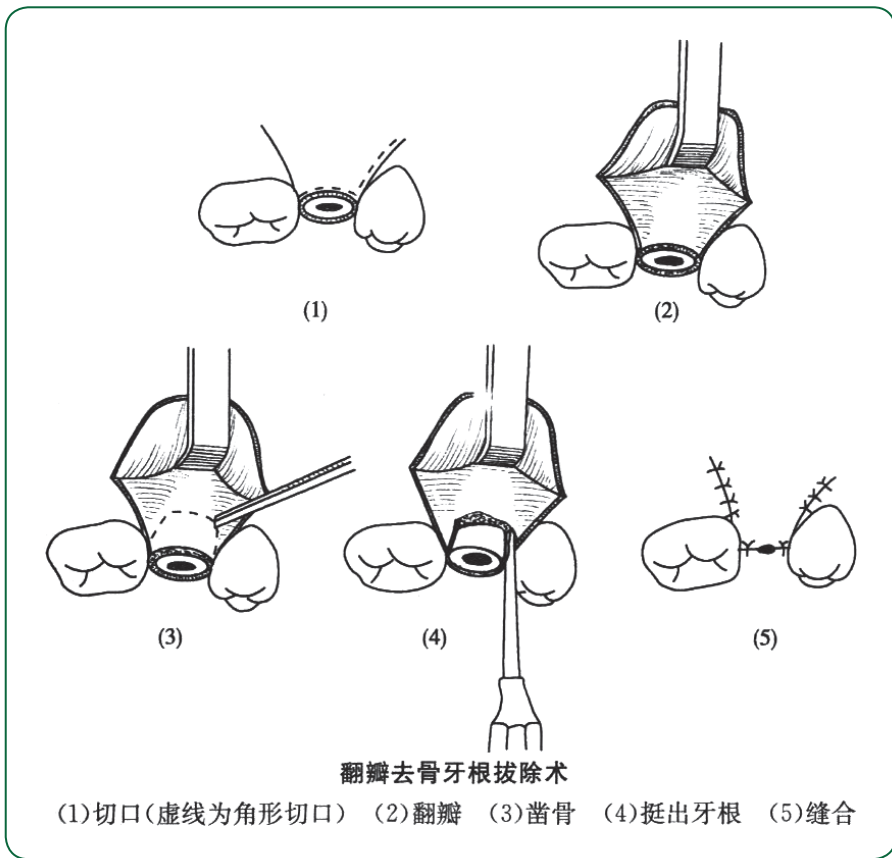
尖锐湿疣

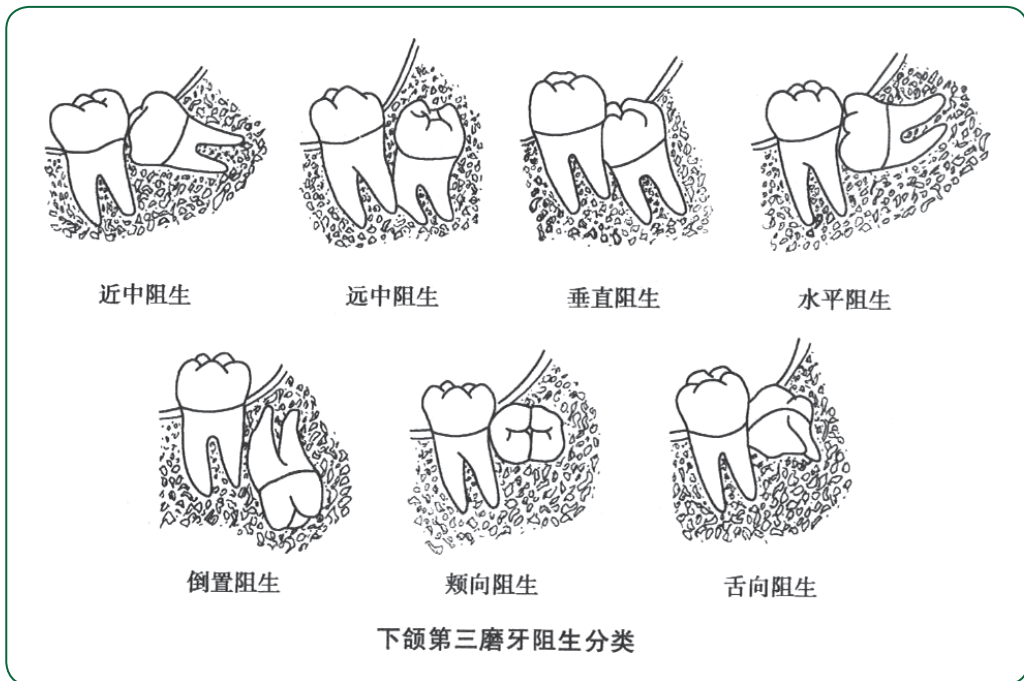
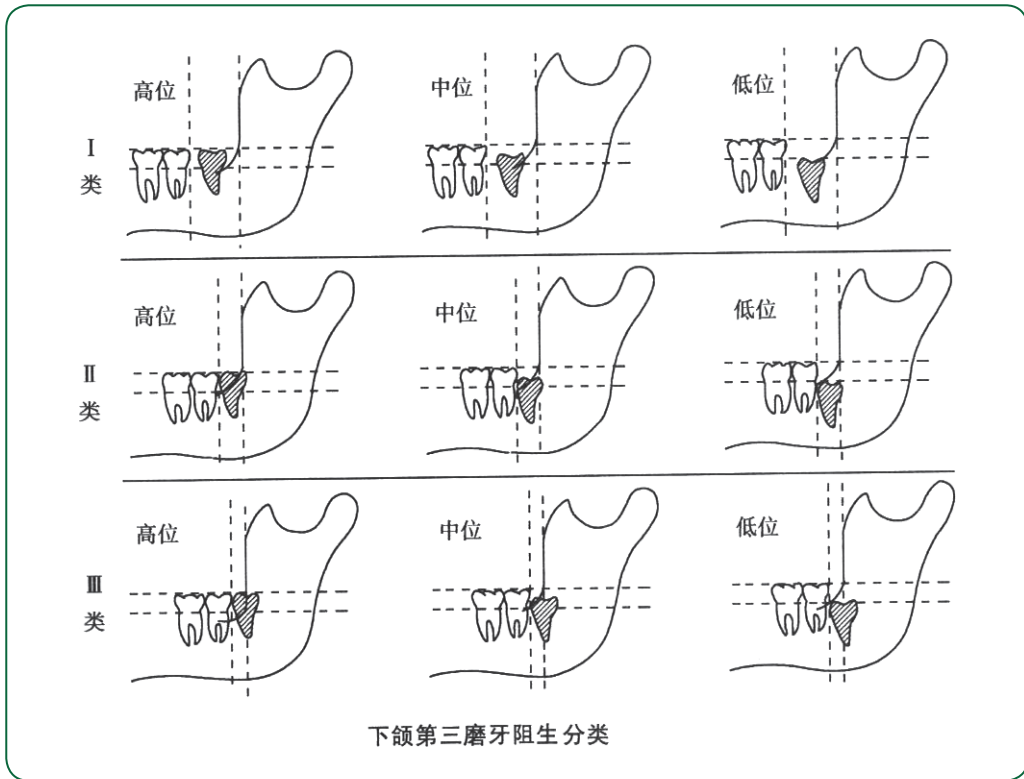
# 口腔颌面外科学

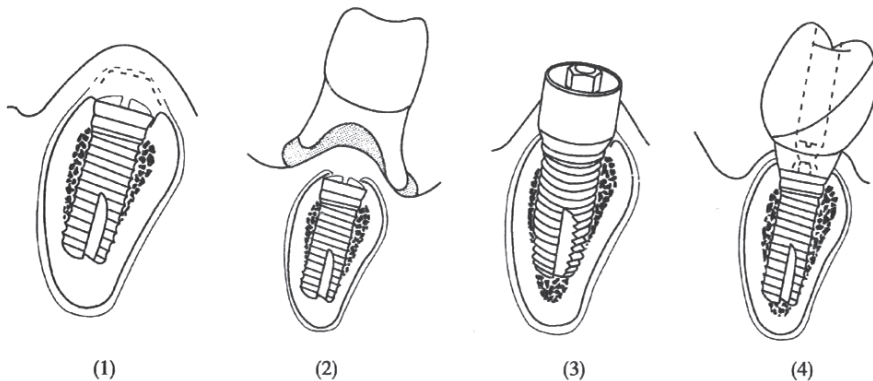






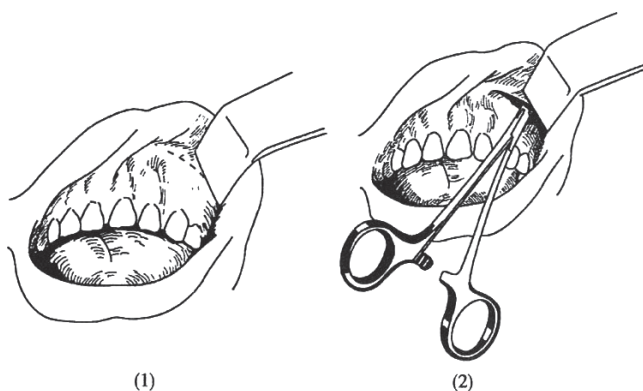






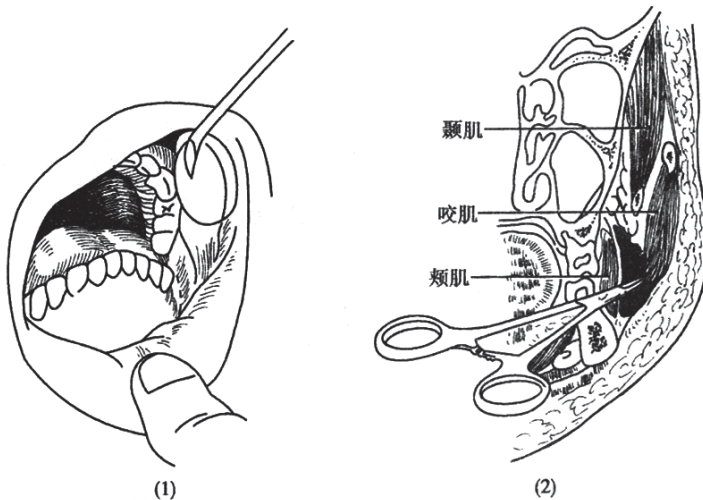
两段式种植义齿修复的治疗程序

(1)第一期种植体植入术后 (2)第一期术后的骨愈合期 (3)第二期基台连接术后 (4)完成种植义齿修复



眶下间隙脓肿切开引流术

(1)口内切口线 (2)分离脓腔



颊间隙脓肿口内切开引流术

(1)口内切口线 (2)分离脓腔

